

Πήχη & Χέρι


E Johnson

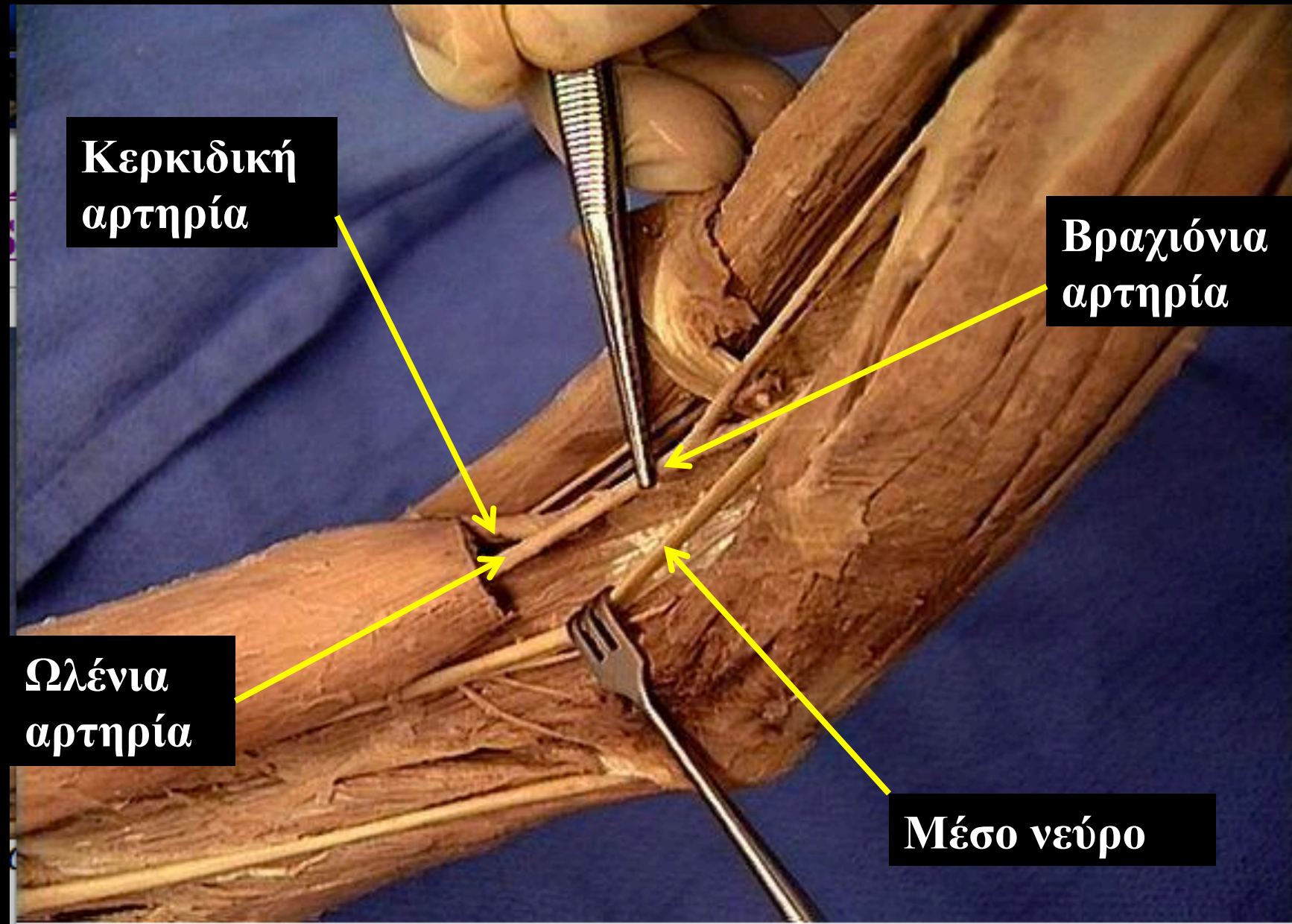
Αν. Καθηγήτρια

Εργαστήριο Ανατομίας

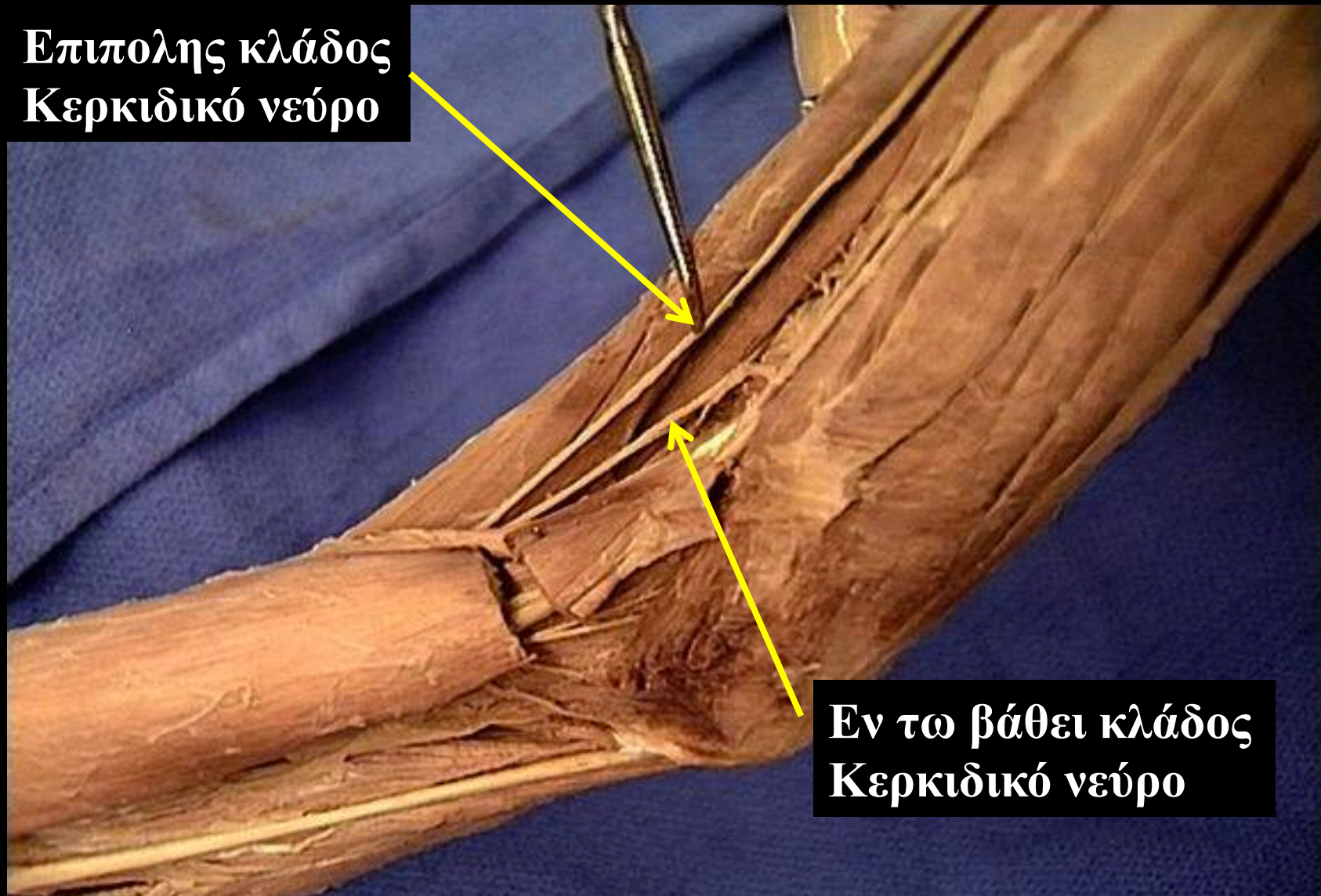
E. Τζόνσον, Αν. Καθηγήτρια

Μύες του αγκωνιαίου βόθρου

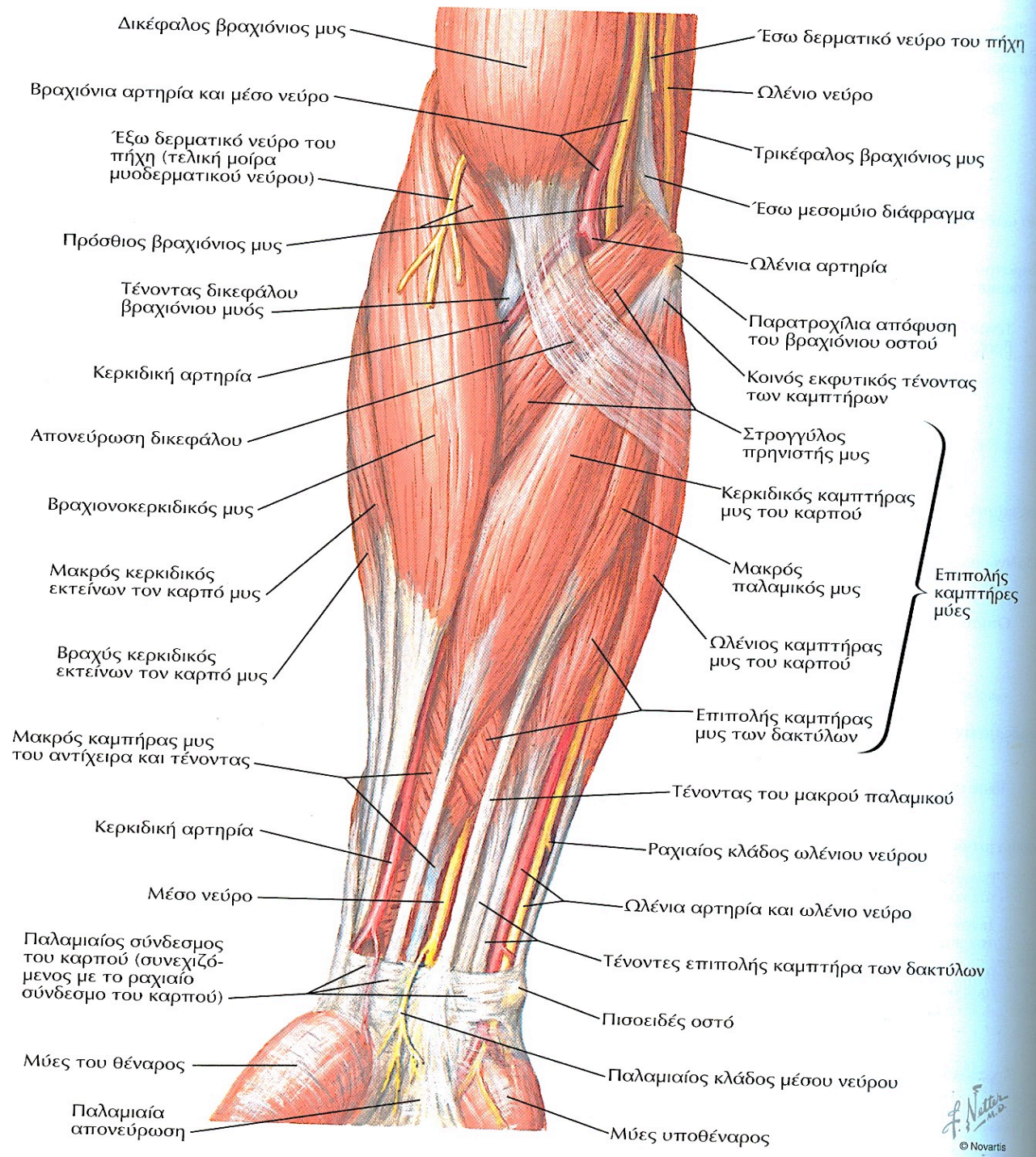




**Επιπολής κλάδος
Κερκιδικό νεύρο**



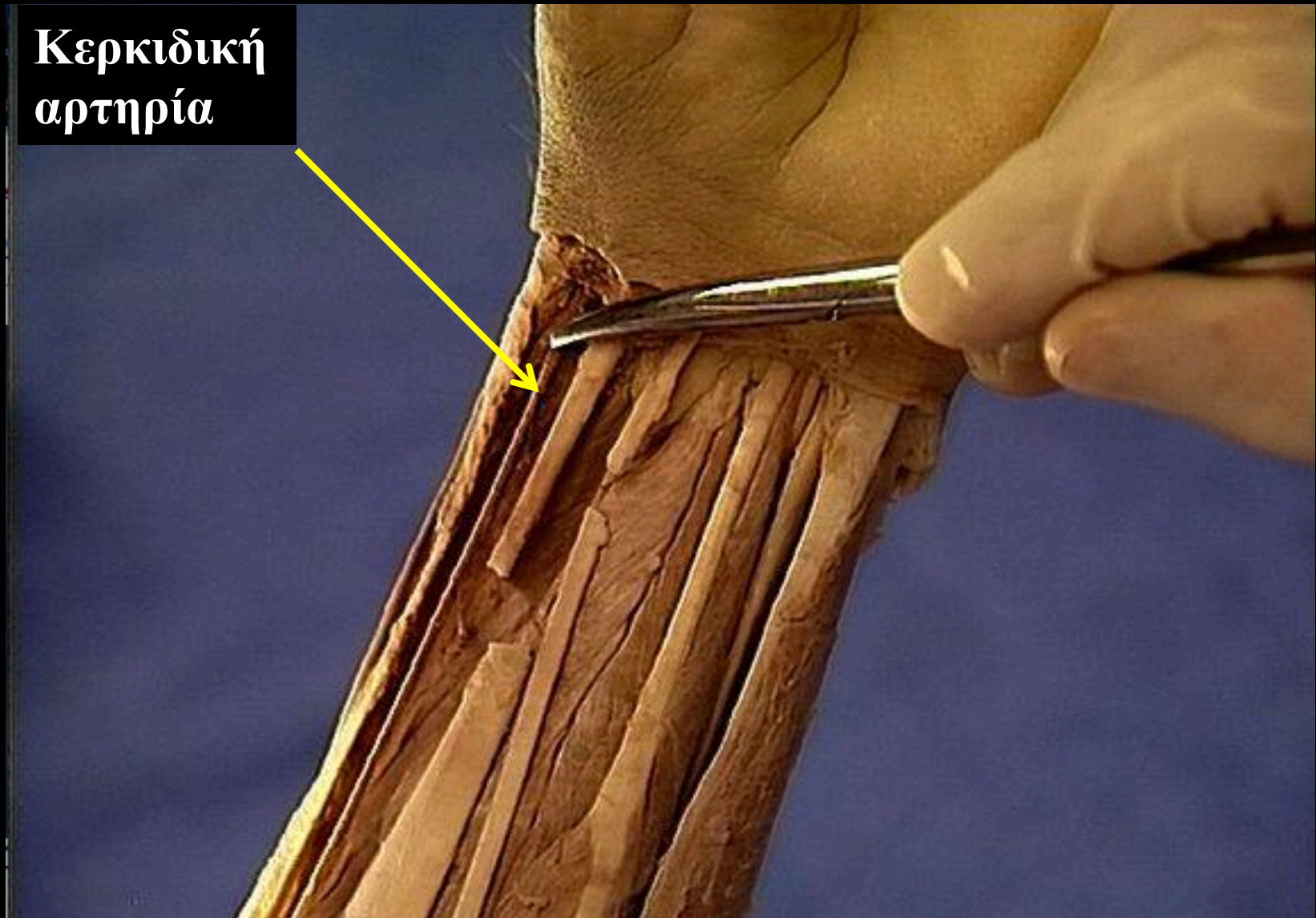
**Εν τω βάθει κλάδος
Κερκιδικό νεύρο**



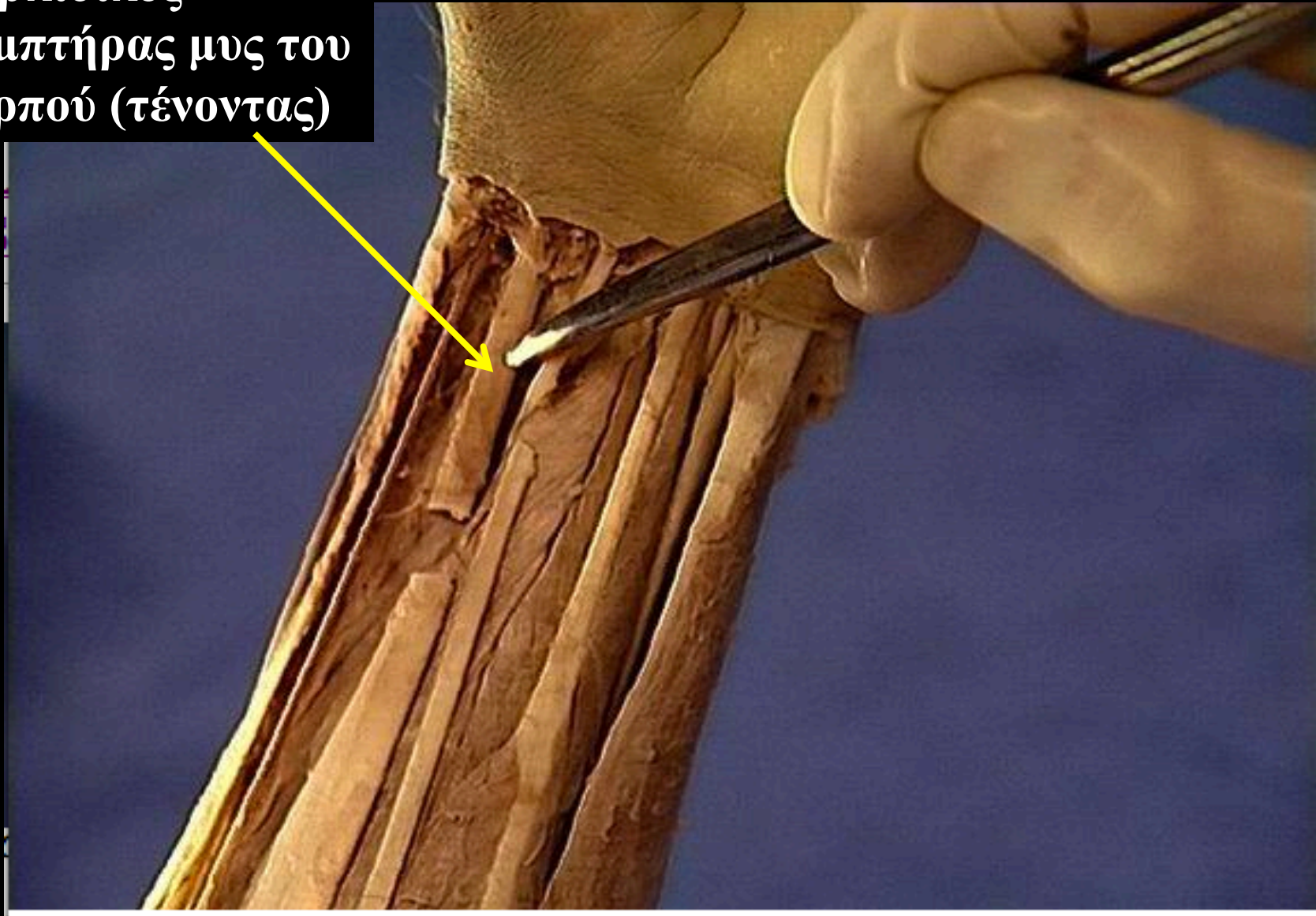
F. Netter M.D.
© Novartis

Ε. Τζόνσον, Αν. Καθηγήτρια

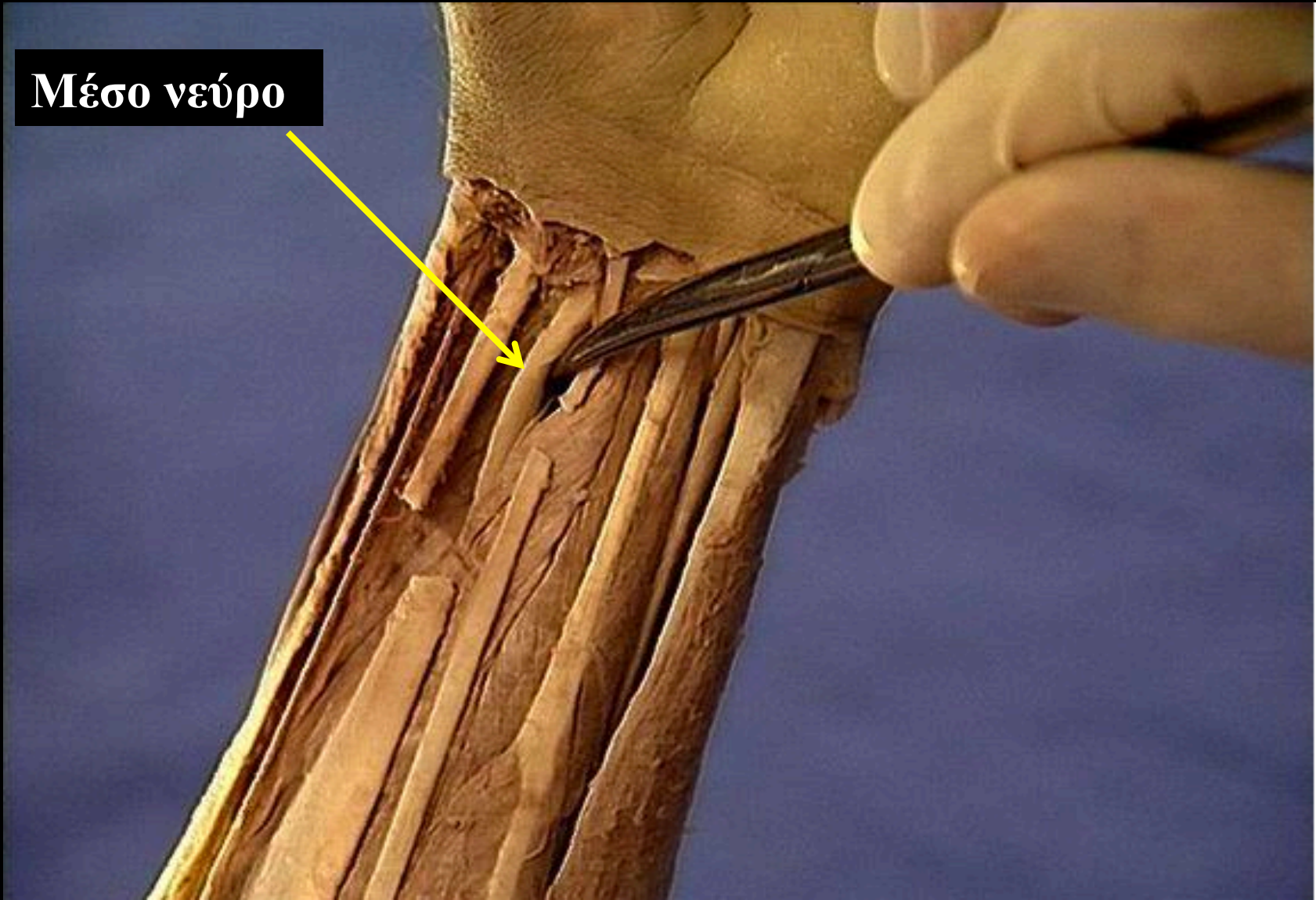
**Κερκιδική
αρτηρία**



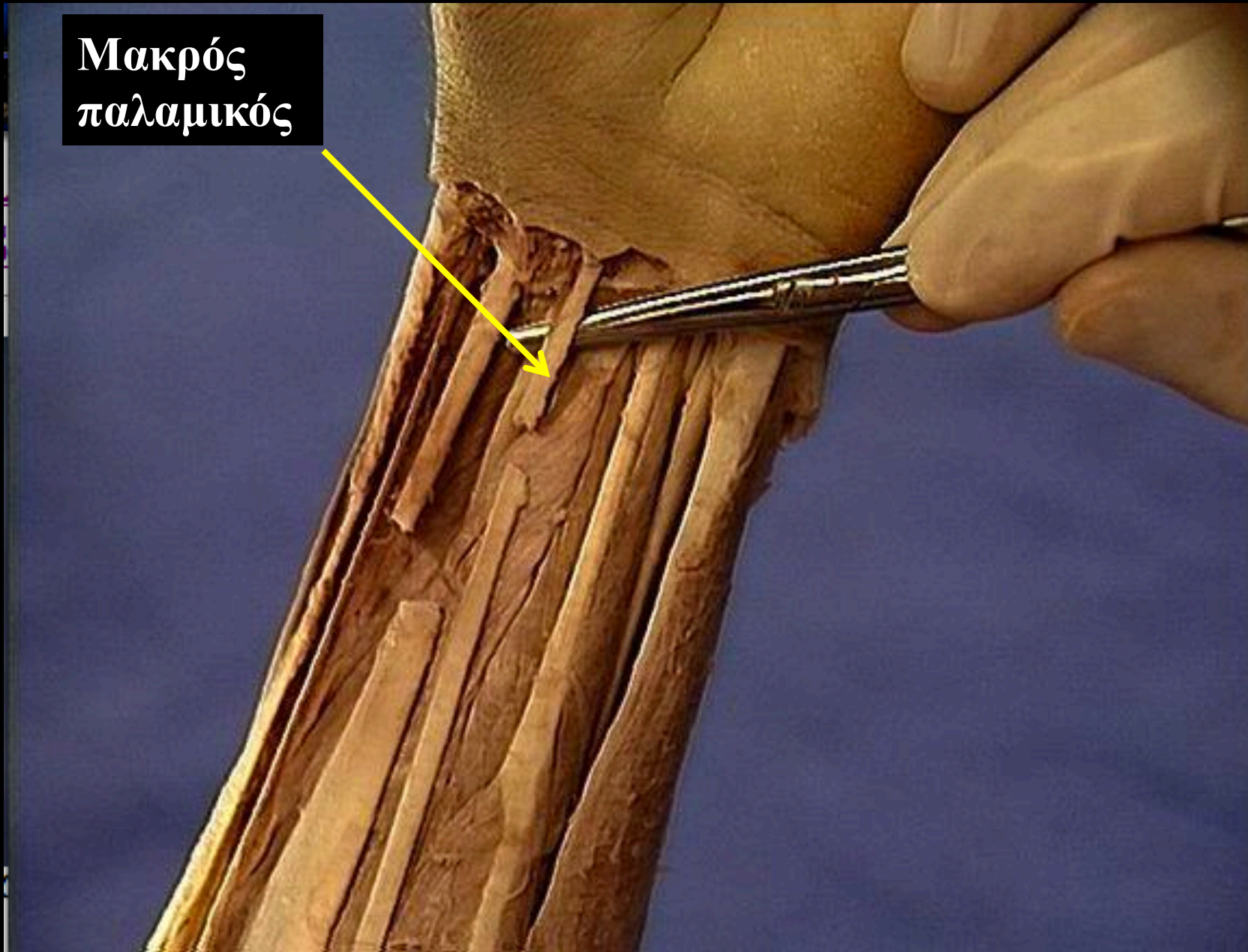
Κερκιδικός
καμπτήρας μυς του
καρπού (τένοντας)



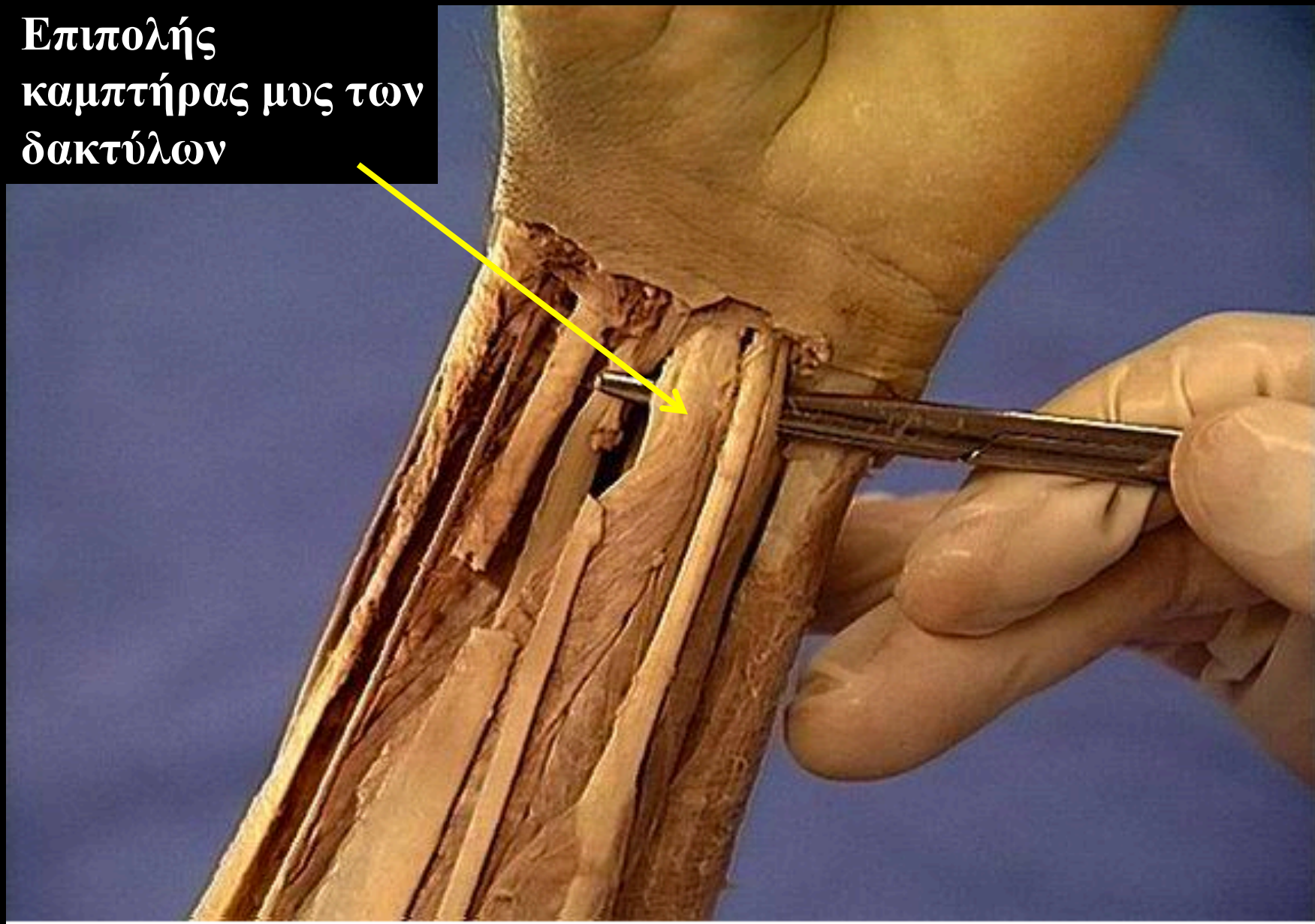
Μέσο νεύρο



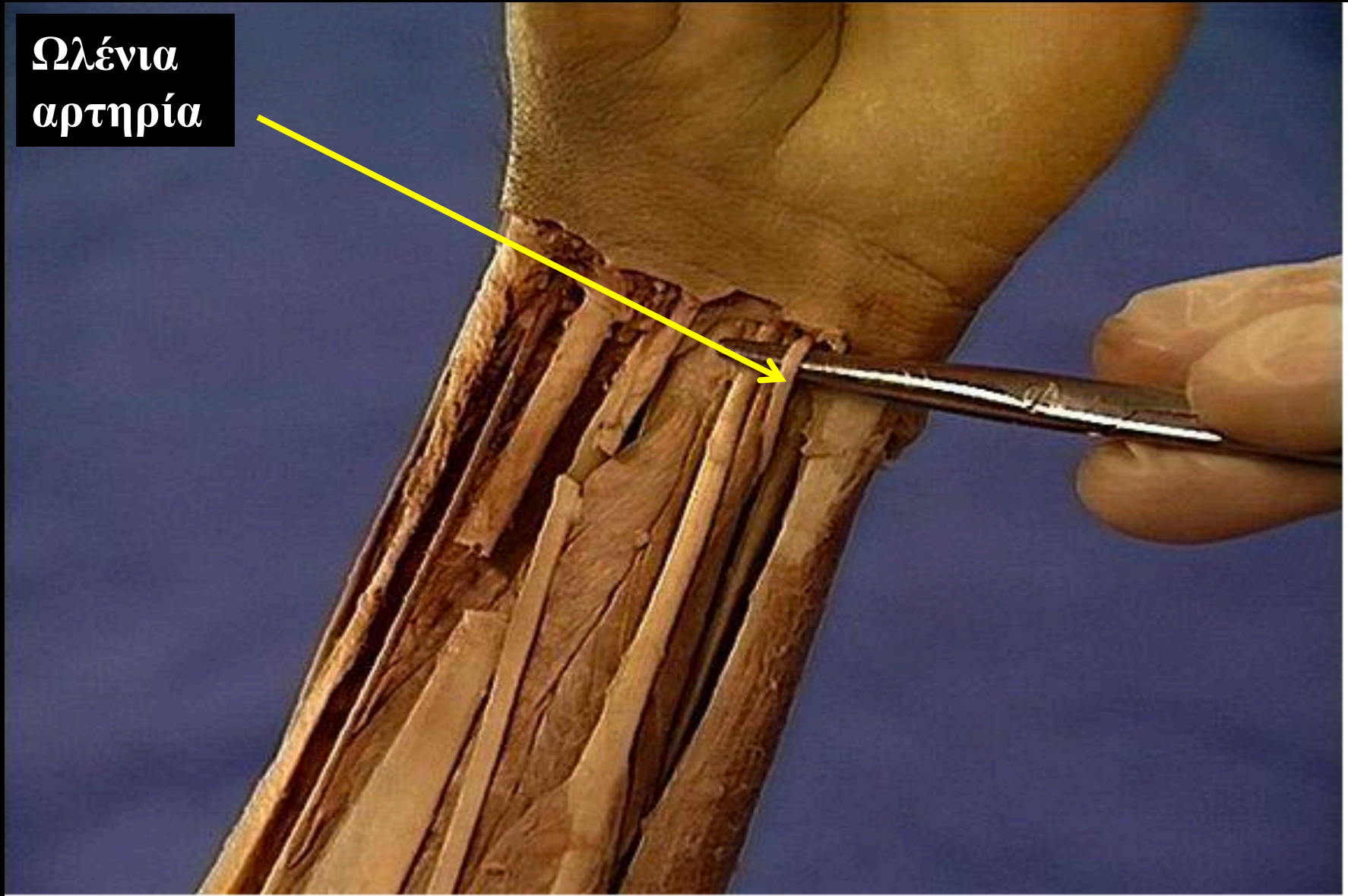
**Μακρός
παλαμικός**



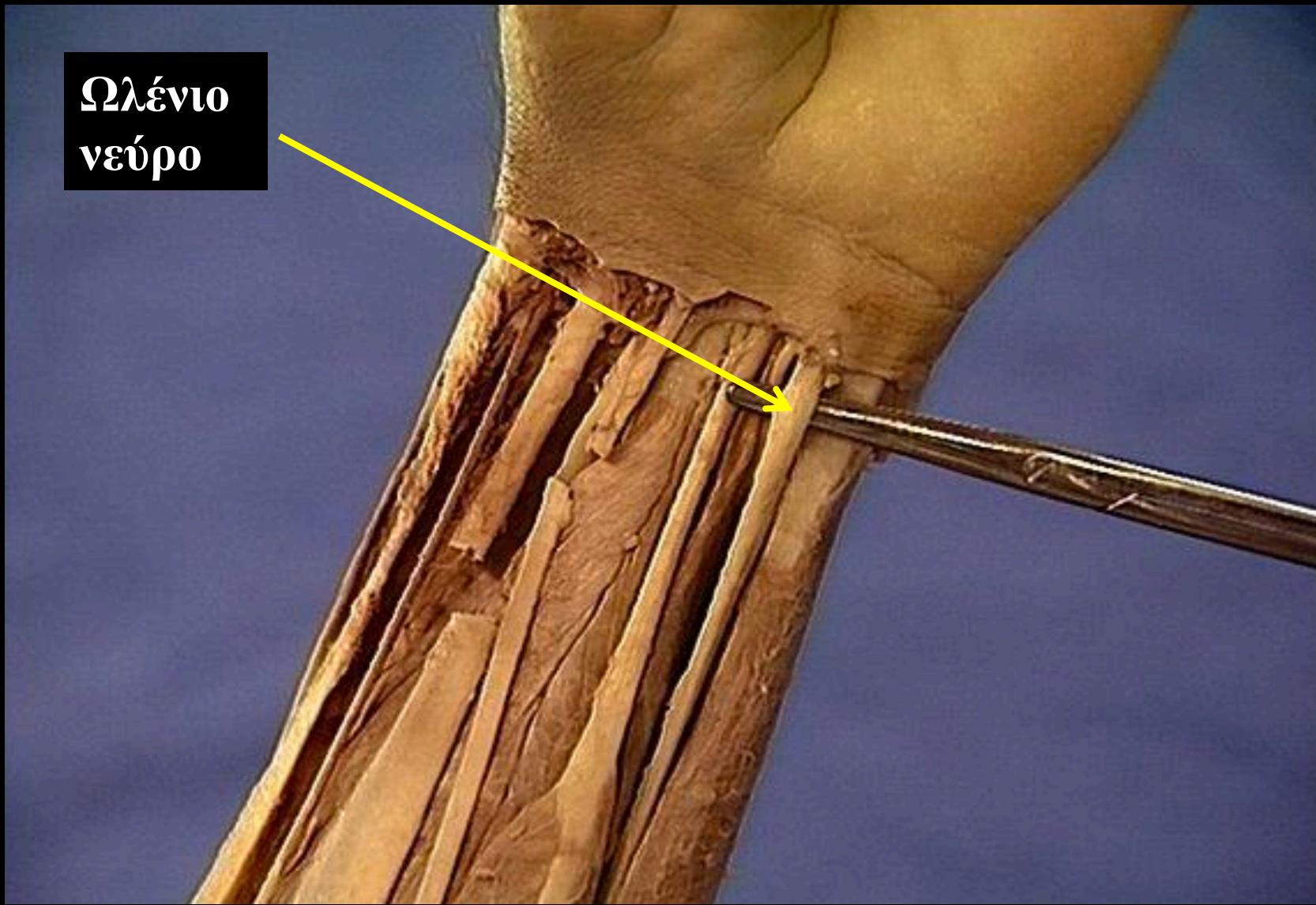
Επιπολής
καμπτήρας μυς των
δακτύλων



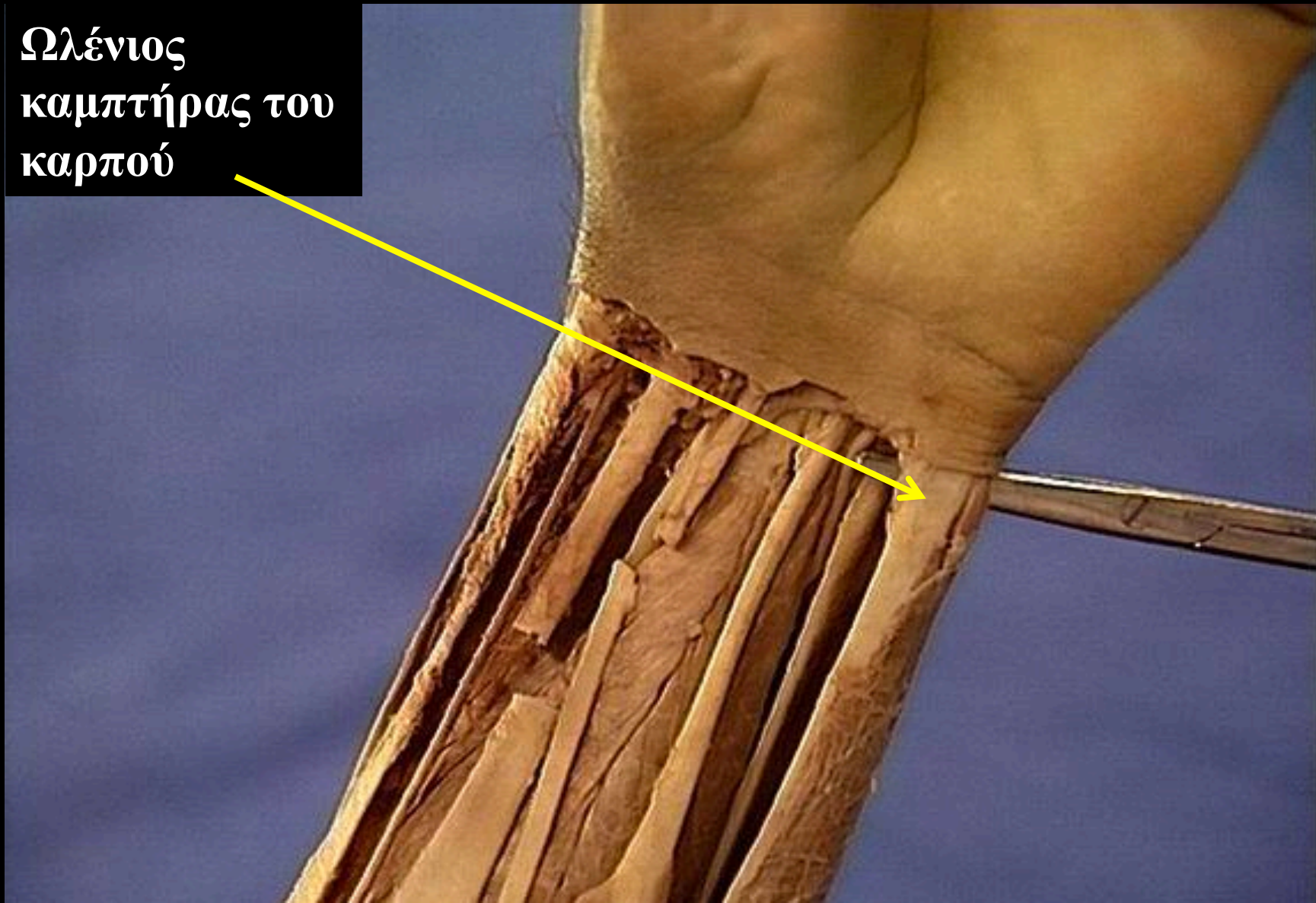
Ωλένια
αρτηρία



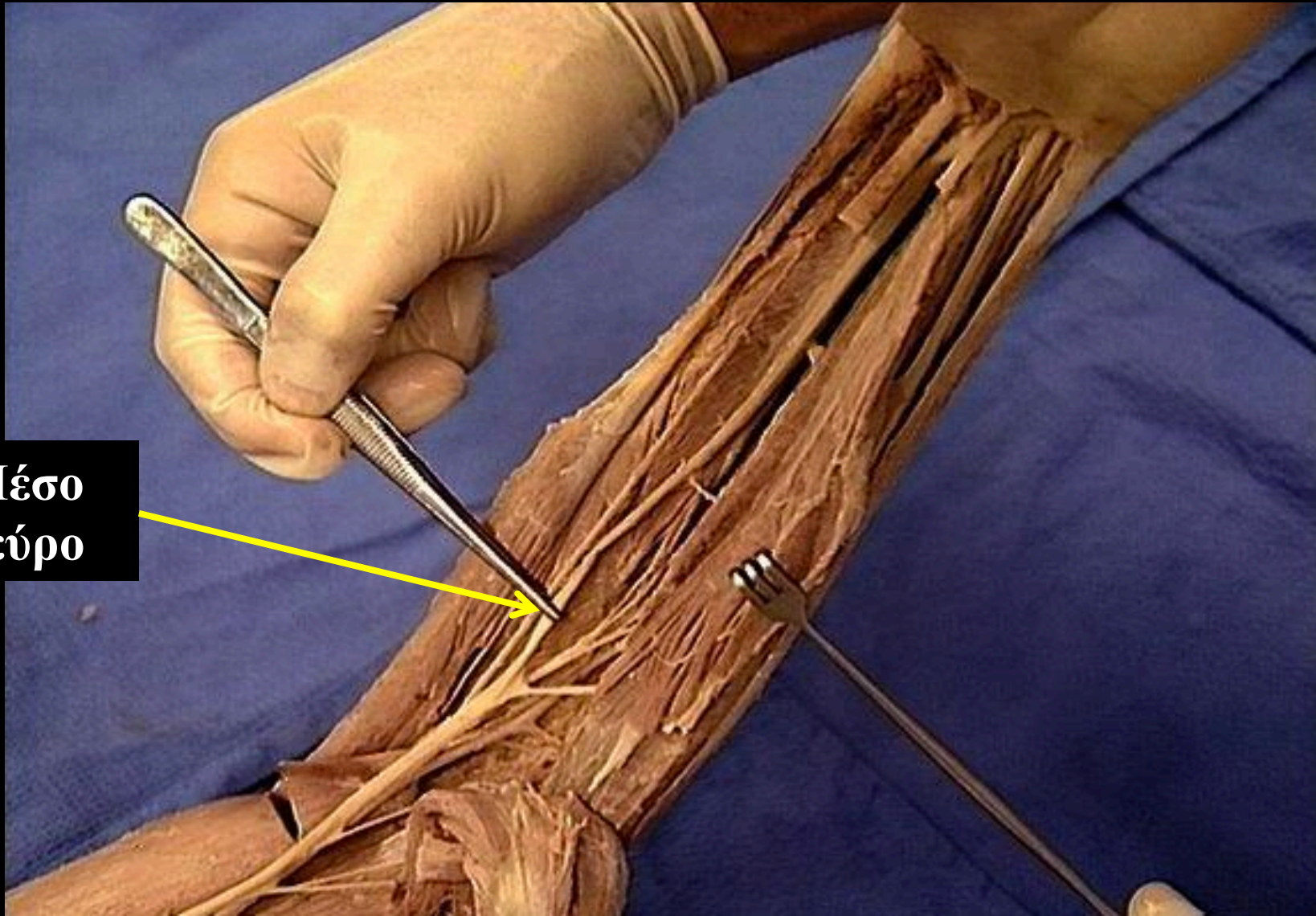
Ωλένιο
νεύρο

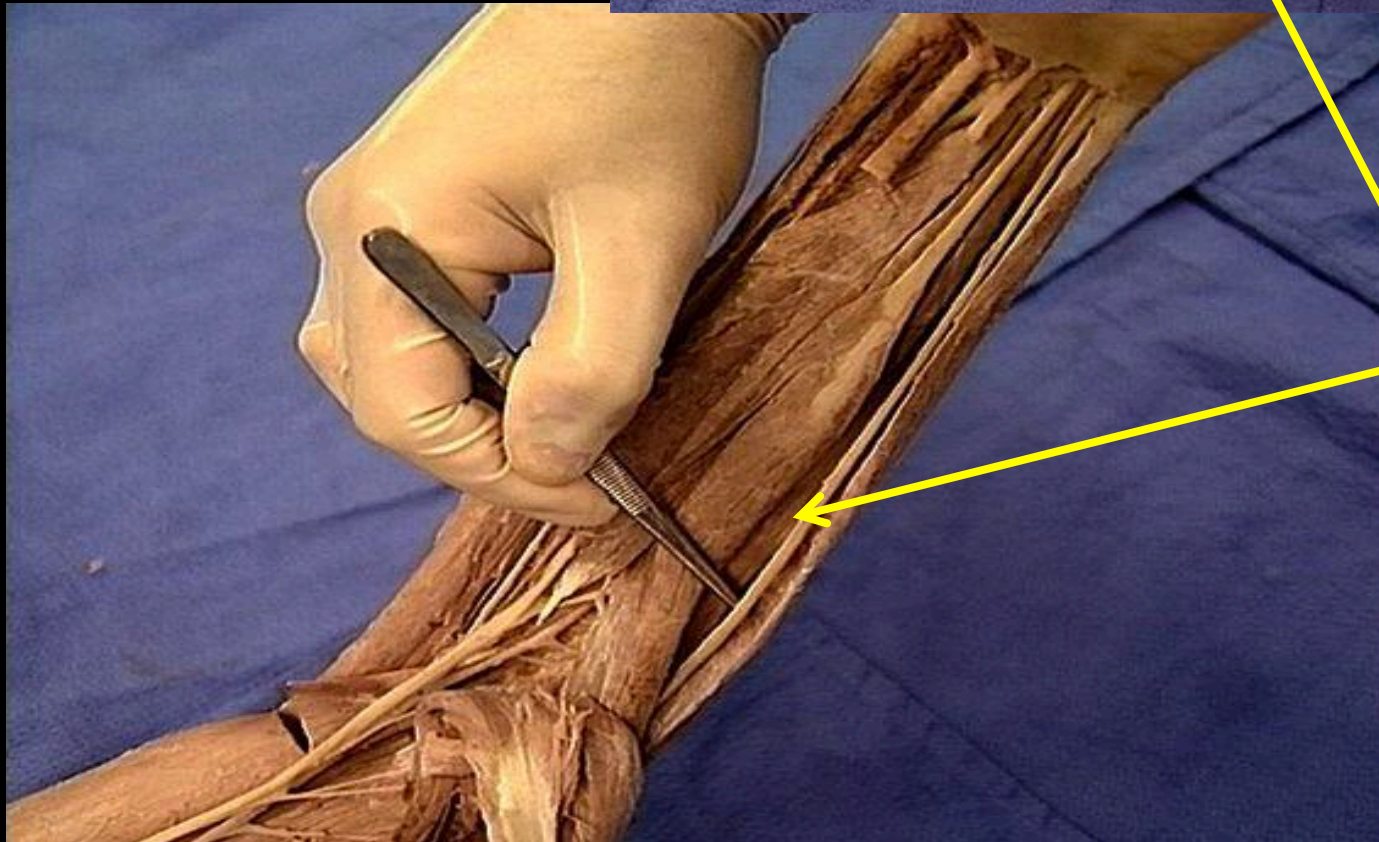
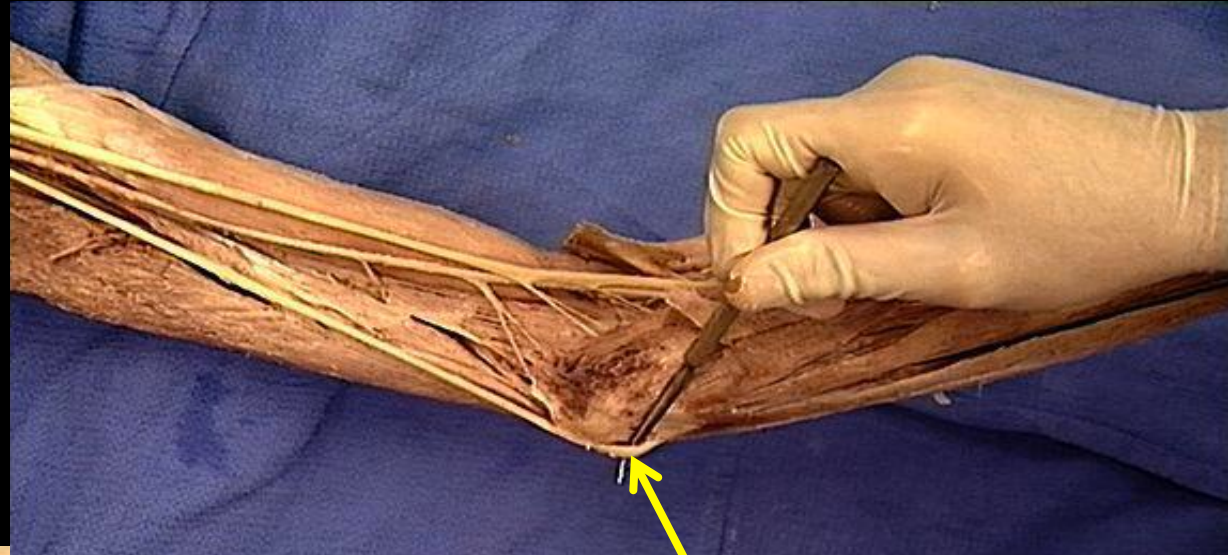


Ωλένιος
καμπτήρας του
καρπού



**Μέσο
νεύρο**





**Ωλένιο
νεύρο**