

TRANSCILIARY ORBITOFRONTOZYGOMATIC APPROACH TO LESIONS OF THE ANTERIOR CRANIAL FOSSA

W. Lee Warren, M.D.

Auburn Neurosurgery,
Auburn, Alabama

Gerald A. Grant, M.D.

Department of Pediatric Neurosurgery,
Duke University Medical Center,
Durham, North Carolina

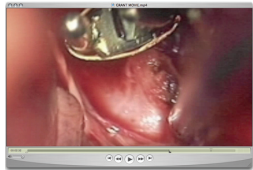Reprint requests:

Gerald A. Grant, M.D.,
Pediatric Neurosurgery,
Duke University Medical Center,
Box 3272,
Durham, NC 27710.
Email: gerald.grant@duke.edu

Received, July 28, 2007.

Accepted, September 26, 2008.

Copyright © 2009 by the
Congress of Neurological Surgeons



Traditionally, the approach to lesions in the midline region of the anterior cranial fossa involves using the bicoronal or “three-quarter Souttar” incision and a frontal or bifrontal craniotomy. In addition, most surgeons perform the pterional or frontotemporal approach to expose anterior circulation aneurysms, sometimes with modification to include the orbital rim and/or the zygoma (15–17). Although these approaches provide adequate exposure of the lesion in most cases, they also expose brain or require dissection or resection of areas that are not critical to the exposure of the lesion itself. The ideal approach to a particular lesion would be that which

OBJECTIVE: Several variations on the supraorbital craniotomy via a forehead or eyebrow incision have been described in the literature in recent years. A modification of this approach, the transiliary orbitofrontozygomatic approach, has been used by the authors as a minimally invasive method of approaching certain intracranial pathologies. The authors present their experience with this technique in 105 consecutive patients with tumors or aneurysms of the anterior cranial fossa.

METHODS: A transiliary keyhole approach was used in all cases. From June 1998 to June 2005, 37 tumors, 1 cavernous malformation, and 77 anterior circulation aneurysms were treated (67 females, 38 males; age range, 8–77 years) with an orbitofrontozygomatic approach via an eyebrow incision. Patients were followed by the authors at a single institution for 1 year postoperatively.

RESULTS: Of the 105 patients treated with a transiliary orbitofrontozygomatic approach, 2 (1.9%) developed a cerebrospinal leak. Two other patients (1.9%) very early in the series had persistent forehead asymmetry at 1 year postoperatively. Two patients who underwent surgery for a ruptured aneurysm experienced an intraoperative rupture, which was thought to be unrelated to the exposure. None of the operations had to be converted to a pterional craniotomy.

CONCLUSION: This approach was used in 105 consecutive patients who underwent operation for either tumors or aneurysms via an eyebrow incision. The transiliary orbitofrontozygomatic approach is associated with low surgical morbidity. Although experience with this technique is still limited, it is a viable alternative in cases in which the pathology resides in the midline or anterior fossa.

KEY WORDS: Cranial base, Keyhole approach, Minimally invasive, Orbitozygomatic approach, Skull base, Transiliary

Neurosurgery 64[ONS Suppl 2]:ons324–ons330, 2009

DOI: 10.1227/01.NEU.0000338951.29171.07

most directly exposes the area of interest, provides adequate exposure of all relevant anatomy, can be accomplished with the lowest possible morbidity, and does not compromise patient safety or the treatment objectives. Postoperative swelling, pain, operative blood loss, anesthesia time, length of hospitalization, and long-term cosmetic and functional sequelae (such as temporal muscle atrophy, malocclusion of the teeth, and scalp alopecia and numbness) are all relevant factors when considering the approach to be used for a particular patient (8, 9). In recent years, a movement has begun in Neurosurgery toward minimally invasive and more tailored approaches and away from traditional cranial base surgery dogma of the “more bone removal means less brain retraction.” Instead of a large craniotomy (frontotemporal), a small craniotomy can be used under the concept of keyhole surgery (Fig. 1), as described by Perneczky et al. (11), which is a minimally invasive approach to the anterior cranial fossa including the sellar and parasellar

ABBREVIATION: CSF, cerebrospinal fluid

Supplemental digital content is available for this article. Direct URL citations appear in the printed text and are provided in the HTML and PDF versions of this article on the journal's Web site (www.neurosurgery-online.com).

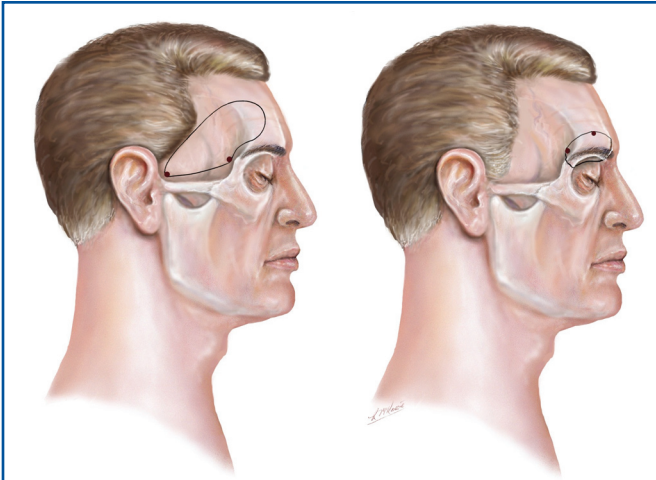


FIGURE 1. Illustration demonstrating the craniotomy differences of the classic pterional and transciiliary orbitozygomatic surgical approaches.

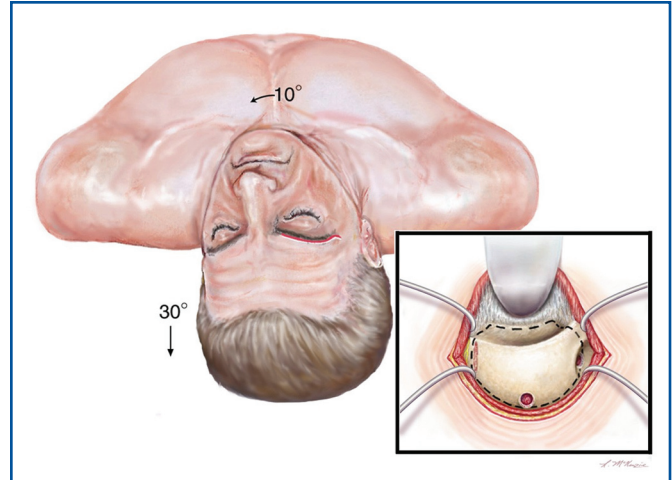


FIGURE 2. Illustration demonstrating the eyebrow incision and outlines of the orbitofrontozygomatic craniotomy.

areas. In general, the size of the craniotomy should be small, but large enough to operate without compromising the operative procedure. A modification of the supraorbital keyhole approach combining an orbital osteotomy with a supraorbital minicraniotomy to facilitate access to the anterior and middle cranial fossa has been described by Cohen et al. (2), Dare et al. (3), Figueiredo et al. (4, 5), Jallo and Bognar (7), Paladino et al. (10), and van Lindert et al. (13). Herein, we describe the patient demographics and technical details of the transciiliary orbitofrontozygomatic approach used to treat 105 patients.

SURGICAL TECHNIQUE

Preoperative Maneuvers and Positioning

After endotracheal intubation and general anesthesia are achieved, the patient's head is secured in a Mayfield holder, with the neck flexed and the vertex extended approximately 20 degrees (see Video, Supplemental Digital Content, <http://links.lww.com/A942>). The head is then rotated contralaterally approximately 15 degrees, and is slightly lateroflexed to the contralateral side. For tumors and ruptured aneurysms, a bolus of mannitol is administered to achieve better relaxation. In some cases, a lumbar drain or ventricular catheter is also inserted preoperatively if there is significant ventriculomegaly or intraventricular hemorrhage. The ventricular catheter is often inserted intraoperatively, directly through the exposed frontal lobe, and tunneled posteriorly to a previously prepped area of skin at the end of the procedure. The brow, upper lid, ipsilateral forehead, and temporal regions are sterilely prepped.

Soft Tissue Exposure

The brow is not shaved. An incision is made directly in the eyebrow, beveled slightly superiorly to keep parallel to the hair follicles to avoid cutting directly across the hair follicles.

Avoiding a direct cut across the hair follicles has been reported to prevent alopecia in the brow postoperatively (6). The incision extends from the supraorbital notch to the lateral aspect of the brow (Fig. 2). Occasionally, the incision must be extended more laterally to obtain a more superior or lateral exposure. If this is necessary, 1 cm of the laugh line at the lateral aspect of the brow is used to hide the incision.

Electrocautery is used with an insulated needle tip to precisely obtain hemostasis in the dermis and to dissect through the subdermal tissues. The supraorbital nerve is carefully dissected free from the tissues laterally attached to it and is preserved. The frontalis muscle is opened slightly above the line of the skin incision and reflected inferiorly. Blunt, Fukushima-style fishhook retractors on sterile rubber bands are then inserted to retract the skin edges superiorly and inferiorly. C clamps attached to each side of the head holder act as anchors to wrap the rubber bands around to provide tension. When all of the soft tissue exposure is complete, the rubber bands are stapled to the drapes to keep them flat and out of the way during the procedure.

The periosteum is then dissected off the frontal bone superiorly and inferiorly to the limits of the exposure. When the inferior dissection reaches the orbital rim, a freer elevator is used to carefully reflect the periorbita away from the orbital roof. If the orbit is inadvertently entered, bipolar electrocautery is used to condense the extruded fat and seal the defect. If the defect is large enough, a 4–0 braided nylon suture is used to reduce the bulk of the periorbital fat.

A Leyla bar is attached to the operating table and a third C clamp is fixed to it. A brain retractor blade is then used to gently retract the periorbita inferiorly to expose the orbital roof. After the dissection, the exposed bone should extend from the supraorbital notch approximately 2.5 cm superiorly and laterally to the keyhole. In addition, the first 1 cm of zygomatic arch is also exposed.

Craniotomy and Bony Exposure

The craniotomy includes the orbital roof, a portion of the frontal bone, and approximately 1 cm of the zygoma. A 4-mm rough diamond burr is used with an air-powered drill to create a small burr hole at the superior aspect of the exposed bone, approximately in the middle of the flap. Another hole is made at the keyhole, grooving the underside of the zygomatic arch as well. A small groove is then made just lateral to the supraorbital notch to expose the dura and flatten the orbital rim. The dura is dissected from the bone flap using a small right-angled dissector.

A footplated, right-angled craniotome is then used to make cuts in the orbital rim medially and laterally, with the lateral cut extending across the zygoma toward the temporal burr hole. The craniotome is then used to connect the burr holes and the craniotomy is reflected inferiorly, fracturing the orbital roof across the gap between the 2 grooves drilled previously. In 2 patients, small osteotomes were used to chisel the excessively thick orbital roof to prevent the fracture line from extending posteriorly toward the optic canal. If the frontal sinus is entered, it is exenterated and packed with temporalis muscle. When the defect is large, it is sealed with hydroxyapatite. Occasionally, the pathology being treated will require the surgeon to look more medially (such as in clipping a contralateral aneurysm). In these cases, the craniotomy should include more of the frontal process of the zygomatic bone. This additional zygoma removal allows the view to be angled more lateral-to-medial, extending the reach of the approach. Similarly, in cases in which middle fossa lesions or multiple aneurysms are being approached in the same sitting, the medial extent of the craniotomy can be extended to allow a more medial-to-lateral look. After the craniotomy is performed, attention is turned to maximizing the exposure and working corridor. The medial aspect of the sphenoid wing is drilled flat to the meningo-orbital band. The roof of the orbit is removed as far back as possible or drilled until it is very thin and flush with the cranial base to maximize the exposure. For aneurysms directed superiorly or tumors extending high into the suprasellar space, it is helpful to remove as much orbital roof as possible. The removal of the orbital roof along with slight retraction of the orbital contents often provides an additional 1 cm of working space and gives the surgeon a significant superior angle of exposure toward the third ventricle. Finally, the undersurface of the zygomatic arch and the underside of the craniotomy defect is drilled or undercut with a Kerrison rongeur (Codman/Johnson & Johnson, Raynham, MA) to maximize working angles and light.

Intradural Exposure

The dura is opened in a curvilinear manner and reflected inferiorly with the flap based on the orbital roof. The dural edges are secured with a 4-0 braided nylon suture. The exposed brain is protected with nonadhesive material, and the microscope is then used for the remainder of the procedure.

Brain relaxation is achieved by opening the opticocarotid cistern to release additional cerebrospinal fluid (CSF). Additional subfrontal arachnoid dissection can also be performed for bet-

ter brain relaxation if needed. At this point, the operation proceeds the same as any other approach.

Closure

The dura is closed in a watertight manner using a 4-0 braided nylon suture. If the dura cannot be completely closed, a patch is sutured into place and a dural sealant is applied. The bone flap is replaced and the orbital rim is carefully reapproximated with titanium microplates that are recessed for cosmesis. If proper alignment is difficult to achieve because of the amount of drilling required, the defect can be repaired using hydroxyapatite.

Wound closure is then accomplished in 3 layers. The frontalis muscle layer and dermis are closed using 3-0 absorbable sutures. Early in the series, the skin is closed using a 5-0 Prolene suture (Ethicon, Inc., Somerville, NJ) in a running subcuticular manner. The ends of the suture are tied together and secured to the forehead using a tincture of benzoin and 1 sterile adhesive strip. The Prolene suture is removed on postoperative day 5. More recently, the skin closure is performed using Dermabond (Ethicon, Inc.). When absorbable suture is used to close the skin, antibiotic ointment is applied to the wound as an emollient. In cases in which the periorbita is significantly breached, small dental rolls are taped to the upper lid as a pressure dressing to limit postoperative swelling.

RESULTS

The transcliliary orbitofrontozygomatic approach was used in 105 patients to treat a variety of anterior fossa cranial lesions (Table 1).

Patient Population

We reviewed clinical records of 105 consecutive patients (67 female, 38 male; age range, 8-77 years) in whom the transcliliary orbitofrontozygomatic approach was used at a single insti-

TABLE 1. Summary of patients who underwent surgery via the transcliliary orbitofrontozygomatic approach^a

Diagnosis	No. of patients (%)
Pituitary adenoma	2 (1.9)
Olfactory groove meningioma	4 (3.8)
Planum sphenoidale meningioma	10 (9.5)
Craniopharyngioma	11 (10.5)
Cavernous malformation (subfrontal)	1 (1.0)
Ophthalmic segment aneurysm	5 (4.8)
ACoM A aneurysm	60 (57.1)
PCoM A aneurysm	4 (3.8)
MCA	8 (7.6)
Total	105 (100)

^a ACoM A, anterior communicating artery; PCoM A, posterior communicating artery; MCA, middle cerebral artery.

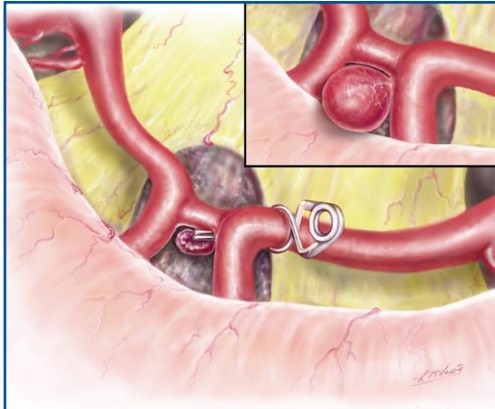


FIGURE 3. Artist illustration of an intraoperative panoramic view of optic nerves, optic chiasm, and anterior communicating artery complex.

tution during the period between June 1998 and June 2005. To evaluate whether this approach provided adequate accessibility and exposure to all these lesions, the intra- and postoperative courses of these patients were closely examined. The 37 tumors included planum sphenoidale meningiomas, cranio-pharyngiomas, olfactory groove meningiomas, and pituitary adenomas. There was 1 cavernous malformation resected via this approach in the inferior frontal lobe. For this procedure, intraoperative strip electroencephalogram recording was performed along the inferior frontal lobe surface for a patient with intractable seizures that were localized to this lesion. The approach provided sufficient exposure for this purpose. The 77 aneurysms were all of the anterior circulation and the majority of these were unruptured (41 of 77 patients).

Complications

In general, there was transient frontalis weakness that returned to normal within 30 days postoperatively (Fig. 3). Two patients (1.9%) did not recover fully at 6 months and 1 year postoperatively, but both had partial return of function. The weakness resulted from detachment of the frontal epicranial aponeurosis during the approach (12). Hypesthesia or sensory loss in the frontal area is much more common and occurs in every patient to varying degrees, although the numbness rarely causes the patient distress. The transient hypesthesia is attributable to the traction on the supraorbital nerve. No patients experienced temporal hollow as a result of atrophy of the temporalis muscle, and alopecia of the eyebrow was not observed.

Olfaction was not tested in every patient, although every patient was questioned about anosmia postoperatively. One patient (1%) who underwent resection of an olfactory groove meningioma reported unilateral anosmia, which still had not improved by 4 months postoperatively.

Two patients undergoing the transciliary orbitofrontozygomatic approach for ruptured anterior communicating artery aneurysms experienced intraoperative ruptures of their aneurysms. These ruptures, however, were not thought to be caused

by inadequate exposure, and adequate proximal control was achieved in both cases to enable clipping of the aneurysms. One of these 2 patients remained neurologically intact (Hunt and Hess Grade II); the other remained obtunded (Hunt and Hess Grade IV) and died after multiorgan system failure caused by sepsis.

Two patients developed postoperative CSF leaks. One patient developed CSF rhinorrhea postoperatively, which required reopening of the craniotomy. This patient underwent a transciliary orbitofrontozygomatic approach to expose an aneurysm of the internal carotid artery. The frontal sinus was entered during the approach because the sinus extended into the far lateral position and the dura was inadvertently opened at the time of the exposure. At the time of reoperation, an abdominal fat graft was harvested and the frontal sinus was cranialized with a free temporalis muscle graft placed into the nasofrontal suture. The patient had no recurrent CSF leak and was discharged neurologically intact. The second patient underwent this approach for a periorbital carotid artery aneurysm and was found to have an unrecognized air cell in the roof of the orbit that required reoperation for repair of the leak to seal the air cells with bone wax.

DISCUSSION

Novel surgical approaches must offer certain advantages over traditional, more standard approaches with equal or lower morbidity. The transciliary orbitofrontozygomatic approach offers the surgeon ample working space in both the mediolateral and superoinferior directions. It requires less brain retraction and does not expose the temporal lobe and sylvian fissure. The approach also allows the accomplishment of key surgical objectives such as proximal control. With this approach, proximal control of the A1 segment is achieved much earlier than with more traditional approaches. A panoramic view of the anterior communicating artery complex is achieved, in which the bilateral A1, A2, and recurrent arteries of Heubner can be visualized (Figs. 4 and 5). In addition, both optic nerves are visualized to

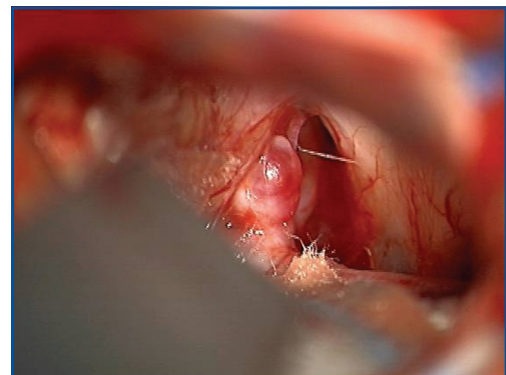


FIGURE 4. Intraoperative view from an operative microscope during a transciliary orbitofrontozygomatic approach to an anterior communicating artery aneurysm.

allow tumor resection in both opticocarotid windows and on both sides of the pituitary stalk. Because of the head position and the early access into the cisterns, the frontal lobe falls significantly off the frontal base, and in many cases there is essentially no brain retraction required.

This approach is not intended to replace the more traditional pterional or bifrontal transbasal approaches. It can be viewed as a viable alternative in cases in which the pathology resides in the midline or anterior fossa. The authors did find it helpful to refine this technique in the cadaver laboratory before application in the operating room. A low basal approach is created for lesions of the circle of Willis, which allows for excellent exposure to dissect the sylvian fissure and middle cerebral artery. Apuzzo (1) stated that the transciliary subfrontal approach is the shortest way to reach the terminal plate. We learned that inferiorly directed carotid artery aneurysms, posterior communicating artery aneurysms, and anterior choroidal artery aneurysms are all treatable using this approach, although some might be more easily handled via the pterional route. Others (14) have reported that the space limitation for dissection and clipping is more difficult for the posterolateral circulation aneurysms such as the basilar or posterior cerebral artery aneurysms. In a case of a large tumor or tight brain secondary to a massive subarachnoid hemorrhage, the surgical corridor that is possible with this approach could be limited if CSF drainage was not accomplished. Lesions in the sella or low in the third ventricle, however, are very feasible with this approach. Sánchez-Vázquez et al. (12) have reported excellent exposure of the sellar structures via a keyhole approach after drilling down the planum sphenoidale in patients with a prefixed optic chiasm. A customized tray of long bayoneted and angled instruments and the use of an endoscope as an adjunct to improve lighting at the deepest part of the exposure are advantageous in this technique.

Modifications to the technique are appropriate depending on the lesion being treated. Aneurysms, for example, require special attention to establishing proximal control and a plan to handle brain swelling should it occur (although these things are also true of more traditional operations). The side of approach is less important in midline aneurysms than it is in a true pterional approach, because the contralateral A1 and internal carotid artery are easily reachable in the transciliary approach before aneurysm dissection. Thus, some aneurysms that project anteriorly or laterally can be safely approached from the side opposite of their parent artery to avoid the dome before establishing proximal control. Tumors, likewise, can present the need to modify the technique. For example, a tumor with a large cystic component on one side should be approached from the cystic side, because early decompression of the cyst will promote ease of resection of the solid portion. The head position affects the line of site once the craniotomy is performed, so careful attention to detail in positioning is crucial to a successful outcome. For example, more head turn is needed for anterior communicating artery aneurysms than for more lateral lesions.

All procedures have their limitations, and this approach is no exception. We learned that giant aneurysms (>2 cm) are

challenging to handle through this approach because of the need to manipulate multiple aneurysm clips in the narrowed surgical corridor. Similarly, some large and especially heavily calcified tumors are best treated through a more traditional open exposure. This approach was performed for several middle cerebral artery aneurysms and it was found that posteriorly projecting lesions arising from a long M1 segment are difficult to reach and should be considered a contraindication to this approach (unpublished observation). The authors do not consider brain swelling or hydrocephalus a limitation to this approach. As in standard approaches, however, the surgeon must be aware of these factors and plan for them before the procedure.

The advantages of this approach are not chiefly cosmetic. Rather, the low anterior corridor of this approach provides ample exposure of many pathologies in the midline and anterior fossa, as well as allowing access to the orbit. Furthermore, an inferior-to-superior trajectory allows the surgeon to work as high as the anterior third ventricle. This view is enhanced by removing the orbital roof, providing the ability to look up superiorly. However, a subfrontal approach alone can be enough for anterior fossa cranial lesions, such as olfactory groove and planum sphenoidale meningiomas.

Surgical targets are reachable with the transciliary orbitozygomatic approach without the disadvantages of unnecessary temporal lobe retraction, exposure of the Sylvian fissure, and potential risk to the middle cerebral artery. However, complications of the pterional and other approaches are low in experienced hands. A careful review of the literature will reveal much research addressing temporalis muscle atrophy, chewing problems, mandibular pain, scalp alopecia, and numbness around the incision of a pterional craniotomy. We have noted a continued decreased incidence of residual forehead weakness with this approach as well.

The work of those who have advocated minimally invasive approaches has led to major advances in neurosurgery over the years. We emphasize that this operation provides excellent exposure, and we do not consider the skills necessary to perform it to be outliers in the spectrum of those possessed by microsurgeons in the modern era. As we would state emphatically for any new technique, practice in the laboratory is essential to safely perform this operation. However, surgeons who perform microvascular decompression for trigeminal neuralgia will find the exposure and feel of this approach to be very familiar and will recognize that they already possess the principles required for its safe performance.

In summary, the transciliary orbitofrontozygomatic approach for lesions of the anterior fossa and intracranial midline is safe and effective, and should be considered as an alternative to traditional methods.

CONCLUSIONS

The transciliary orbitofrontozygomatic approach provides full accessibility and exposure to many lesions of the anterior cranial fossa and key anatomic landmarks surrounding the lesion.

Overall low morbidity to the patient from postoperative swelling and healing and no added operative morbidity in treating the lesion are compelling reasons to consider the transciliary orbitofrontozygomatic approach. It provides excellent exposure to selected midline lesions. As our skill set with the minimally invasive procedure improves in conjunction with available microinstruments and optics for working through narrow corridors and modern microneurosurgical techniques, this approach will become more integrated into our daily practice.

Disclosure

The authors do not have any personal or institutional financial interest in the drugs, materials, or devices described in this article.

REFERENCES

1. Apuzzo ML: *Surgery of the Third Ventricle*. Philadelphia, Lippincott Williams & Wilkins, 1998, ed 2.
2. Cohen AR, Pernecky A, Rodziewicz GS, Gingold SI: Endoscope-assisted craniotomy: Approach to the rostral brain stem. *Neurosurgery* 36:1128–1130, 1995.
3. Dare AO, Landi MK, Lopes DK, Grand W: Eyebrow incision for combined orbital osteotomy and supraorbital minicraniotomy: Application to aneurysms of the anterior circulation. Technical note. *J Neurosurg* 95:714–718, 2001.
4. Figueiredo EG, Deshmukh V, Nakaji P, Deshmukh P, Crusius MU, Crawford N, Spetzler RF, Preul MC: An anatomical evaluation of the mini-supraorbital approach and comparison with standard craniotomies. *Neurosurgery* 59 [Suppl 2]:ONS212–220, 2006.
5. Figueiredo EG, Deshmukh P, Zabramski JM, Preul MC, Crawford NR, Siwanuwatn R, Spetzler RF: Quantitative anatomic study of three surgical approaches to the anterior communicating artery complex. *Neurosurgery* 56:397–405, 2005.
6. Frati A, Pichiari A, Esposito V, Frati R, Delfini R, Cantore G, Bastianello S, Santoro A: Aesthetic issues in neurosurgery: A protocol to improve cosmetic outcome in cranial surgery. *Neurosurg Rev* 30:69–76, 2007.
7. Jallo G, Bogner L: Eyebrow surgery: The supraorbital craniotomy: Technical note. *Neurosurgery* 59 [Suppl 1]:ONS157–ONS158, 2006.
8. Kang DH, Park JC, Kim SO, Hamm IS: Intubation difficulty in patient with pseudoankylosis of temporo-mandibular joint after pterional craniotomy. *J Korean Neurosurg Soc* 36:166–167, 2004.
9. Mori K, Osada H, Yamamoto T, Nakao Y, Maeda M: Pterional keyhole approach to middle cerebral artery aneurysms through an outer canthal skin incision. *Minim Invasive Neurosurg* 50:195–201, 2007.
10. Paladino J, Pirker N, Stimac D, Stern-Padovan R: Eyebrow keyhole approach in vascular neurosurgery. *Minim Invasive Neurosurg* 41:200–203, 1998.
11. Pernecky A, Muller-Forell W, van Lindert E, Fries G: *Keyhole Concept in Neurosurgery*. New York, Thieme Medical Publishers, 1999.
12. Sánchez-Vázquez MA, Barrera-Calatayud P, Mejía-Villela M, Palma-Silva JF, Juan-Carachure I, Gomez-Aguilar JM, Sanchez-Herrera F: Transciliary subfrontal craniotomy for anterior skull base lesions. Technical note. *J Neurosurg* 91:892–896, 1999.
13. van Lindert E, Pernecky A, Fries G, Pierangeli E: The supraorbital keyhole approach to supratentorial aneurysms: Concept and technique. *Surg Neurol* 49:481–490, 1998.
14. Wongsirisuwan M, Ananthanandorn A, Prachasinchai P: The comparison of conventional pterional and transciliary keyhole approaches. *J Med Assoc Thai* 87:891–897, 2004.
15. Yaşargil MG, Fox JL, Ray MW: The operative approach to aneurysms of the anterior communicating artery. *Adv Tech Stand Neurosurg* 2:113–170, 1975.
16. Yaşargil MG, Reichman MV, Kubik S: Preservation of the frontotemporal branch of the facial nerve using the interfascial temporalis flap for pterional craniotomy: Technical article. *J Neurosurg* 67:463–466, 1987.
17. Zabramski JM, Kiris T, Sankhla SK, Cabiol J, Spetzler RF: Orbitozygomatic craniotomy. Technical note. *J Neurosurg* 89:336–341, 1998.

Supplemental digital content is available for this article. Direct URL citations appear in the printed text and are provided in the HTML and PDF versions this article on the journal's Web site (www.neurosurgery-online.com).

COMMENTS

In this well-written report, Warren and Grant present their relatively large experience (n = 105) with the transciliary orbitofrontozygomatic approach to lesions of the anterior cranial fossa and report excellent cosmetic and morbidity outcomes.

This report tackles one of the important philosophical and controversial issues within the field of cranial base surgery.

The definition of the term “minimally invasive” remains subjective and vague when discussing approaches to the cranial base, and clearly there is a lack of a standard definition within this subspecialty as to whether the emphasis is on subtle cosmetic differences or potential invasiveness to eloquent brain and cerebrovascular structures. The term “minimally invasive” in the context of cranial base surgery reflects the extent of the skin incision and the size of the craniotomy. The latter concept has to be weighed against the extent of “invasiveness” to the brain tissue (i.e., the extent of brain retraction), which is more likely to occur in the scenario in which the initial access trajectory to the cranial base is more limited. The limited window combined with the lack of wide splitting of the sylvian fissure will almost certainly require more retraction to access specific areas within the basal cisterns when compared with the frontotemporal incision-based orbitozygomatic approach with the additional transsylvian trajectory.

The second important element is the circumferential control of the lesion. This is especially important in the microsurgical clipping/reconstruction of cerebral aneurysms. A limited trajectory approach certainly allows the visualization of the aneurysm and the parent vessel; however, the ability to reconstruct the aneurysm and apply clips from more than 1 direction increases the safety margin of the procedure, especially for more complex and/or giant aneurysms. In my practice, we routinely use the frontotemporal skin incision combined with a tailored cranio-orbitozygomatic approach, which is further combined with wide splitting of the proximal sylvian fissure for lesions of the anterolateral cranial base. This combination allows us to almost completely avoid the use of self-retaining retractors. In my opinion, the latter orbitozygomatic approach is more “minimally invasive” to the brain when compared with the one presented by the authors. The authors have provided an elegant presentation of the transciliary orbitofrontozygomatic approach and achieved excellent results.

Saleem I. Abdulrauf
St. Louis, Missouri

In this article, the authors have presented a variation of the supraorbital keyhole approach, which is predominantly useful for anterior fossa lesions and anterior communicating artery aneurysms. It is worth noting that the approach corridor is entirely subfrontal, without any benefit of a transsylvian exposure. I think that an eyebrow incision is quick but has some cosmetic disadvantages in the long run, especially in young patients. Temporalis atrophy and dysfunction after frontotemporal approaches are definite problems but are related to poor operative technique. They are eliminated by careful muscle handling and the placement of a titanium disc or titanium mesh (and bone cement, if needed) in the region of the pterion (where bone has been drilled away) during closure. In fact, after healing is completed, observers frequently have trouble discerning which side had a craniotomy, without looking at the medical record. Therefore, the main

advantage of this orbitociliary approach is speed, when the brain is relaxed, and the lesion is appropriate.

The entire concept of a "keyhole approach," as it exists at present, is flawed, since we do not have the instruments to manipulate structures through a curvilinear space. This can be easily verified by making holes of different sizes in a bell pepper and trying to grasp and extract the seeds with various instruments. An endoscope with working channels greatly enhances the dexterity, and 2 ports (or holes) also increase the usefulness of the endoscope. Although a lot can be seen through a "keyhole," the ability to manipulate is limited with present instruments. If there is bleeding, then the situation becomes much more difficult.

Another problem with a tiny approach is brain retraction. If the brain falls away because of cerebrospinal fluid drainage, then there is no problem. But if the brain has to be retracted even minimally, the brain has to be displaced somewhere (since it is a fluid), and it is less traumatic to the brain if there is a craniotomy with a dural opening, which allows brain shift.

Nevertheless, surgeons must practice and learn these keyhole approaches in the laboratory, which will improve their abilities with traditional craniotomies. Each surgeon can then find the optimal median between too much exposure and too little exposure. The authors have presented a well-written article with a balanced perspective.

Laligam N. Sekhar
Seattle, Washington

Warren and Grant, in a well-written and well-illustrated article, have detailed their initial experience with a transciliary variation of the orbitozygomatic approach in the treatment of slightly more than 100 patients. The typical surgical indication was an aneurysm involving the anterior circulation. They achieved satisfactory results, and no significant additional morbidity or mortality could be attributed to the approach per se.

The novelty associated with the authors' approach (i.e., the transciliary aspect) is primarily a cosmetic issue. However, whether an eyebrow incision is cosmetically superior to a traditional incision is open to debate.

We believe that a traditional pterional skin incision, buried well behind the hair line, is cosmetically superior to an incision in the most visible portion of the face: the eye. As the authors themselves noted, the same craniotomy and trajectory can be achieved from a standard skin incision. Moreover, the authors report that frontalis paresis is to be expected with this approach, although it evidently recovers in most cases. From a cosmetic perspective, this paresis is a significant disadvantage of their approach.

The price of this questionable cosmetic benefit is a dramatic loss in flexibility. Not all anterior circulation aneurysms should be considered ideal candidates for a subfrontal approach; rather, the direction of the projection of the aneurysm dome must also be considered. Even for aneurysms involving the anterior communicating artery, a more lateral approach (as provided by a more traditional modified orbitozygomatic approach, incorporating a pterional craniotomy) may sometimes improve the surgeon's ability to visualize the aneurysm and critical perforators. Nonetheless, the authors have con-

vincingly demonstrated that an orbitozygomatic craniotomy can be performed through a transciliary approach with satisfactory results in appropriately selected patients.

Gregory P. Lekovic
Los Angeles, California

Robert F. Spetzler
Phoenix, Arizona

The authors describe a series of 105 patients with anterior cranial fossa pathology, including 77 anterior circulation aneurysms and 37 tumors. There are several statements in this report that should be emphasized, including the authors' recommendation that the approach be first exercised in the cadaver laboratory before being applied in the operating room and that patients with large tumors and tight brains probably deserve a more classic approach. The latter statement brings us to the issue of indications for this approach that should be commensurate to the pathology at hand as well as to the surgeon's comfort and experience with minimal exposures. Indeed, surgical minimalism is not always synonymous with minimal invasiveness.

My personal experience with this approach is limited to 2 patients with orbitofrontal (gyrus rectus) oligodendrogliomas that were resected in a gross total fashion using the transciliary approach.

Ivan S. Ciric
Evanston, Illinois

The authors describe the transciliary orbitofrontozygomatic approach, which is a variation of the recently popularized supraorbital keyhole approach. It was used in 105 consecutive patients and was associated with low approach-related morbidity. The authors' experience proved that, with this less invasive technique, anterior circulation aneurysms and tumors of the anterior cranial fossa can be adequately exposed. Furthermore, the complications related to the alternative approaches could be avoided.

Our favorite approach to the anterior cranial base and the sellar, suprasellar, and parasellar regions, in the past 10 years, has been the so-called "frontolateral approach." The extent of exposure that it provides is similar to that of the transciliary orbitofrontozygomatic approach, but it is even less invasive and is related to a lower risk of complications. To avoid a visible scar or eyebrow alopecia, we perform the skin incision behind the hair line. The size of the craniotomy is usually 25 to 35 mm in width and 20 to 25 mm in height. Medially, the craniotomy should reach the supraorbital notch. However, we try to avoid entering the frontal sinus and, if necessary, modify the position of the craniotomy accordingly. Thus, in the case of a large frontal sinus, the craniotomy is positioned slightly more laterally. The lower end of the craniotomy is just above the supraorbital margin. We do not think that the removal of the orbital roof or parts of the zygoma is justified: it does not lead to considerable advantages or increased exposure.

Venelin M. Gerganov
Madjid Samii
Hannover, Germany

ADVERTISING

Inquiries regarding advertising in **NEUROSURGERY** should be directed to:

Robert Williams
Lippincott Williams & Wilkins
530 Walnut Street
Philadelphia, PA 19106-3621
TEL: 215/521-8394
FAX: 215/827-5816
EMAIL: bob.williams@wolterskluwer.com