

Osteoplastic Lateral Suboccipital Approach for Acoustic Neuroma Surgery: Technical Note

Abolghassem Sepehrnia, M.D., Ulrich Knopp, M.D.

Department of Neurosurgery, University of Lübeck, Lübeck, Germany

OBJECTIVE: Persistent headache remains a significant problem in a small group of patients after acoustic neuroma surgery via the lateral suboccipital approach. We describe a modified technique of osteoplastic lateral suboccipital craniotomy for surgery of the cerebellopontine angle. This simple and elegant technique provides a superior cosmetic result and a significant reduction in patients' symptoms.

METHODS: We report on our series of 75 patients who underwent surgery for acoustic neuroma. The maximal follow-up period was 4 years.

RESULTS: No patients reported headache postoperatively. Cerebrospinal fluid fistulae were not observed.

CONCLUSION: This modified approach minimizes cerebellar retraction, and the neural and vascular structures can be preserved under direct visualization of the tumor. This lateral suboccipital approach is a useful modification of previous approaches in acoustic neuroma surgery. It provides successful tumor resection and excellent functional results. (Neurosurgery 48:229–231, 2001)

Key words: Acoustic neuroma, Cranioplasty, Headache

Sir Charles Ballance (1) is credited with performing the first successful removal of an acoustic neuroma, in 1894. Ten years later, Krause (11) reported a unilateral osteoplastic operation. In 1925, Dandy (4) described a technique for unilateral suboccipital exposure, internal decompression, unroofing of the internal auditory canal, and total removal of the tumor. This technique provides the basis for the current operative approach (2, 3, 6, 7, 12). Aside from tumor resection and preservation of nerve function (10), persistent headache and neck pain remain significant problems in a small percentage of patients (8, 9, 13, 14).

The restoration of anatomy using the osteoplastic bone flap technique produces superior cosmetic results and seems to reduce the frequency of reported postoperative head and neck

pain. In the retrosigmoid approach, one of the fundamental determinants of success or failure of functional preservation and total tumor removal is avoidance of the bony labyrinth and exposure of the fundus during removal of the posterior wall of the internal auditory canal (3). In the fundus area, lateral structures serve as landmarks so that the angle of approach may be adapted to the working angle required.

PATIENTS AND METHODS

Thin-section bone window computed tomographic scans of the temporal bone provide valuable information when the morphometric variability of the temporal bone is considered. The transverse sinus extends from the region of the inion to the asterion (5). This point where the lambdoid, parietomastoid,

and occipitomastoid sutures merge corresponds to the level of the transverse sigmoid junction. The axis of the sigmoid sinus can then be determined by connecting the asterion with the tip of the mastoid process, bearing in mind the variable position of the asterion. Exposure of the sigmoid and transverse sinuses at the anterior and lateral limits of a near-maximal anterior angle of approach reduces the necessary degree of cerebellar retraction.

A linear, approximately 8-cm retroauricular skin incision is performed to expose the occipital bone and mastoid. One burr hole is made at the junction of the transverse and sigmoid sinuses. The posterior fossa dura and the lower part of the sinus are separated from the bone by using a blunt hook. The medial margin of the sigmoid sinus is exposed in a stepwise fashion, and the mastoid cells are removed with a high-speed drill. After the sigmoid sinus is unroofed, the retrosigmoid dura and the transverse sinus can be separated easily with the blunt hook.

The craniotomy is performed at a size appropriate for the tumor being removed. During our series, the greatest angle of view expected with maximal cerebellar retraction was estimated to be 50 to 60 degrees. In a large number of patients, this limited angle of approach renders exposure of the fundus of the internal auditory canal virtually impossible without fenestration of the bony labyrinth. It is important that the exact morphology and morphometric relationships for each patient's temporal bone be determined preoperatively from computed tomographic data (Fig. 1) and intraoperatively according to the chosen craniotomy. At the conclusion of the operation, the dura is closed in watertight fashion, and the bone flap is replaced and affixed by two CranioFix buttons (Aesculap, Tuttlingen, Germany) (Fig. 2).

RESULTS

Seventy-five patients underwent surgery for acoustic neuroma using the approach described here. The maximal

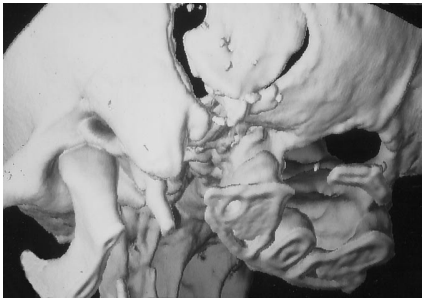

FIGURE 1. Three-dimensional reconstruction of a computed tomographic scan of the bony cranium demonstrating the extent of the craniotomy.

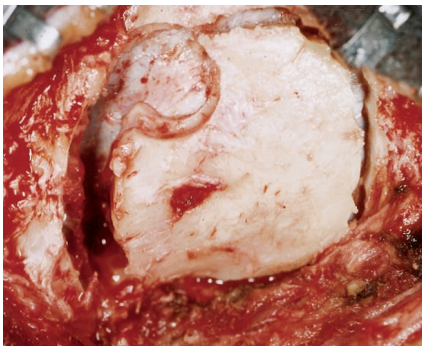


FIGURE 2. Photograph of the cranium after bone flap replacement showing the economic bone resection.

follow-up period was 4 years. None of the patients reported headache or neck pain, and cerebrospinal fluid fistulae were not observed postoperatively.

DISCUSSION

Surgery via a retrosigmoid approach can cause profound pain in the head and neck regions. This type of pain may be caused by the adherence of the nuchal muscles to the retrosigmoid dura. Minor complications such as incision pain and headache have been reported after cerebellopontine angle surgery. Schessel et al. (13) observed postoperative pain in 64% of patients who underwent craniectomy via the lateral suboccipital approach, compared with no reported pain in patients who underwent surgery with a translabyrinthine approach. Studies have not yet been performed to assess differences between postoperative pain in midline versus lateral approaches.

CONCLUSION

This modified lateral suboccipital approach minimizes pain-related complications and cerebellar retraction. The neural and vascular structures can be preserved under direct visualization of the tumor. On the basis of our experience, this approach seems to be a useful modification of previous approaches for acoustic neuroma surgery, providing successful tumor resection and excellent functional and cosmetic results.

Received, December 8, 1999.

Accepted, August 31, 2000.

Reprint requests: Abolghassem Sepehrnia, M.D., Department of Neurosurgery, University of Lübeck, Ratzeburger Allee 160, 23538 Lübeck, Germany. Email: sepehrni@medinf.mu-luebeck.de

REFERENCES

- Ballance CA (ed): *Some Points in the Surgery of the Brain and Its Membranes*. London, Macmillan and Co., 1907, pp 405–418.
- Brackmann DE: Middle fossa approach for acoustic tumour removal. *Clin Neurosurg* 38: 603–618, 1992.
- Cohen NL: Retrosigmoid approach for acoustic tumour removal. *Otolaryngol Clin North Am* 25:295–310, 1992.
- Dandy WE: An operation for the total removal of cerebellopontile (acoustic) tumours. *Surg Gynecol Obstet* 41:129–148, 1925.
- Day JD, Tschabitscher M: Anatomic position of the asterion. *Neurosurgery* 42:198–199, 1998.
- Day JD, Kellogg JX, Tschabitscher M, Fukushima T: Surface and superficial surgical anatomy of the posterolateral cranial base: Significance for surgical planning and approach. *Neurosurgery* 38:1079–1084, 1996.
- Gianotta SL: Translabyrinthine approach for removal of medium and large tumours of the cerebellopontine angle. *Clin Neurosurg* 38:589–600, 1992.
- Harner SG, Beatty CW, Ebersold MJ: Headache after acoustic neuroma excision. *Am J Otol* 14: 552–555, 1993.
- Harner SG, Beatty CW, Ebersold MJ: Impact of cranioplasty on headache after acoustic neuroma removal. *Neurosurgery* 36:1097–1100, 1995.
- Koos WT, Perneczky A: Suboccipital approach to acoustic neuromas with emphasis on preservation of facial nerve and cochlear nerve function, in Rand RW (ed): *Microneurosurgery*. St. Louis, C.V. Mosby, 1985, pp 335–365.
- Krause F (ed): *Chirurgie des Gehirns und Rückenmarks nach eigenen Erfahrungen*. Berlin, Urban & Schwarzenberg, 1904.
- Ojemann RG: Microsurgical suboccipital approach to cerebellopontine angle tumours. *Clin Neurosurg* 25:461–479, 1978.
- Schessel DA, Rowed DW, Nedzelski JM, Feghali JG: Postoperative pain following excision of acoustic neuroma by the suboccipital approach: Observations on possible cause and potential amelioration. *Am J Otol* 14:491–494, 1993.
- Wiegand DA, Fickel V: Acoustic neuroma: The patient's perspective—Subjective assessment of symptoms, diagnosis, therapy, and outcome in 541 patients. *Laryngoscope* 99:179–187, 1989.

COMMENTS

The authors present their experience in performing an osteoplastic lateral suboccipital approach for acoustic neuroma resection. The concept is based on the surgical principle of reconstituting all anatomic layers that were breached during the operation. Surgeons who routinely perform this approach in a craniectomy-style opening are familiar with patients' experiencing persistent headaches after the operation. Several patients who have reported persistent headaches after undergoing a retrosigmoid approach at other institutions have been referred to our center for removal of recurrent tumors. Cranioplasties performed after the procedure have consistently resulted in relief from these headaches. We perform the retrosigmoid approach in a style similar to the authors' method: replacing the bone flap before closure. We also have simply placed a fat graft over the exposed retrosigmoid dura, which is also effective in preventing postoperative headaches.

The probable mechanism of such headaches is scarring of the musculature to exposed dura when a bone flap or other barrier is not placed after the procedure. These headaches can be accentuated by tension and stress. In some patients, they may be brought on simply by bending the patient's head forward into a flexed position.

The author's work is clearly consistent with our institutional experience. It provides compelling evidence that most chronic postoperative headaches after a lateral suboccipital craniotomy can be prevented with attention to a basic neurosurgical principle. In such patients, a frontotemporal approach that includes unroofing of the orbit, the optic canal, and superior orbital fissure, as well as removal of the anterior clinoid process,

is sufficient for adequate exposure. As with any cranial base tumor, the strategic approach to tumors involving the orbit should be tailored to the individual lesion.

John Diaz Day
Los Angeles, California

Sepehrnia and Knopp report on an osteoplastic bone flap technique for surgery of cerebellopontine angle tumors. This procedure is probably not used by many surgeons in the world. Osteoplastic bone flap replacement certainly helps to decrease postoperative headaches. It also reduces postoperative cerebrospinal fluid fistulae and pseudomeningoceles through exertion of counterpressure at the opening site. Other authors, such as Samii, replace the bone with an acrylic cranioplasty (personal communication). This provides the same advantage but carries some risk of infection near the mastoid cells. The technical problem is the design of a perfect bone flap; otherwise, a craniectomy must be performed to achieve the proper open-

ing, which creates a large gap on at least one side after the bone is repositioned.

Bernard George
Paris, France

This technical note describing the osteoplastic method of lateral suboccipital craniotomy is short but useful. This procedure improves the cosmetic result for patients with slender necks. It would have been useful if the authors had provided contraindications to avoid surgical complications, such as in patients with thick and narrow crania of the posterior fossa, or patients with large emissary veins from the sigmoid sinus. I hope that in another article, the authors will publish their current data related to craniectomy and headache.

Takeshi Kawase
Tokyo, Japan

In this article, Sepehrnia and Knopp discuss the role of bone flap replacement and fixation for the prevention of postoperative headaches in patients undergoing the lateral suboccipital ap-

proach for acoustic neuroma surgery. We perform a C-shaped skin incision, followed by reflection of muscles in a layered fashion and elevation of the bone flap. After closing the dura, we replace the bone flap and anchor it in position. A cranioplasty is performed for any residual bony defect, followed by layered closure of the musculocutaneous flap. With this technique, the incidence of postoperative headaches in patients who have undergone surgery for an acoustic neuroma via a lateral suboccipital approach has been negligible in our series. This method also seems to reduce the incidence of postoperative pseudomeningocele formation. In a large number of centers, this approach is combined with the osteoplastic technique to remove these tumors. Other centers have not reported similar results to those of Sepehrnia and Knopp, however.

Kalavakonda Chandrasekhar
Laligam N. Sekhar
Annapuram, Virginia

Research Award Applications Available

The American Brain Tumor Association is accepting applications for Basic Research Fellowships and Translational Research Grants to begin July 1, 2001.

The Basic Research Fellowships are \$60,000 awards for 2 years. The fellowships provide salary support to postdoctorates who have demonstrated the potential to conduct basic brain tumor research. Eligible candidates are M.D.s within 2 years of residency completion or Ph.D.s with no more than 30 months postdoctoral laboratory experience.

The Translational Research Grants are 1 year \$50,000 awards. This is preclinical research beyond the molecular level. Human studies are excluded. Eligible candidates are M.D.s who have up to 5 years postresidency and have attained Junior Faculty to Assistant Professor stature or Ph.D.s who have no more than 5 years postdoctoral laboratory experience.

Pediatric fellowship and grant applications are strongly encouraged. Eligibility requirements for pediatric fellowship applicants may vary from those of other applicants, depending on their training programs.

Candidates for all awards must be citizens or permanent residents of the United States or Canada. The deadline for completed applications is January 4, 2001.

Obtain applications from:

American Brain Tumor Association
Tel: 847/827-9910
Fax: 847/827-9918
Email: info@abta.org