

Suprasellar Meningiomas

Ivan Ciric, M.D., Sami Rosenblatt, M.D.

Division of Neurosurgery, Evanston Northwestern Healthcare, Evanston Hospital,
Northwestern University Medical School, Evanston, Illinois

We describe some of the conceptual nuances and technical details that we think were important in influencing the outcomes of the surgical treatment in our patients with tuberculum sellae (TS) and diaphragma sellae (DS) meningiomas. *Table 1* lists our experience with these tumors. Included in this series were TS and DS meningiomas, as well as three clinoid meningiomas that also involved the dura of the TS, the DS, or both. Pretubercular meningiomas were not included in this series.

CONCEPTUAL NUANCES

When evaluating the magnetic resonance imaging (MRI) scan of a patient with a TS or DS meningioma, one of our main focuses is to analyze the location of the carotid artery and anterior cerebral artery (ACA) complex in relationship to the meningioma. The posterolateral position of the carotid arteries and the posterosuperior position of the ACA complex usually predict a relatively easy and safe complete surgical removal of the tumor (*Fig. 1*). Conversely, if the meningioma is insinuated into the floor of the third ventricle behind the ACA complex, complete tumor removal may prove difficult. A consistent surgical anatomic relationship exists between the tumor capsule and the ACA complex, including the perforator vessels, in that the ACA complex and the perforator vessels are separated from the tumor capsule by a layer of arachnoid. This is not necessarily a single layer of arachnoid; it may contain several layers of differently oriented arachnoid trabeculae.

The surgical dissection is performed between the arachnoid and the tumor capsule, thus leaving a layer of arachnoid covering the ACA and the perforators. An arachnoid layer is also present between the tumor capsule and the optic nerves and chiasm on the one hand and the pituitary stalk on the other. Again, surgical dissection should be performed between the tumor capsule and the arachnoid, thus leaving a layer of arachnoid over the optic nerves, chiasm, and the pituitary stalk. The reason for these anatomic relationships is that meningiomas, although histologically derived from the arachnoid villi, are in fact anatomically dural tumors because they arise from the portion of the arachnoid villus embedded within the dura mater. Thus, as they rise from their original

location in the dura as they continue to grow, meningiomas tend to displace the arachnoid ahead of them.

In contrast to the well-defined anatomic boundaries between the tumor capsule, the arachnoid, and the surrounding neurovascular structures, meningiomas show no respect for the dura mater, which they penetrate with impunity, leading to a true encasement of such intradural-intracavernous structures as the carotid artery and the cranial nerves.

PREOPERATIVE EVALUATION

The preoperative medical evaluation includes a baseline endocrine panel of pituitary and target organ hormones in addition to routine preadmission testing. On a case-by-case basis, we also obtain venous Doppler scans of the lower extremities, especially under circumstances deemed conducive to the development of deep vein thrombosis. The standard imaging study is the T1-weighted infused MRI scan in all three planes. We do not routinely obtain a cerebral angiogram. The decision to proceed with a cerebral angiogram is not really based on the need to evaluate the position of the carotid arteries, their branches, and their relationship to the tumor; this information is better obtained from the MRI scan. Rather, the cerebral angiogram is used to rule out any associated vascular abnormality, such as extracranial or intracranial carotid artery disease. Although we prefer digitized cerebral angiograms, we have obtained a magnetic resonance angiogram in some patients.

TECHNICAL NUANCES

Positioning

When positioning the patient, we rotate his or her head no more than 15 to 20 degrees toward the contralateral side because greater rotation of the head leads to a poorer visualization of the tumor tucked beneath the ipsilateral optic nerve and carotid artery. Consequently, we rely mostly on the liberal rotation of the operating room table during the operation to obtain exposure as needed.

Extradural approach

We prefer a right frontotemporopterional approach for TS and DS meningiomas. In patients whose tumors are situated

TABLE 1. Suprasellar Meningioma

Patient	Date of Surgery	Removal	Follow-up (mo)	Radiation Therapy	Recurrence
1	5/71	Partial	Lost to follow-up	—	?
2	11/80	Subtotal	186	+	—
3	5/82	Subtotal	41	+	—
4	8/82	Complete	192	—	+
5	7/83	Complete	89	—	—
6	7/83	Subtotal	200	—	+
7	4/85	Subtotal	93	—	—
8	2/87	Complete	48	—	—
9	2/87	Complete	72	—	—
10	12/87	Subtotal	186	+	—
11	1/88	Complete	138	—	+
12	10/88	Complete	137	—	—
13	9/89	Complete	48	—	—
14	5/93	Complete	12	—	—
15	6/93	Complete	81	—	—
16	6/93	Complete	72	—	—
17	2/95	Subtotal	56	—	+
18	4/96	Complete	12	—	—
19	12/98	Complete	15	—	—
20	3/99	Complete	12	—	—
21	5/00	Complete	12	—	—
22	7/00	Complete	11	—	—
23	1/01	Complete	6	—	—
24	1/01	Complete	6	—	—

mostly toward the left anterior clinoid, causing left-sided visual symptoms, the tumor is approached from the left side. However, we also prefer to have simultaneous access to the midline in these largely midline tumors (*Fig. 2*). Thus, the craniotomy is performed to the midline, unless the tumor is rather large, in which case the craniotomy is performed across the midline, thus allowing for section of the falx if necessary. Removal of the greater and lesser wings of the sphenoid with opening of the superior orbital fissure, superior orbitotomy to include the supraorbital ridge as a single bone construct, and

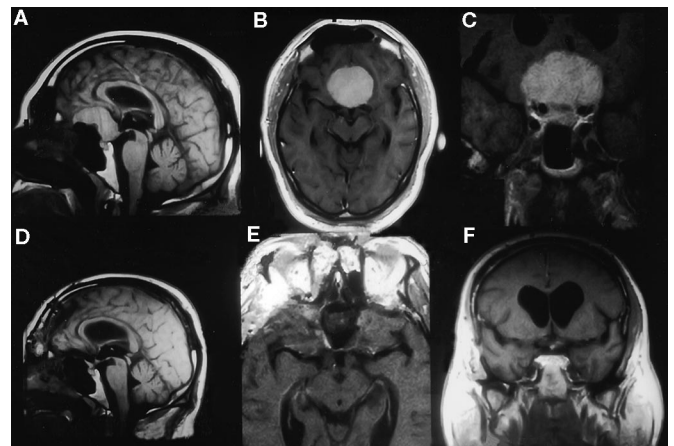


FIGURE 1. Preoperative (A–C) and postoperative (D–F) MRI scans in a 56-year-old patient with a tuberculum and diaphragma sellae meningioma. Note the posterosuperior position of the ACA complex in relationship to the tumor on the preoperative MRI scan.

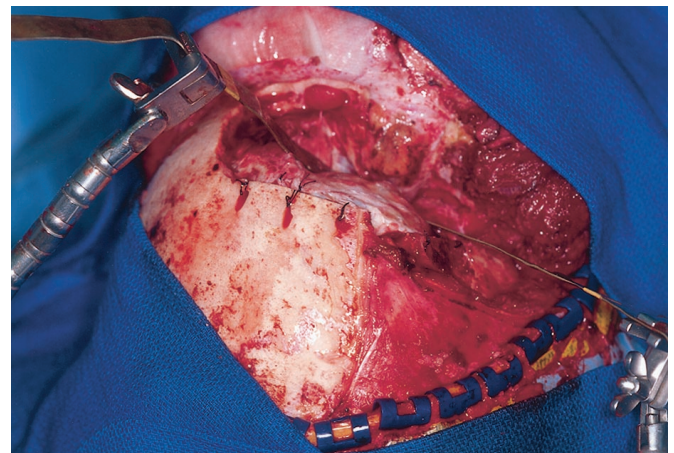


FIGURE 2. Placement of scalp and cranial flaps. Note the vascularized pericranial flap prepared to be used at the time of closure.

extradural removal of the anterior clinoid bring the surgeon as close to the tumor as possible (*Fig. 3*).

An orbitozygomatic cranial base dissection is rarely necessary, but such a procedure may provide room for additional maneuvering if needed. Removal of the anterior clinoid and division of the distal dural ring permits mobilization of the carotid artery as it emerges from the cavernous sinus, a maneuver particularly useful in patients with tumors positioned behind the ACA complex because it provides for better access to the tumor through the optic-carotid recess. A vascularized galeal flap is fashioned; this is used to seal the frontal sinuses during closure.

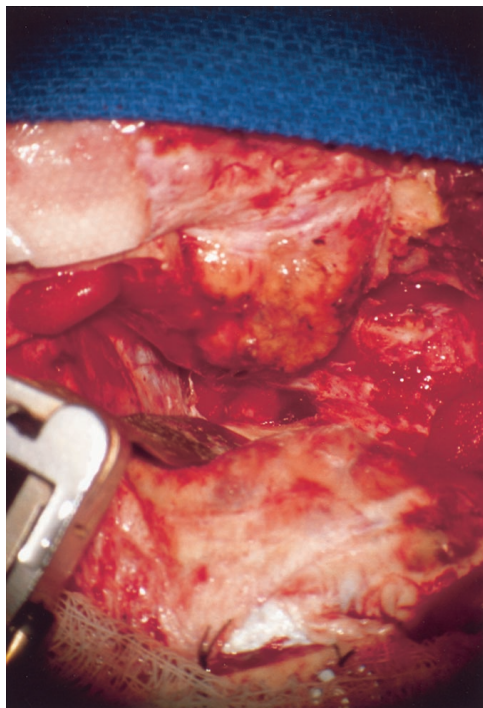


FIGURE 3. Orbitoclinoid osteotomy completed. Note the optic nerve in its dural sheath uncovered by the removal of the anterior clinoid.

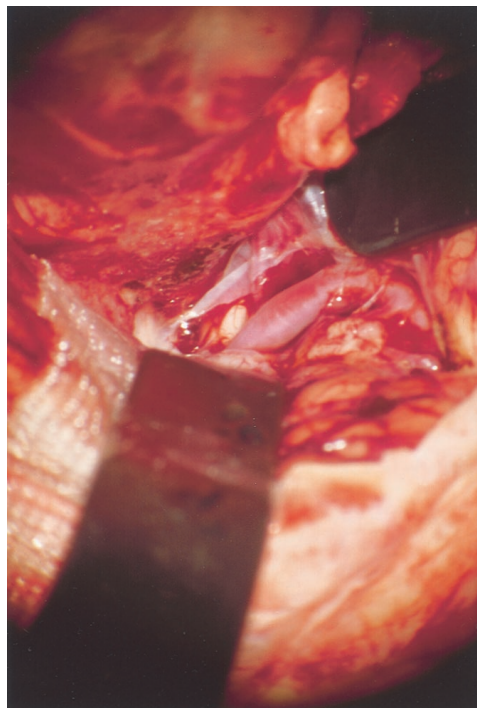


FIGURE 5. Sylvian vessels exposed.

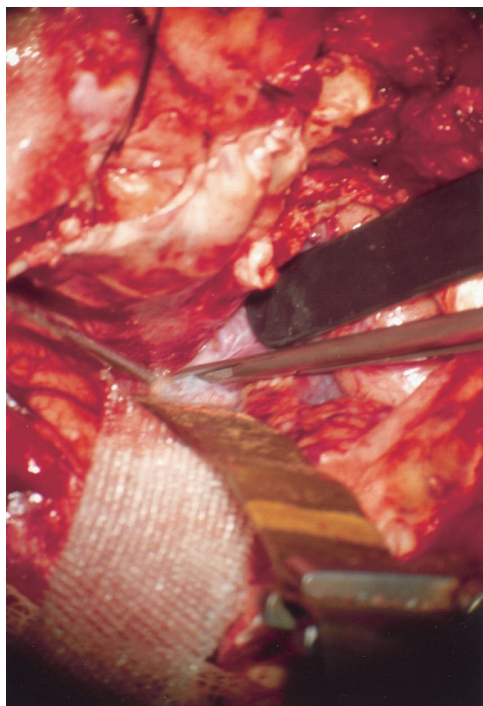


FIGURE 4. Opening of the right Sylvian fissure from distal to proximal. Arachnoid placed under slight tension by retractors.

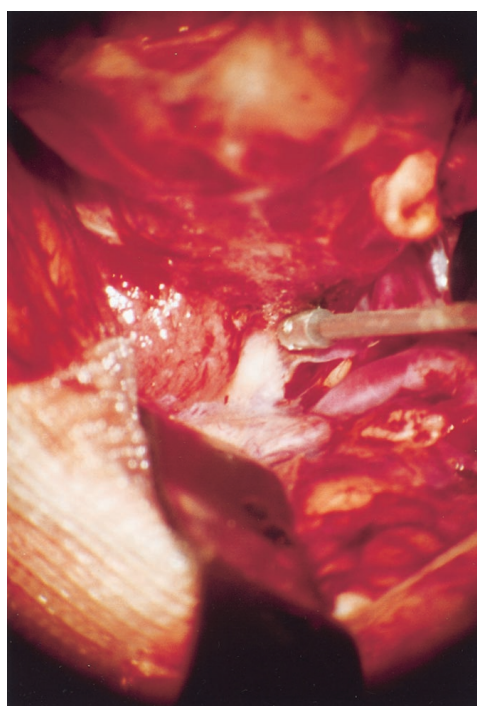


FIGURE 6. Tumor visualized as the arachnoid is opened over the right optic nerve.

In addition to the usual measures of obtaining brain relaxation before opening the dura, the cranial base exposure as described above usually yields ample room. If the dura is still under fair tension, thus precluding safe opening, temporary elevation of the patient's head will almost always result in good relaxation of the brain. A lumbar drain is not necessary and may be harmful.

Intradural operative steps

The dura mater is opened so that it drapes over the exposed periorbita. The Sylvian fissure is next opened widely from distal to proximal across the limen insulae (Fig. 4–6). The Sylvian fissure is often wider in the depth; because of this, we prefer to open it from inside out instead of proceeding first

from the surface. Placing the arachnoid of the fissure under some tension with self-retaining retractors facilitates the opening of the sylvian arachnoid. Next, we open the arachnoid across the superior surface of the optic nerve. When the optic nerve is significantly displaced and flattened out, it may be wiser to open the arachnoid along its lateral margin and then along its medial margin, proceeding further medially along the anterosuperior side of the tumor (Fig. 7). The relationship of the optic nerves and chiasm to the tumor can vary greatly. The ipsilateral optic nerve can be elevated by the tumor (and thereby kinked at the dural ring of the distal end of the optic nerve canal); the chiasm may be tilted obliquely; and the opposite optic nerve can be situated below the tumor with the tumor above it—or these relationships can be just the opposite.

After the arachnoid over the tumor is divided, the tumor is internally decompressed, preferably with an ultrasonic cavitating aspirator armed with a precision tip (Fig. 8). With some of the tumor capsule relaxation accomplished, the ipsilateral optic nerve and chiasm are freed first via sharp dissection along the tumor capsule-arachnoid interface (Fig. 9). After the ipsilateral optic nerve and chiasm are decompressed, and as more anatomic landmarks come into view (Fig. 10), we proceed with tumor capsule separation from the dural attachments along the cranial base with a nonadherent bipolar coagulating forceps (Fig. 11).

After additional internal tumor decompression posteriorly and superiorly, the superior pole of the tumor on the ipsilateral side is collapsed from underneath the arachnoid covering the right ACA. This separation starts distally and proceeds proximally along the vessel until the tumor capsule is col-

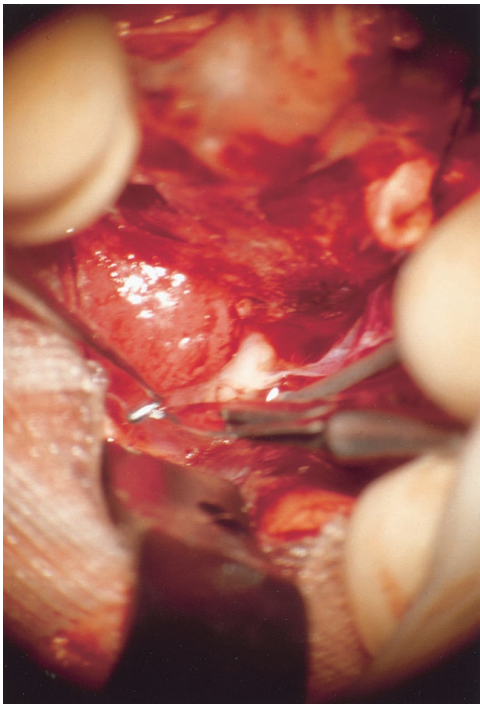


FIGURE 7. More tumor exposed as the arachnoid is opened along the medial border of the right optic nerve-chiasm junction.

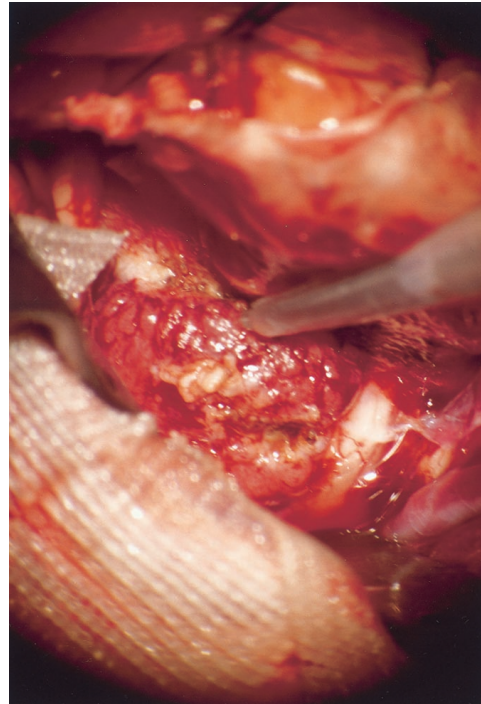


FIGURE 8. Tumor decompression using an ultrasonic cavitating aspirator.

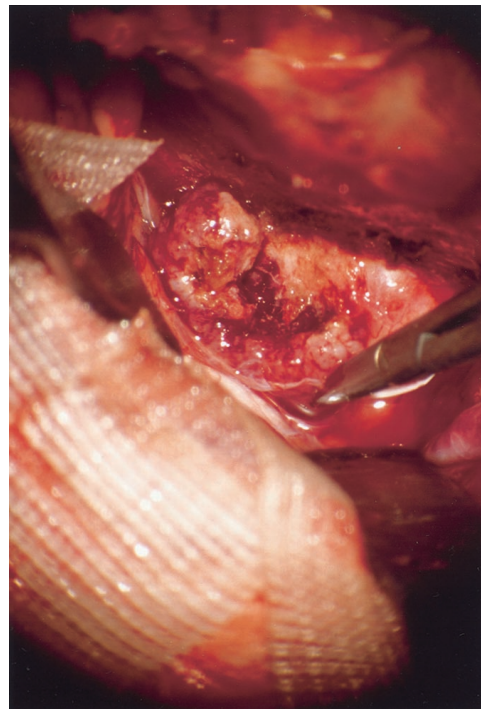


FIGURE 9. Right optic nerve and right side of chiasm freed using sharp dissection along tumor-arachnoid interface. A layer of arachnoid remains, covering the optic nerves and chiasm and the vessels.

lapsed anteromedially toward the cavitated tumor bed. The redundant tumor capsule on the ipsilateral side is then excised, bringing into view the chiasm on the ipsilateral side and giving us a glimpse of the pituitary stalk through the intact arachnoid (Fig. 12). With considerable working space achieved through the removal of the right and middle portions of the tumor, we can now continue with relative ease to

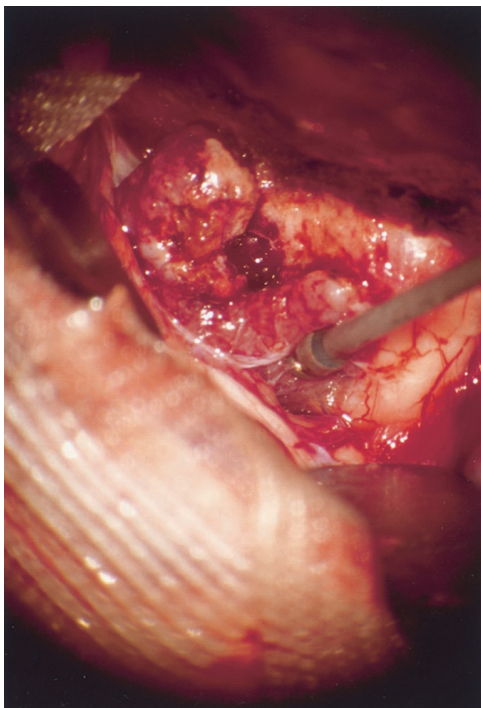


FIGURE 10. More anatomic landmarks, such as the chiasm, coming into view.

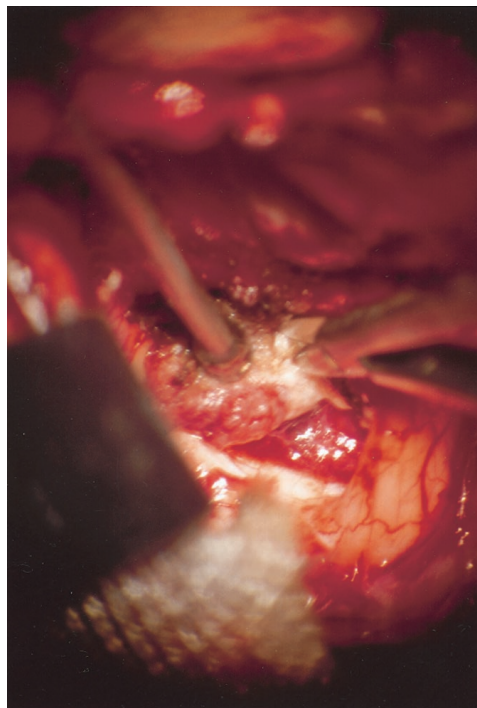


FIGURE 12. The pituitary stalk comes into view through an intact layer of arachnoid covering it.

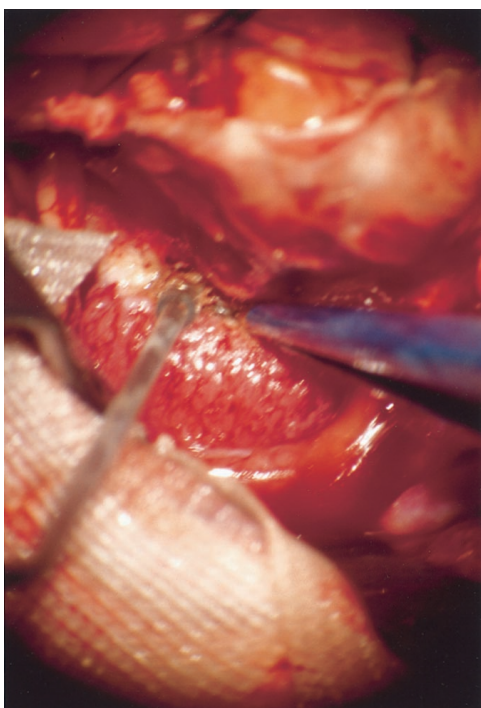


FIGURE 11. Separation of tumor attachments from the dura of the tuberculum and diaphragma sellae using bipolar coagulation with a nonad-hearing coagulating forceps.

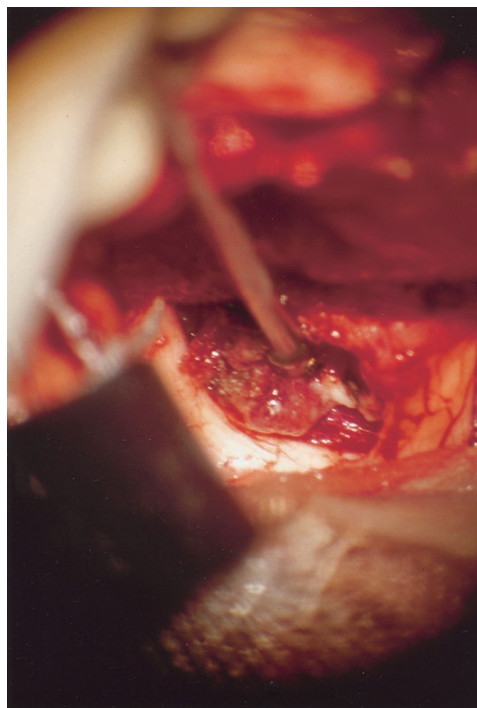


FIGURE 13. Freeing the residual tumor from the arachnoid covering the contralateral side of the chiasm and the left optic nerve.

remove the left side of the tumor. In large tumors, the left side of the tumor is cavitated before rolling the decompressed capsule away from the medial-orbital surfaces of the left frontal lobe and the arachnoid covering the left ACA. In smaller tumors, we directly proceed to free the tumor capsule from the arachnoid cover the left side of the chiasm and the left optic nerve (Figs. 13 and 14).

Resection of the DS or of the TS is not necessarily a curative maneuver and can be associated with a higher risk of developing diabetes insipidus or a cerebrospinal fluid (CSF) fistula. If there is any question that the dura and the bone of the TS were violated, an autologous fascia-fat graft should be used and anchored into position with two or three stay sutures via the microsuture technique.

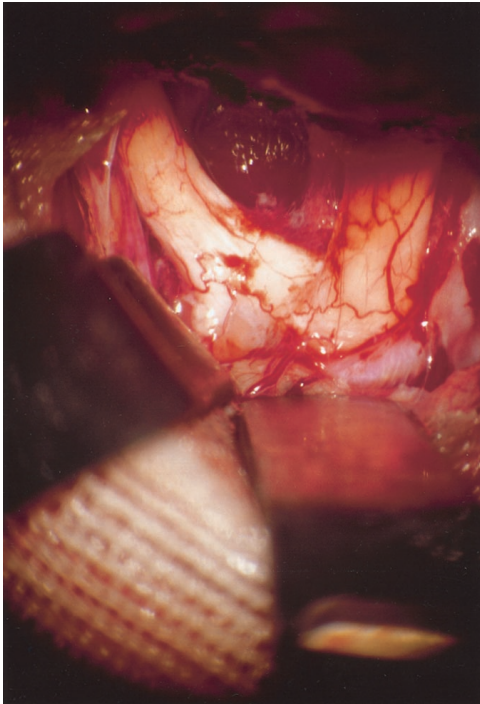


FIGURE 14. Tumor removed. Note that all neurovascular structures, including the ACA complex, the optic nerves, and chiasm, remain covered by a glistening layer of intact arachnoid.

Closure

The closure proceeds in the standard fashion, including reconstructing the orbital rim and roof and sealing off the denuded frontal sinuses with a fat graft and the galeal flap, which is sutured into the underlying dura via the surface-to-surface suture technique.

RESULTS

The patients who received the operation we describe comprised 18 women and 6 men. The mean age was 40 years (range, 25–68 yr). The mean follow-up period was 76 months (range, 12–200 mo). The completeness of tumor removal was evaluated before 1987 with an infused computed tomographic scan; after 1987, we evaluated completeness of tumor removal with an infused T1-weighted MRI scan. There were 16 complete removals, 7 subtotal removals, and 1 partial removal. There were four recurrences (16%). Two of the recurrences occurred in patients in whom the postoperative imaging studies showed no evidence of residual tumor tissue. Postoperative radiation therapy was administered in three patients with subtotal tumor removal. None of these patients developed a recurrence. No patient died. Six patients lost their sense of smell.

One patient (Patient 10) experienced a greater degree of visual loss, with near blindness in one eye and a partial temporal anopic defect in the other. In contrast, visual improvement was observed in several patients within a matter of days after the operation. One patient (Patient 3), who had a traumatic amaurosis in one eye and a progressive visual loss in the other secondary to a tuberculoma-clinoid meningioma and whose remaining vision failed to improve after subtotal removal of a tumor due to residual meningioma infiltrating the optic nerve sheath, went on to develop a near-complete recovery of vision in that

eye after radiation therapy. A postoperative paresis of the frontalis branch of the facial nerve was observed in two patients. No other cranial nerve deficits were noted in this series. There were no instances of CSF leaks or meningitis. Two patients developed fairly significant subgaleal CSF effusions, requiring subsequent aspirations, lumbar spinal drainage, or both.

One patient (Patient 21), who presented with a 3-cm DS meningioma and who underwent complete tumor removal, developed temporary confusion after the operation, although recovery was complete. A retraction against the fronto-orbital surface of the right frontal lobe was deemed responsible for this complication. Patient 21 also developed bilateral deep vein thrombosis with pulmonary emboli, which was treated initially with placement of a vena cava filter. The patient completely recovered after receiving therapy with anticoagulants. Although a temporary increase in diuresis occurred in several patients, true diabetes insipidus did not occur in any of these patients on a permanent basis.

In patients with complete tumor removal, the pituitary stalk was always visualized behind a veil of arachnoid, as discussed above. When we decided on a strategy of subtotal tumor removal during the operation, we did so to avoid injuring the pituitary stalk in patients whose tumors straddled (rather than displaced), and in some instances engulfed, the pituitary stalk.

CONCLUSION

Most suprasellar meningiomas can be removed completely and safely. One of the important anatomic concepts in this regard is that although meningiomas are histologically arachnoid-derived tumors, they are anatomically dura-based, and consequently, they displace the arachnoid as they grow. Thus, an arachnoid barrier exists between the tumor and the surrounding neurovascular structures. Preservation of this arachnoid barrier will safeguard the neurovascular structures during the tumor removal.

The principal surgical concepts and steps we used are as follows: 1) we approached the tumor by dissecting the cranial base; 2) we opened the sylvian fissure with release of CSF to minimize—if not obviate—the necessity for retraction; 3) we dissected the arachnoid through the arachnoid corridors of the limen insulae, the optic-carotid cistern, and the suprasellar cistern; 4) we performed initial internal tumor decompression; 5) as the internal tumor decompression progressed, we gradually lifted the tumor base off the dura of the TS and the DS as we interrupted the tumor's blood supply; and 6) we separated the slackened tumor capsule from the arachnoid covering the neurovascular structures.

When complete tumor removal is not deemed advisable for whatever reason (e.g., patient age, tumor size, and technical difficulties), the strategy of a subtotal tumor removal followed by radiation therapy can be used with what seems to be satisfactory long-term outcomes.

Received, January 25, 2001.

Accepted, July 5, 2001.

Reprint requests: Ivan Ciric, M.D., Division of Neurosurgery, Evanston Hospital, Northwestern University Medical School, 2650 Ridge Avenue, Evanston, IL 60201. Email: iciric@enh.org