

Ivan Ciric, M.D.

Department of Neurological Surgery, Feinberg School of Medicine, Northwestern University, and Evanston Northwestern Healthcare, Evanston, Illinois

Jin-cheng Zhao, M.D.

Department of Neurological Surgery, Feinberg School of Medicine, Northwestern University, and Evanston Northwestern Healthcare, Evanston, Illinois

Sami Rosenblatt, M.D.

Department of Neurological Surgery, Feinberg School of Medicine, Northwestern University, and Evanston Northwestern Healthcare, Evanston, Illinois

Richard Wiet, M.D.

Department of Otolaryngology, Feinberg School of Medicine, Northwestern University, and Evanston Northwestern Healthcare, Evanston, Illinois

Brian O'Shaughnessy, M.D.

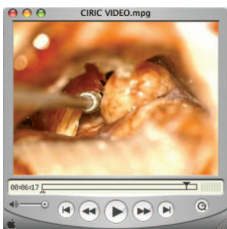Department of Neurological Surgery, Feinberg School of Medicine, Northwestern University, and Evanston Northwestern Healthcare, Evanston, Illinois

Reprint requests:

Ivan S. Ciric, M.D.,
Division of Neurosurgery, Evanston Hospital, 2650 Ridge Avenue,
Evanston, IL 60201.
Email: iciric@enh.org

Received, August 11, 2004.

Accepted, December 10, 2004.



SUBOCCIPITAL RETROSIGMOID APPROACH FOR REMOVAL OF VESTIBULAR SCHWANNOMAS: FACIAL NERVE FUNCTION AND HEARING PRESERVATION

IN THIS REPORT, we discuss the pertinent bony, arachnoid, and neurovascular anatomy of vestibular schwannomas that has an impact on the surgical technique for removal of these tumors, with the goal of facial nerve and hearing preservation. The surgical technique is described in detail starting with anesthesia, positioning, and neurophysiological monitoring and continuing with the exposure, technical nuances of tumor removal, hemostasis, and closure. Positive prognostic factors for hearing preservation are also highlighted.

KEY WORDS: Cochlear nerve, Facial nerve, Surgical anatomy

Neurosurgery 56:560-570, 2005

DOI: 10.1227/01.NEU.0000154059.34990.B8

www.neurosurgery-online.com

With the advent of radiosurgery techniques in the treatment of vestibular schwannomas, the bar was raised on the expectations of the surgical outcomes in these patients. Although recent reports on radiosurgical treatment of vestibular schwannomas have demonstrated excellent results in tumor control (12), surgical cure remains a viable treatment option. A number of reports have been published in the neurosurgery literature in the past 2 decades on hearing preservation in patients with vestibular schwannomas undergoing surgical resection of their tumors (1–11, 13–17, 19). In this report, we describe the technical nuances that we found useful and conducive to facial nerve and, especially, hearing function preservation during retrosigmoid microsurgical removal of vestibular schwannomas.

posure, the asterion should always be identified as the point where the transverse sinus merges into the sigmoid sinus. The digastric groove should also be identified as being just posterior to the stylomastoid foramen and the facial nerve. The position of the mastoid emissary, however, is variable. The posterior semicircular canal is closest to the fundus of the internal auditory canal (IAC) and is situated some 8 to 10 mm lateral to the posterior rim of the IAC meatus. The endolymphatic duct that arises from the common crus of the semicircular canals is situated as a *cul-de-sac* in the bony vestibular aqueduct just medial and inferior to the posterior rim of the IAC meatus, where it is covered by the petrous dura. The appearance of the falciform crest while drilling the posterior wall of the IAC denotes that the surgeon has reached the fundus of the IAC.

SURGICAL ANATOMY NUANCES

There are several surgical anatomy concepts that are constant and promote facial nerve function and hearing preservation.

Bony Anatomy

A preoperative computed tomographic scan can identify the extent of mastoid and adjacent bone pneumatization. During the ex-

Arachnoid Anatomy

Yaşargil et al. (18) have demonstrated that vestibular schwannomas originate outside the arachnoid, which invaginates into the IAC. Thus, as they grow toward the meatus and further into the cerebellopontine angle (CPA), vestibular schwannomas displace the arachnoid into the CPA and remain covered by a layer of arachnoid regardless of their size. This layer is referred to as the second layer of arachnoid as opposed to the first, parietal

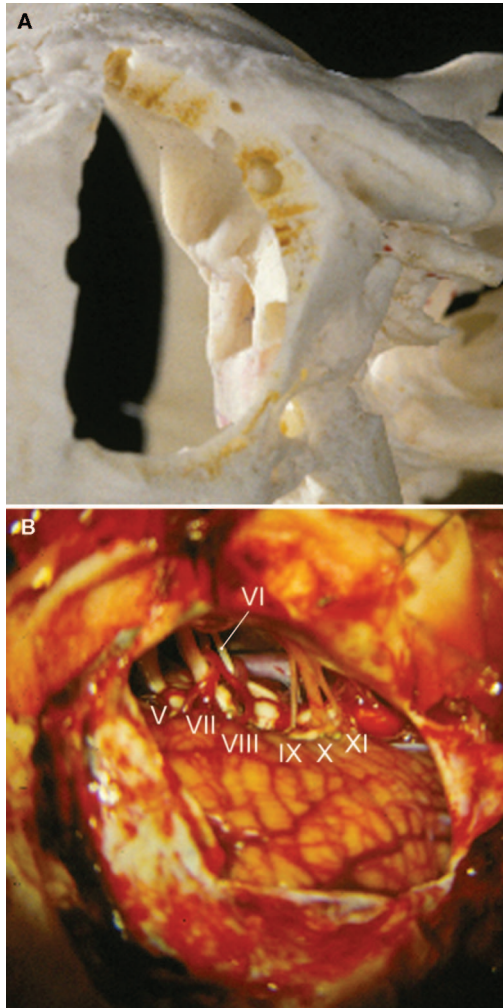


FIGURE 1. Intraoperative photographs showing surgeon's view of the right CPA. Cranial Nerves V through XI are shown. Note the basilar artery in the depth of the exposure.

arachnoid that is aligned with the dura of the posterior fossa. In large vestibular schwannomas, these two layers can be juxtapositioned to a point where they approximate each other.

Neurovascular Anatomy

Figure 1 reveals the anatomy of the right CPA as viewed by the surgeon through a suboccipital craniotomy with the patient positioned supine and the head turned to the opposite side. Figure 2 is a magnified view of the inferior and superior compartments of the CPA. The position of the cochlear and facial nerves is constant at the brainstem and at the meatus. The root entry zone of the cochlear nerve at the pontomedullary junction is always lateral to the root exit zone of the facial nerve. The intraoperative landmarks in this regard are the flocculus and the choroid plexus in the foramen of Luschka. The cochlear and facial nerves are approximately 2 to 3 mm ventral and rostral to these structures. In the meatus, the cochlear nerve is situated anteroinferiorly and the facial nerve is situated anterosuperiorly, with the vestibular nerves occupying a posterior position.

In patients with a vestibular schwannoma, the cochlear nerve is splayed along the inferior surface of the tumor (Fig. 3). The facial nerve, conversely, can have a variable course between the brainstem and the meatus, although in light of its initial anatomic location, it is usually situated anterior to a vestibular schwannoma. Not infrequently, the facial nerve can be positioned between the tumor and the brainstem, where it runs in a rostral direction, at times reaching the axilla of the trigeminal nerve root before curving back on itself to enter the IAC.

The anteroinferior cerebellar artery is usually anteroinferior to the tumor. The internal auditory artery, a branch of the anteroinferior cerebellar artery, is positioned along the inferior surface of the cochlear nerve in most individuals, sending off a leash of arterial twigs into the nerve between the brainstem and the meatus. The posteroinferior cerebellar artery, or one of its branches, can be found along the posterior tumor surface, at times meandering through the dura and sometimes even through the petrous bone.

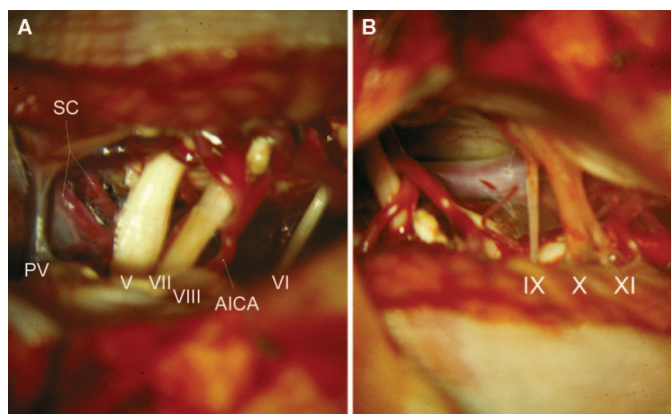


FIGURE 2. A and B, intraoperative photographs showing magnified views of the right CPA: upper compartment (A) and lower compartment (B).

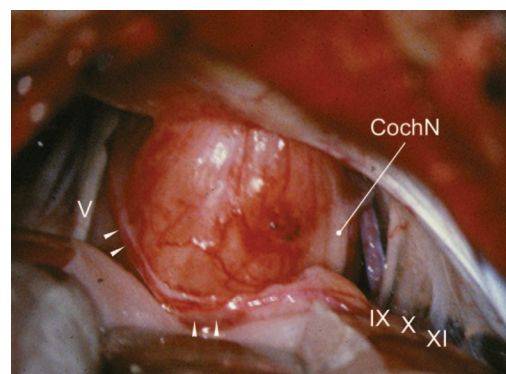


FIGURE 3. Intraoperative photograph showing 1.5-cm right vestibular schwannoma. Note the cochlear nerve (Coch N) along the inferior tumor surface.

SURGICAL TECHNIQUE

(see video at web site)

Anesthesia, Neurophysiological Monitoring, and Positioning

Balanced general anesthesia that permits intraoperative electrophysiological monitoring is a prerequisite for a safe operative procedure. Brainstem auditory evoked potential recordings (BAERs) from both ears and ipsilateral facial nerve electromyographic recordings are carried out in every patient, with the neurologist and/or neurophysiologist in attendance from dura opening to dura closure (Fig. 4). Earlier on, in our series, we stimulated the facial nerve using a bipolar stimulation technique. Presently, we prefer a monopolar stimulation technique. Preferably, the facial nerve should be stimulated at its point of exit from the brainstem. The electromyographic electrodes remain live throughout the procedure so that any train of undesired electrical activity during the critical part of the dissection of the tumor capsule from the facial nerve, especially around the meatus, can be detected and the surgical strategy thus adjusted.

The patient is positioned supine with the ipsilateral shoulder and hip slightly elevated on foam rubber pads (especially useful

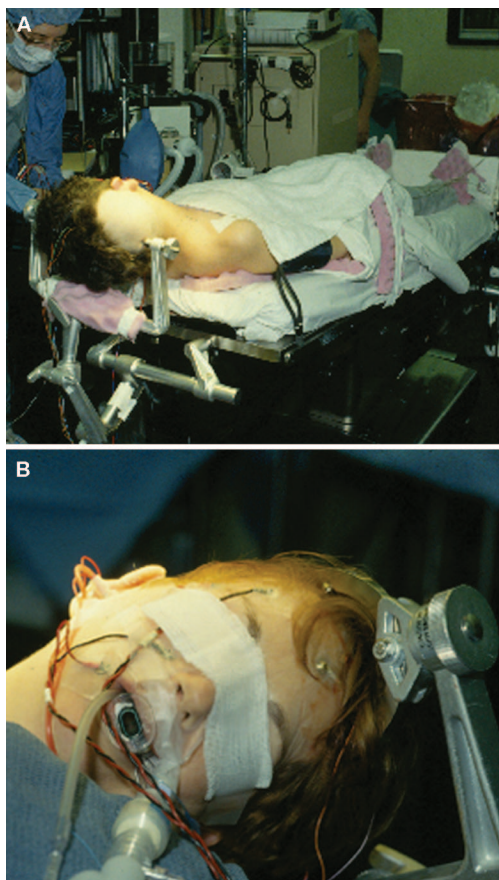


FIGURE 4. Photographs showing patient position (A) and monitoring electrodes (B).

for elderly patients), so as to allow for easy and unrestricted turning of the head to the opposite side (Fig. 4). We prefer to have the ipsilateral temporal squama level and parallel to the operating room floor, with the head slightly flexed toward the sternum. Care must be taken, however, not to occlude the jugular venous outflow, especially on the ipsilateral side. The head is secured to the operating table with a three-point fixation clamp. All exposed peripheral nerves are well padded so as to prevent pressure neuropathy. The ipsilateral upper or lower quadrant of the abdomen is exposed so that a subcutaneous fat graft can be harvested for use during closure of the cranial incision. Lateral leg supports (“sleds”) are placed to support the legs during side-ways tilting of the operating table, which is used liberally during surgery. The cranial and abdominal sites are prepared and draped in the standard fashion. We do not use intracranial navigation for removal of vestibular schwannomas unless the tumor is very large, or a combined supra-infratentorial approach is planned, when it can be of value in determining the position of the brainstem relative to the far side of the tumor capsule. Insertion of a lumbar drain is not necessary during vestibular schwannoma surgery.

Exposure

A vertical incision is made immediately posterior to the vertical hairline and from above the asterion to below the mastoid tip level. In patients with thicker scalps, a slightly longer incision is necessary. The suboccipital muscles are dissected away from the suboccipital squama as low

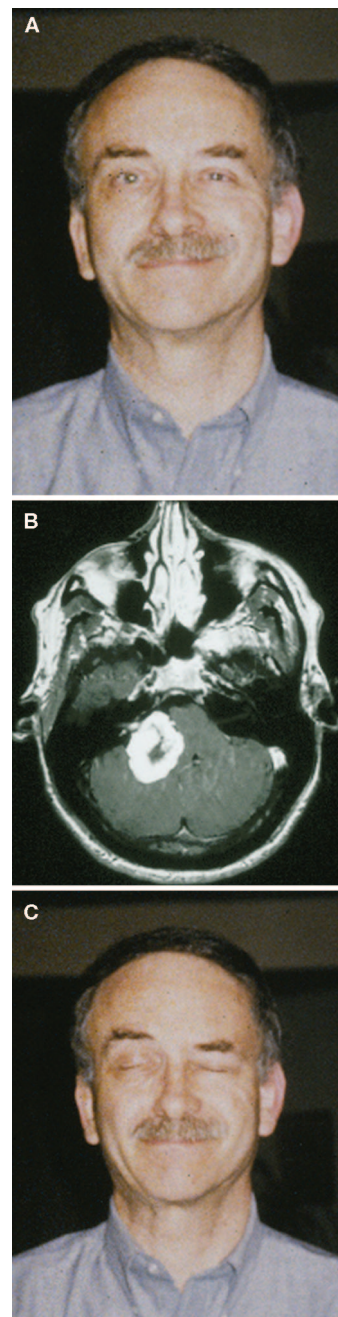


FIGURE 5. Postoperative photographs of a patient (A and C) and preoperative magnetic resonance image (B) of the same patient showing the result of an end-to-end anastomosis of a transected facial nerve performed in situ.

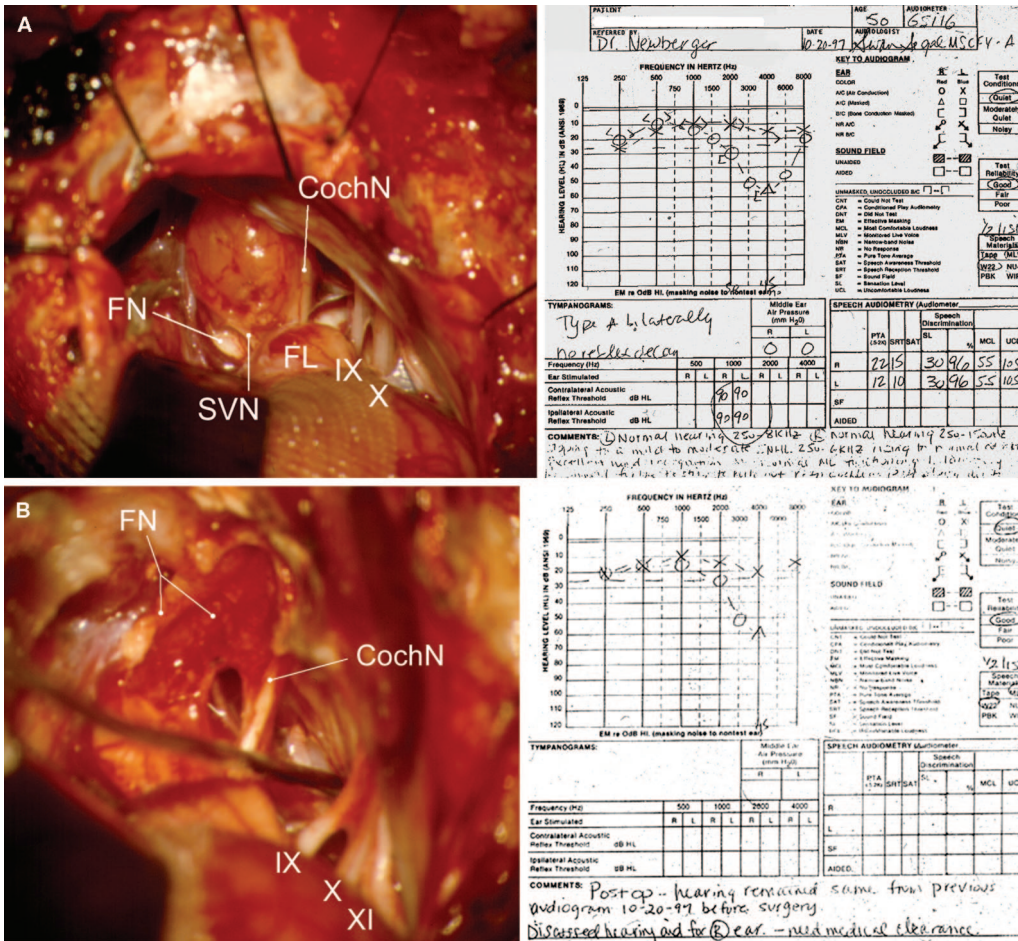


FIGURE 6. A, intraoperative photograph showing a 1.25-cm right vestibular schwannoma nestled between the cochlear nerve (Coch N) and superior vestibular nerve (SVN). The facial nerve (FN) root entry zone is apparent behind the tumor. FL, flocculus. Note that the speech discrimination score is 96% for both ears in the preoperative audiogram. B, intraoperative photograph showing operative site after tumor removal. Note that the posterior wall of the IAC was removed. The cochlear nerve and facial nerve are splayed and still covered by a layer of glistening arachnoid. The composite of the cochlear nerve and facial nerve resembles a chalice. The postoperative audiogram shows the hearing to be the same as before surgery.

as the cranial base. Bleeding from emissary veins is stopped with bone wax. Care should be exercised not to injure the facial nerve as it exits the cranium anterior to the digastric groove by using dissecting instruments or monopolar coagulation. Thus, the "bovie" knife should be used sparingly in the vicinity of the facial nerve. The periosteum should be cleared sufficiently anteriorly over the mastoid itself, with care taken not to penetrate the posterior wall of the external ear canal.

A standard suboccipital craniotomy is performed. We prefer to place the burr holes with a high-speed drill armed with a conically shaped drill. The use of standard perforating drills can prove dangerous, inasmuch as they can cause cerebellar contusions. Such injuries must be stringently avoided. The craniotomy is then enlarged using the same drill. The craniotomy should be as high as the lateral sinus and as anterior as the entire sigmoid sinus (with the junction between the two exposed underneath

the asterion) down to the jugular bulb. Such an exposure usually requires a partial mastoidectomy, during which the mastoid air cells may be opened widely. They should be thoroughly sealed off with bone wax. Emissary veins joining the sigmoid sinus can prove to be a temporary obstacle because of the potential for fairly vigorous bleeding if injured. The emissary veins should thus be skeletonized using the same drill until they are free of their bony encasement; at that point, they can be coagulated. Finally, exposure should be as low as the posterior fossa floor. Up to this point, the operation is usually performed using vision magnification with magnifying loupes. From this point on, however, it is necessary to continue the operation under the operating microscope so as to allow not only for magnification and strict coaxial illumination but, most importantly, for three-dimensional visualization of the CPA, the tumor, and the surrounding neurovascular structures.

Opening the Dura

It has been our practice for the surgeon and the assistant to change gloves and to irrigate the operative field with a topical antibiotic solution before opening the dura, lest there be some contamination of the operative field during the exposure of the mastoid air cells. More likely than not, with the patient in the supine position, the dura of the posterior fossa is under tension when initially exposed. Lowering the pCO₂ down to approximately 28 to 30 mm Hg (by arterial blood gases) and placing the operating table temporarily in a Fowler (head-up) position (by some 30 degrees) should suffice to promote relaxation of the posterior fossa dura and a safe opening of the dura. The anesthesiologist should be aware of this change in the patient's position and should notify the surgeon of any developing hypotension. Although we did occasionally observe a temporary but not significant decrease in blood pressure, we have not had a single instance of a pulmonary embolism.

The dura is first opened along the cranial base, and the small triangular flap based inferiorly is secured to the cervical muscles.

The cerebellum is then gently elevated over a coated handheld retractor until the cerebellomedullary cistern is detected and opened sharply. This critical maneuver results in the copious escape of cerebrospinal fluid and, invariably, a nice relaxation of the cerebellum, which now recedes away from the posterior surface of the petrous bone. With the cerebellum relaxed, the dura is opened further, and the lateral dura leaf, together with the sigmoid sinus, is reflected out of the operative field and held retracted with stay sutures. From this point on, the self-retaining cerebellar retractor is used only as a protector during certain surgical maneuvers with little, if any, need for cerebellar retraction. We are reluctant to use standard issue cotton pledgets over the cerebellum because they are prone to abrade the cerebellar folia. Instead, we prefer to cover the cerebellum with strips made of lubricant-impregnated Adaptic dressing (Johnson & Johnson Medical, Arlington, TX). Similarly, to prevent injury during the surgical dissection of the tumor capsule from the surrounding neurovascular structures, we keep the established surgical cleavage planes open with moist Telfa pledgets (Kendall Health Care Products, Mansfield, MA).

Technique of Tumor Removal

With the cerebellum receded from the posterior surface of the petrous bone and the schwannoma identified, the operative field should be inspected while the tumor is still covered by its arachnoid investments. Inspection may reveal a branch of the posteroinferior cerebellar artery over the posterior tumor surface. Such an arterial vessel may be observed insinuating itself in a loop-like fashion into the IAC, where it may, in fact, penetrate through the dura or even the petrous bone. An attempt to extract this artery from the IAC without visualizing the entire vessel loop can thus be associated with disastrous consequences. After both layers of arach-

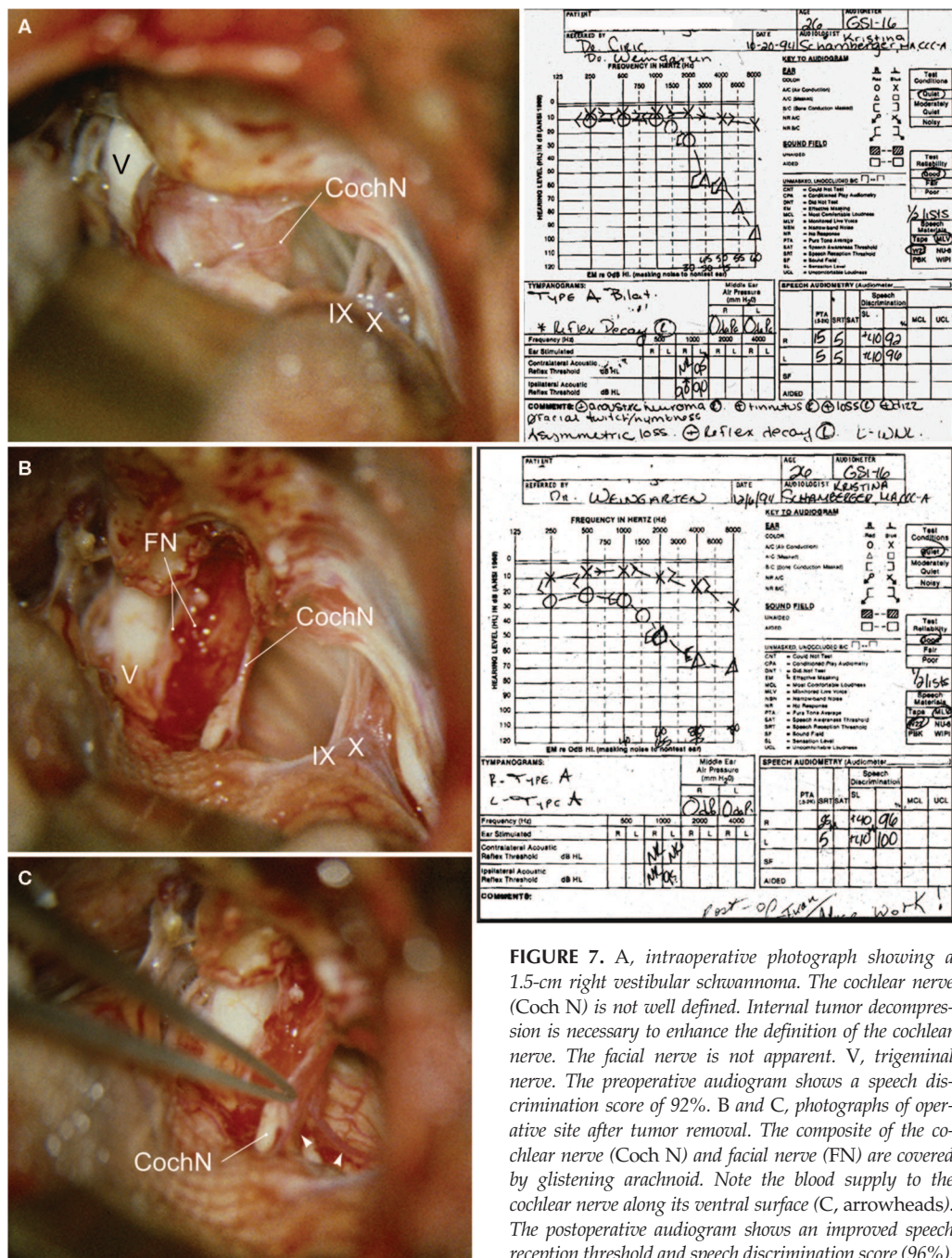
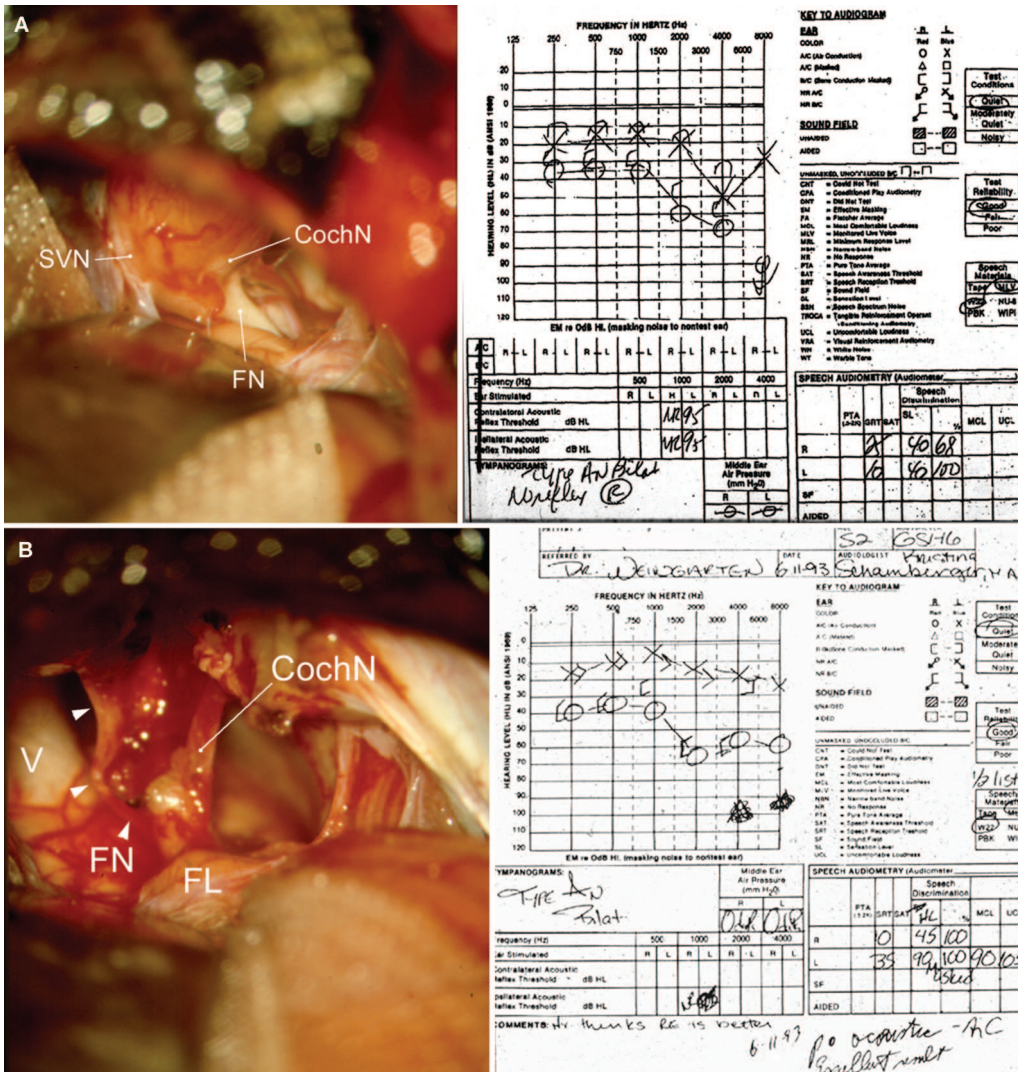


FIGURE 7. A, intraoperative photograph showing a 1.5-cm right vestibular schwannoma. The cochlear nerve (Coch N) is not well defined. Internal tumor decompression is necessary to enhance the definition of the cochlear nerve. The facial nerve is not apparent. V, trigeminal nerve. The preoperative audiogram shows a speech discrimination score of 92%. B and C, photographs of operative site after tumor removal. The composite of the cochlear nerve (Coch N) and facial nerve (FN) are covered by glistening arachnoid. Note the blood supply to the cochlear nerve along its ventral surface (C, arrowheads). The postoperative audiogram shows an improved speech reception threshold and speech discrimination score (96%).

noid are opened using sharp dissection, the arterial vessel should first be skeletonized by drilling away the surrounding petrous bone using a 2- to 3-mm diamond drill and a continuous irrigation-suction technique. The freed vessel can then be extracted from the IAC under direct vision along with a cuff of dura around it before it is reflected out of harm's way (see video at web site). Once this has been accomplished, the arachnoid layers over the dorsal surface of the tumor can be stripped away using sharp or blunt dissection. If



the dorsal surface of the tumor is free of vessels and stimulation also reveals no evidence of any facial nerve fibers, the surgeon can then proceed to the next step in the operation.

There is some difference of opinion as to whether a vestibular schwannoma should first be decompressed internally or whether the IAC should be opened first so as to identify the cochlear and facial nerves in the canal. Our position in this regard is to decompress a larger tumor (>1.5–2 cm) first so as to be able to identify the cochlear nerve, which invariably drapes the inferior surface of the tumor, as well as to be able to identify the facial

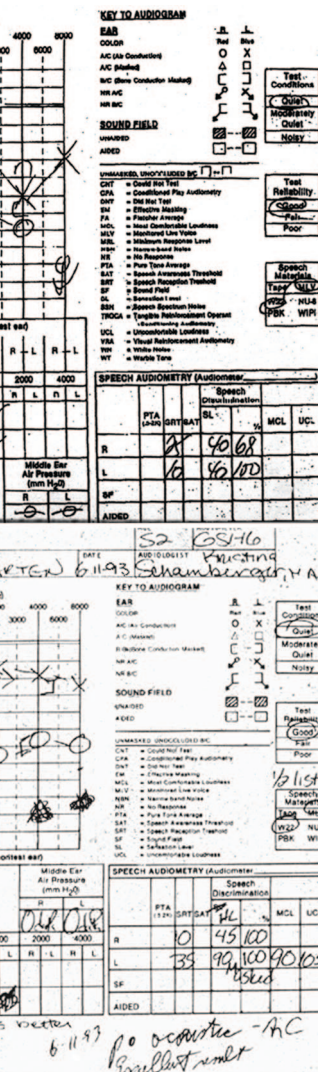nerve at the brainstem. The cochlear nerve can be significantly attenuated in patients with large tumors and may be barely recognizable even under the operating microscope. As the tumor is decompressed, the identity of the cochlear nerve becomes progressively clearer to a point at which a spontaneous cleavage plane begins to develop between the cochlear nerve and the tumor capsule, which can then be further developed using microsurgical dissecting techniques. With a larger tumor adequately decompressed, the IAC is then opened and the cochlear and facial nerves are identified in the canal.

After the dura is stripped off, the posterior wall of the IAC is drilled away, initially using a coarse 3-mm diamond burr and, as the surgeon approaches the dura of the canal, a fine-surface 3-mm and then 2-mm diamond burr. The removal of the posterior canal wall is carried out as far into the canal as the lateral extent of the tumor, as determined by the preoperative magnetic resonance imaging scans or until the horizontally placed falci-form crest is apparent at the fundus of the IAC. It is advisable not to remove more than 8 to 9 mm of the posterior canal wall lest the surgeon opens the posterior semicircular canal or the endolymphatic duct by stripping the dura that covers the vestibular aqueduct, both of which can result in a loss of hearing.

It is necessary to accomplish excellent internal decompression in larger tumors before commencing with the dissection of the tumor capsule from the surrounding neurovascular structures. More often than not, it is preferable to alternate internal decompression with extracapsular dissection of the ever more relaxed

nerve at the brainstem. The cochlear nerve can be significantly attenuated in patients with large tumors and may be barely recognizable even under the operating microscope. As the tumor is decompressed, the identity of the cochlear nerve becomes progressively clearer to a point at which a spontaneous cleavage plane begins to develop between the cochlear nerve and the tumor capsule, which can then be further developed using microsurgical dissecting techniques. With a larger tumor adequately decompressed, the IAC is then opened and the cochlear and facial nerves are identified in the canal.

After the dura is stripped off, the posterior wall of the IAC is drilled away, initially using a coarse 3-mm diamond burr and, as the surgeon approaches the dura of the canal, a fine-surface 3-mm and then 2-mm diamond burr. The removal of the posterior canal wall is carried out as far into the canal as the lateral extent of the tumor, as determined by the preoperative magnetic resonance imaging scans or until the horizontally placed falci-form crest is apparent at the fundus of the IAC. It is advisable not to remove more than 8 to 9 mm of the posterior canal wall lest the surgeon opens the posterior semicircular canal or the endolymphatic duct by stripping the dura that covers the vestibular aqueduct, both of which can result in a loss of hearing.



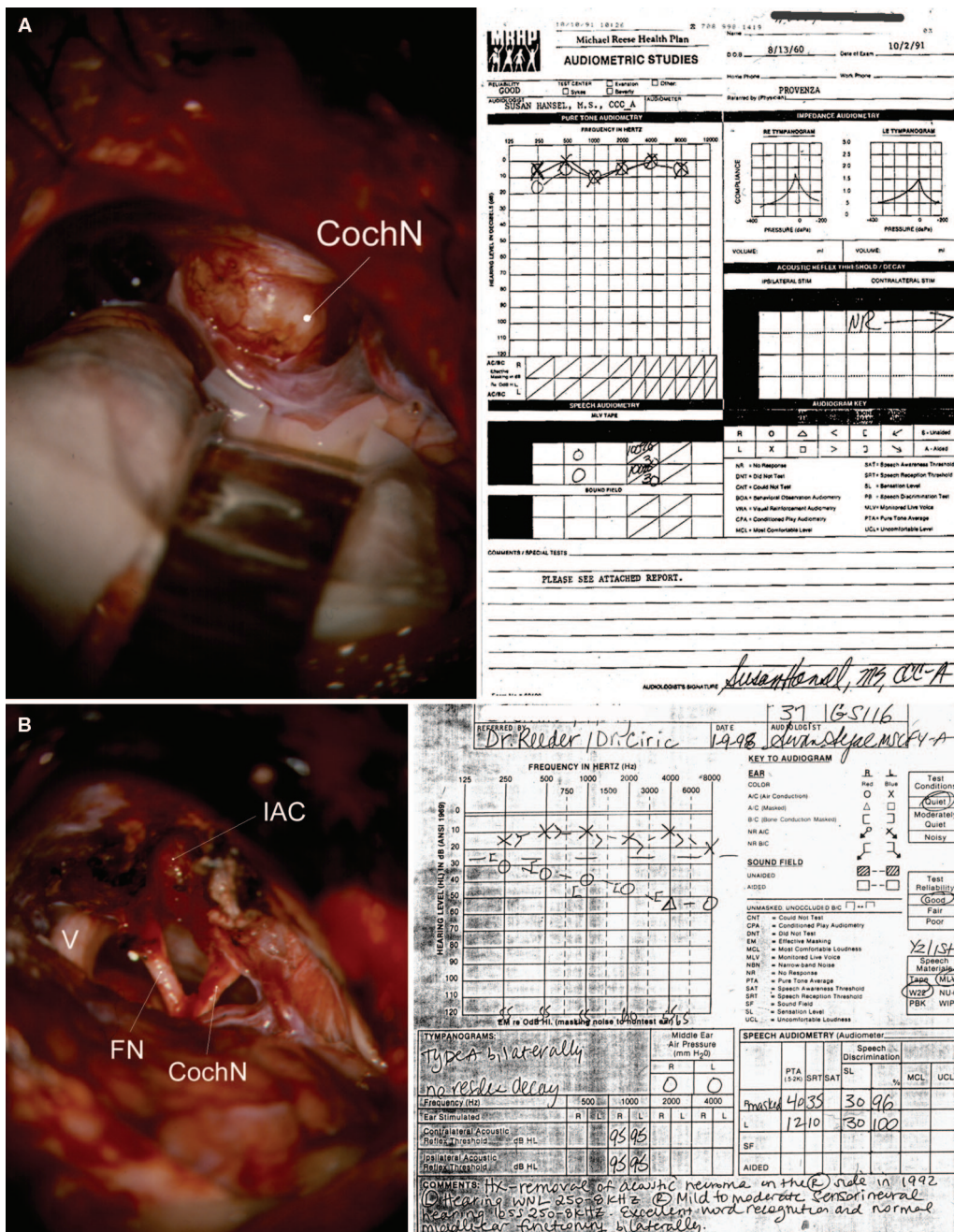


FIGURE 9. A, intraoperative photograph showing a 1.75-cm right vestibular schwannoma. The preoperative audiogram (1991) shows normal hearing, with a speech discrimination score of 100%. Coch N, cochlear nerve. B, photograph of operative site after tumor removal. Coch N, cochlear nerve; FN, facial nerve; IAC, internal auditory canal; V, trigeminal nerve. Note that the audiogram 7 years later (1998) shows near-normal hearing, with a speech discrimination score of 96%.

and slackened tumor capsule away from the cranial nerves and surrounding vessels. The extracapsular dissection of the tumor capsule from the surrounding cranial nerves and vessels should proceed along the tumor capsule-arachnoid interface and never along the interface between the arachnoid and the neurovascular

structures (brainstem, cranial nerves, and vessels). Considering that the growth of vestibular schwannomas commences outside the subarachnoid space in the IAC, they remain covered by a layer of arachnoid no matter how attenuated it may be. The better the tumor is decompressed internally, the more obvious becomes the surgical dissection plane between the arachnoid covering the neurovascular structures on one side and the tumor capsule on the other.

The extracapsular dissection proceeds in an orderly fashion, beginning with the separation of the tumor capsule from the cochlear and facial nerves at the brainstem and continuing in the direction of the porus. All along, the leash of perforator vessels from the internal auditory artery that provide the blood supply of the cochlear nerve must be meticulously preserved. The anatomic constellation whereby this blood supply reaches the cochlear nerve from its ventral side is favorable to hearing preservation. In contrast, when the internal auditory artery or one of its branches meanders through the tumor capsule, preservation of the blood supply, and thus of hearing, can prove difficult to impossible. Any change in the BAER recordings should alert the surgeon to alter his strategy in freeing the cochlear nerve from the tumor capsule. In smaller tumors and adequately decompressed larger tumors, the anatomic preservation of the cochlear nerve usually proceeds rather straightforwardly even if the cochlear nerve is attenuated.

We think that it is advisable to attempt to preserve the cochlear nerve anatomically in every patient, even if the BAER recordings deteriorate during surgery with only Wave 1 remaining. In the process of freeing the tumor capsule from the cochlear and facial nerves, the surgeon should painstakingly search for the thin layer of

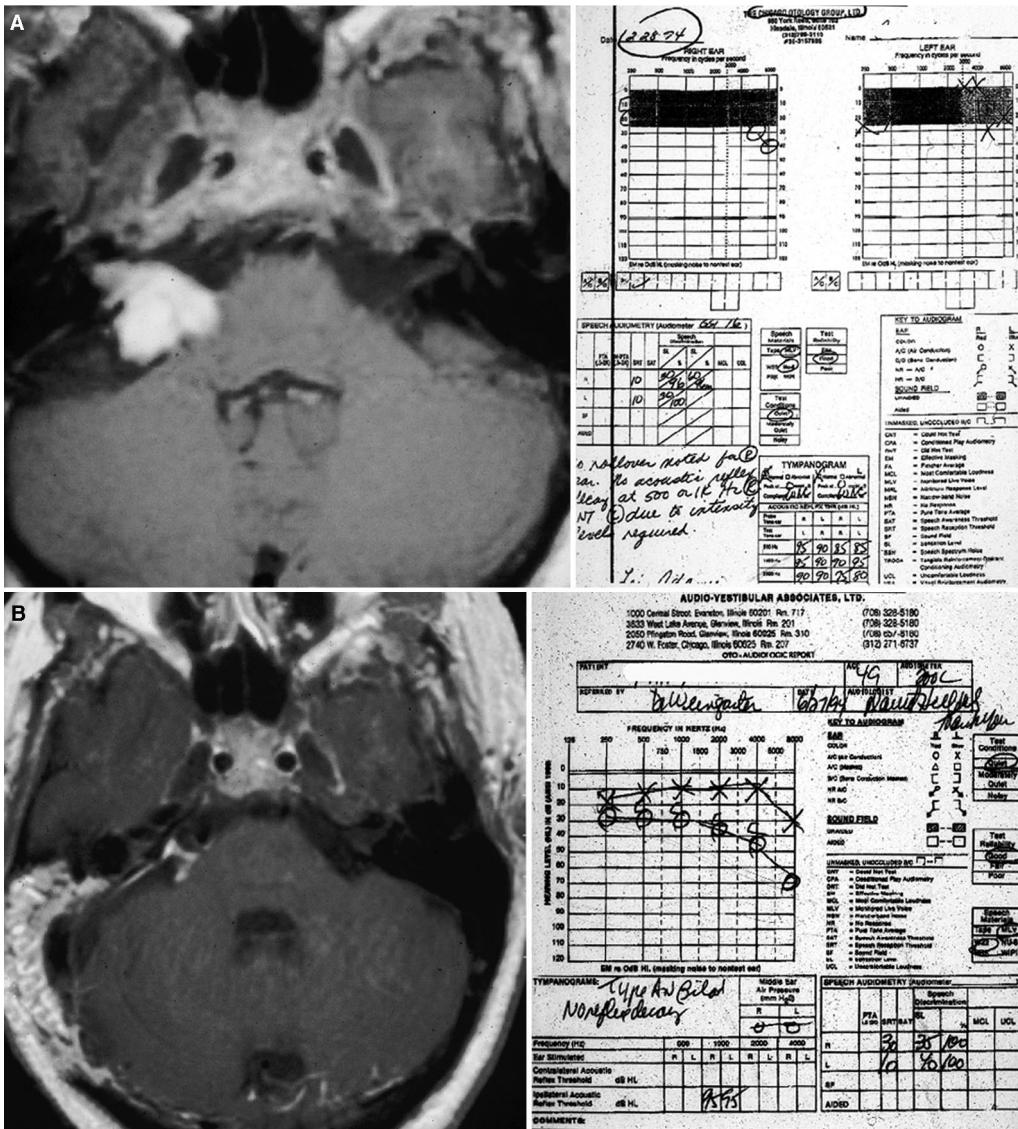


FIGURE 10. Magnetic resonance imaging scan showing the largest vestibular schwannoma case in our series in which the patient's hearing was saved. A, preoperative magnetic resonance imaging scan and audiogram showing a speech discrimination score of 96%. B, postoperative magnetic resonance imaging scan and audiogram showing an improved speech discrimination score of 100%.

arachnoid covering these nerves, the brainstem, and the adjacent vessels so that the plane of dissection remains strictly between the tumor capsule and the arachnoid. Because enough of the tumor capsule has been freed, the redundant capsule in the CPA can then be resected, always keeping the cochlear and facial nerves in sight so that they remain out of harm's way. At this point in the operation, attention is focused on the residual tumor in the IAC and in the vicinity of the meatus itself. The dissection here proceeds in a lateral-to-medial direction, from the fundus of the IAC toward the meatus, with care being taken to avoid lateral-to-medial traction on the cochlear nerve. Even in the IAC, the surgeon should search for the

arachnoid plane of cleavage that separates the cochlear and facial nerves from the tumor capsule.

The last portion of the tumor to be removed is at the meatus itself, where the cochlear and facial nerves are usually most attenuated and adherent to the tumor capsule. The intimate adherence of the facial nerve to the tumor capsule in some cases is the result of chronic compression in a confined space of the meatus, resulting in venous stasis; fibrin exudate; and, eventually, adhesions between the facial nerve, arachnoid, and tumor capsule. High-power magnification as well as patient and meticulous microsurgical techniques allow for complete removal of the tumor capsule at the meatus in the majority of cases. With the tumor removed, the attenuated cochlear and facial nerves exhibit a deep groove resembling a chalice in which the tumor was nestled. When the facial nerve is divided during removal of large tumors, there are several options for facial nerve reconstruction. Our preferred strategy is to attempt a direct end-to-end anastomosis in situ using no more than two or three 10-0 monofilament nylon sutures (Fig. 5).

Hemostasis

In smaller tumors, the operation is associated with minimal, if any, bleeding. In larger tumors, especially in the younger age groups, there can be vigorous bleeding from the tumor during tumor decompression. When there is bleeding during tumor decompression, suction should always be in place within the tumor bed cavity so as to facilitate a clear operative field and hemostasis of the tumor bed using nonadherent bipolar coagulating forceps at low-current settings under continuous irrigation. Bipolar coagulation outside the tumor capsule should be avoided or at least used sparingly and only if the facial and cochlear nerves and their blood supply are clearly identifiable and out of harm's way. Monopolar

coagulation has no role in vestibular schwannoma surgery and should not be used. The operative field should be equipped with three suction lines so that when the surgeon needs to exchange the suction devices in one of his hands (left hand for a right-handed surgeon), the second suction tip can be introduced temporarily into the tumor bed cavity with the other hand. At no time is bleeding inside the tumor allowed to spill into the subarachnoid space. The use of a perforated suction tip, available in various sizes, with a bulbous end is preferred so as to prevent undue and potentially injurious adherence of the tissues to the suction tip. In addition, such suction tips lend themselves to use as a nontraumatic dissecting and retracting tool. Surgeons who prefer to operate on patients placed in a sitting position probably do have an easier time with hemostasis for several reasons, mostly as a result of spontaneous gravity-induced outflow from the operative site. This is further promoted by irrigation without the need for continuous suction. Conversely, there are also some obvious disadvantages of the sitting position, a discussion of which is beyond the scope of this article.

Closure

With the hemostasis complete and secure also with the intrathoracic pressure temporarily raised by the anesthesiologist, the closure is begun by applying bone wax to the drilled surface of the IAC to prevent the escape of cerebrospinal fluid into the middle ear and the eustachian tube via opened air cells in the petrous bone. The dura of the posterior fossa is closed with nonresorbable suture material using the interrupted suture technique. We have not had instances of cerebrospinal fluid leakage since we began using an autologous fat graft that is secured over the dura suture line using a surface-to-surface suture technique (dura adjacent to the suture line to fat graft and fat graft to dura on the opposite side of the suture line). The opened mastoid air cells are thoroughly sealed off with bone wax. The bone flap is replaced and secured only to the underlying dura. The surrounding gaps between the flap and the craniotomy margins are filled with the remaining autologous fat graft. The operative site is then thoroughly irrigated with a topical antibiotic solution, and the incision is closed in anatomic layers.

ILLUSTRATIVE CASES

Figures 6 and 7 demonstrate representative cases from our series, especially as far as tumor size is concerned. Figures 8 and 9 are representative of our long-term follow-up cases, and Figure 10 comprises magnetic resonance imaging scans of a patient with the largest tumor in our series in whom useful hearing was preserved.

POSITIVE PROGNOSTIC FACTORS FOR HEARING PRESERVATION

In our experience, the positive prognostic factors for hearing preservation were useful preoperative hearing (speech reception threshold <50 dB in middle to high frequencies and a speech discrimination score of >50%). In fact, intact preop-

erative hearing was associated with the best chance of saving hearing. Furthermore, the presence of at least Waves 1 and 5 on the preoperative BAER study was a positive prognostic factor for hearing preservation. The more normal the preoperative BAER tracing, the better was the chance of saving hearing. Moreover, smaller tumors (<1.5 cm) and minimal involvement of the IAC by the tumor were also associated with a higher incidence of hearing preservation. Conversely, when the IAC was packed with the tumor all the way to the IAC fundus, hearing preservation proved to be much more difficult. It has also been our experience that superior tumor growth away from the cochlear nerve is associated with more favorable outcomes relative to hearing preservation when compared with tumors that significantly straddle the cochlear nerve. Finally, blood supply to the cochlear nerve that reaches the nerve from its inferior or ventral side portends a better prognosis for hearing preservation than when this blood supply first meanders through the tumor capsule before reaching the cochlear nerve from its dorsal side.

CONCLUSIONS

Preservation of facial nerve function in surgery for removal of all but extremely large vestibular schwannomas is presently considered the standard of care in the surgical treatment of these tumors. Hearing preservation should be attempted in all patients with useful preoperative hearing undergoing retrosigmoid removal of vestibular schwannomas. Certain favorable prognostic factors in this regard have been identified and discussed. Operative nuances that promote facial nerve function and hearing preservation in vestibular schwannomas have been described.

REFERENCES

1. Baldwin DL, King TT, Morrison AW: Hearing conservation in acoustic neuroma surgery via the posterior fossa. *J Laryngol Otol* 104:463–467, 1990.
2. Chee GH, Nedzelski JM, Rowed D: Acoustic neuroma surgery: The results of long-term hearing preservation. *Otol Neurotol* 24:672–676, 2003.
3. Frerebeau P, Benezech J, Uziel A, Coubes P, Segnarbieux F, Malonga M: Hearing preservation after acoustic neurinoma operation. *Neurosurgery* 21:197–200, 1987.
4. Gardner G, Robertson JH: Hearing preservation in unilateral acoustic neuroma surgery. *Ann Otol Rhinol Laryngol* 97:55–66, 1988.
5. Glasscock ME III, Hays JW, Minor LB, Haynes DS, Carrasco VN: Preservation of hearing in surgery for acoustic neuromas. *J Neurosurg* 78:864–870, 1993.
6. Haines SJ, Levine SC: Intracanalicular acoustic neuroma: Early surgery for preservation of hearing. *J Neurosurg* 79:515–520, 1993.
7. Kemink JL, LaRouere MJ, Kileny PR, Telian SA, Hoff JT: Hearing preservation following suboccipital removal of acoustic neuromas. *Laryngoscope* 100:597–602, 1990.
8. Lassaletta L, Fontes L, Melcon E, Sarria MJ, Gavilan JV: Hearing preservation with the retrosigmoid approach for vestibular schwannoma: Myth or reality? *Otolaryngol Head Neck Surg* 129:397–401, 2003.
9. Magnan T, Barbieri M, Mora R, Murphy S, Meller R, Bruzzo M, Chays A: Retrosigmoid approach for small and medium-sized acoustic neuromas. *Otol Neurotol* 23:141–145, 2002.

10. Moriyama T, Fukushima T, Asaoka K, Roche PH, Barrs DM, McElveen JT Jr: Hearing preservation in acoustic neuroma surgery: Importance of adhesion between the cochlear nerve and the tumor. *J Neurosurg* 97:337-340, 2002.
11. Nadol JB Jr, Levine R, Ojemann RG, Martuza RL, Montgomery WW, de Sandoval PK: Preservation of hearing in surgical removal of acoustic neuromas of the internal auditory canal and cerebellar pontine angle. *Laryngoscope* 97:1287-1294, 1987.
12. Niranjan A, Lunsford LD, Kondziolka D, Flickinger J: Gamma knife radiosurgery for acoustic tumors. *Neurosurgery* 4:36-42, 2001.
13. Palva T, Troupp H, Jauhainene T: Hearing preservation in acoustic neuroma surgery. *Acta Otolaryngol (Stockh)* 99:1-7, 1985.
14. Samii M, Matthies C: Management of 1000 vestibular schwannomas (acoustic neuromas): Hearing function in 1000 tumor resections. *Neurosurgery* 40:248-262, 1997.
15. Silverstein H, McDaniel AB, Norrell H: Hearing preservation after acoustic neuroma surgery using intraoperative direct eighth cranial nerve monitoring. *Am J Otol Suppl*:99-106, 1985.
16. Smith MFW, Lager RL: hearing conservation in acoustic neurilemmoma surgery via the retrosigmoid approach. *Otolaryngol Head Neck Surg* 92:168-175, 1984.
17. Sterkers JM, Sterkers O, Maudelonde C: Preservation of hearing by the retrosigmoid approach in acoustic neuroma surgery. *Adv Otorhinolaryngol* 34: 187-192, 1984.
18. Yaşargil MG, Smith RD, Gasser JC: Microsurgical approach to acoustic neurinomas. *Adv Tech Stand Neurosurg* 4:93-129, 1977.
19. Yokoh A, Kobayashi S, Tanaka Y, Gibo H, Sugita K: Preservation of cochlear nerve function in acoustic neurinoma surgery. *Acta Neurochir (Wien)* 123:8-13, 1993.

Acknowledgment

We thank Armela Nantes-Marquez for her assistance with the preparation of the manuscript.

COMMENTS

This is a very well-written and easy-to-follow text on the operative technique of removing vestibular schwannomas by a suboccipital retrosigmoid approach. This review would serve as a starting point for someone interested in performing this type of surgery. I do think that there is a long learning curve for this surgery, and the best results are still going to be achieved by surgeons who perform this surgery frequently and have had an opportunity to "fine-tune" what Ciric et al. describe in this article.

The loss of facial nerve function should be the exception, although hearing preservation continues to be much less of a sure thing, especially for tumors greater than 2 cm in diameter. The availability and success rate of gamma knife treatment has continued to "raise the bar." Anyone performing surgery to remove vestibular nerve schwannomas has to strive for outcomes as good as or better than those of the very experienced and recognized centers that deal with this type of tumor routinely. I have always thought that the approach used for resection of these tumors is less important than the expertise and familiarity of the surgeon using the given approach. I have been very satisfied with the outcomes I have observed when using the approach described.

Michael J. Ebersold
Rochester, Minnesota

This article offers a detailed description of microsurgical nuances for the removal of vestibular schwannomas in the supine position. The anatomic description of bony landmarks, with identifica-

tion of the asterion and the digastric groove, and the variable position of the mastoid emissary are important for the localization of the craniotomy. The authors point out the importance of preoperative high-resolution computed tomographic scans, also for the identification of the posterior semicircular canal and its location with regard to the posterior rim of the internal acoustic meatus.

The importance of the arachnoid layers covering the tumor on the one hand and the neurovascular layers on the other is outlined in the anatomic description. In the description of the microsurgical procedure itself, the authors point out the need for identification of the arachnoid membranes and the neurovascular structures and recommend the use of three suction devices with various perforated bulbous suction tips. The authors are right to contend that surgeons who are able to use the semisitting position do have an easier time with regard to suction devices. In particular, the identification of the arachnoid membranes and the neurovascular structures is facilitated in this position. We use one suction-irrigation device during the microsurgical procedure.

There are some interesting topics addressed in this microsurgical description, e.g., how to deal with arteries in front of the tumor, attached to the petrous bone, and the avoidance of bipolar coagulation outside the tumor bed. We agree that monopolar coagulation has no role in vestibular schwannoma surgery, and it is preferable to use bipolar low-current forceps with nonadherent tips instead. The role of internal decompression of the tumor in the case of larger tumors (>1.5 cm) is addressed, with the advantage of better identification of neurovascular structures and decompression of the brainstem and cranial nerves.

The opening of the cerebellomedullary cistern is described after dural opening as a critical maneuver for the escape of cerebrospinal fluid and opens the cerebellopontine angle for the surgeon without unnecessary cerebellar compression. The importance of intraoperative continuous electrophysiological monitoring is underlined and should include acoustic evoked potentials (brainstem auditory evoked potentials), facial electromyography, and somatosensory evoked potentials. The latter is to identify spinal cord compression during positioning of the patient. In particular, patients with degenerated cervical spines are at risk, and plain x-rays of the cervical spine help to identify them preoperatively.

Regarding the strategy for facial nerve reconstruction after division during surgery, our experience has been that a direct end-to-end anastomosis is rarely possible. A sural nerve graft attached with fibrin glue avoids tension to the reconstructed facial nerve (1, 2).

Concerning the dural closure and the avoidance of cerebrospinal fluid fistula, we have had good experiences with autologous fat grafts, but we prefer the use of muscle grafts harvested from the neck muscles during dissection of the bone. This autologous muscle graft is attached by fibrin glue to the drilled posterior rim of the internal acoustic meatus, to the opened mastoid air cells, and, if necessary, to the sutured dura. We do not use bone wax for the sealing of mastoid air cells since experiencing wound healing problems in some patients (2). We agree that good preoperative hearing and normal brainstem auditory evoked potential recordings are associated with a higher rate of hearing preservation.

Surgery on vestibular schwannomas in the 21st century should be able to preserve facial and cochlear nerves with a minimal

risk. Every possible technique that helps us to reach this goal should be applied routinely in vestibular schwannoma surgery. This detailed description from an experienced neurosurgeon is a helpful guide for planning of the procedure.

Madjid Samii
Wolf Lüdemann
Hannover, Germany

1. Lüdemann W, Stan AC, Tatagiba M, Samii M: Sporadic unilateral vestibular schwannoma with islets of meningioma: Case report. *Neurosurgery* 47:451–452, 2000.
2. Samii M, Matthies C: Management of 1000 vestibular schwannomas (acoustic neuromas): Surgical management and results with an emphasis on complications and how to avoid them—Clinical study. *Neurosurgery* 40:11–23, 1997.

Arteries and veins of the human body (engraving, 1704), by John Harris (from, Stafford BM: Body Criticism: Imaging the Unseen in Enlightenment Art and Medicine. Cambridge, MIT Press, 1991).

