

## CONTINUING MEDICAL EDUCATION ΣΥΝΕΧΙΖΟΜΕΝΗ ΙΑΤΡΙΚΗ ΕΚΠΑΙΔΕΥΣΗ

---

### Oral Medicine and Pathology Quiz – Case 20

A 66-year-old man was referred by his prosthodontist for evaluation of gingival swelling of several years duration in the left mandibular molar area. Clinical examination revealed diffuse lobulated swelling of free and attached buccal gingiva of normal color and rubbery consistency in the left mandibular premolar-molar area (fig. 1). Less prominent gingival swelling was also noticed on the lingual aspect of the same region (fig. 2). In this area, one

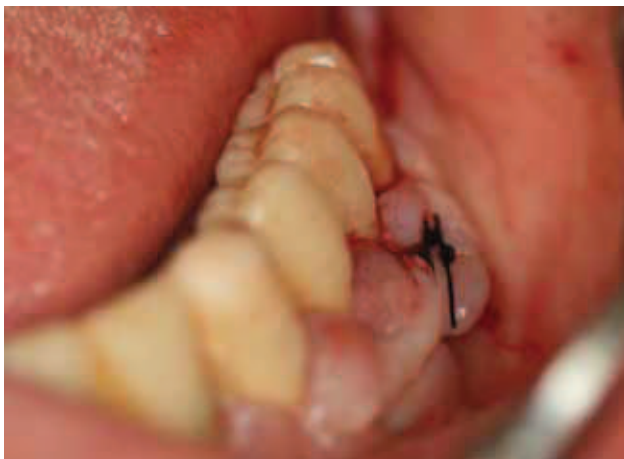

Figure 1

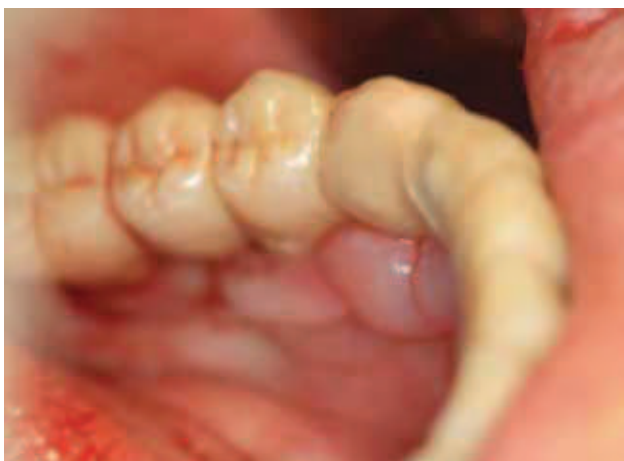

Figure 2

piece transmucosal osseointegrated implants and a full arch fixed prosthetic restoration had been placed seven years previously after the extraction of the remaining periodontally involved teeth. The patient did not respond to the follow-up program that was prescribed postoperatively or any of the recall efforts and he only came back for the first time to his prosthodontist when the cementation of the mandibular prosthesis became loose. Upon removal of the prosthesis the implants were found firmly osseointegrated, yet the implant on site 34 had developed peri-implantitis, bone loss and circumferential pocketing (fig. 3). Medical history was remarkable for diabetes mellitus (treated with metformin and glimepiride without adequate control based on recent blood tests showing elevated glucose and HbA1c levels) and hypertension (managed with ramipril, hydrochlorothiazide and amlodipine for several years). An incisional biopsy of the left buccal mandibular gingival swelling was performed revealing prominent fibrous hyperplasia and mild inflammation (fig. 4).

#### Comment

*Diffuse gingival enlargement may be due to a variety of local and systemic factors. Local factors associated with periodontal disease, such as poor oral hygiene, malocclusion, chronic mouth*

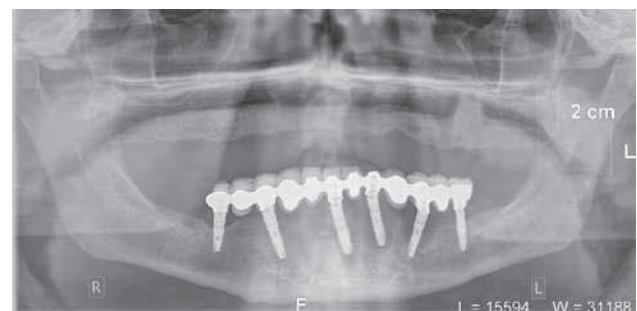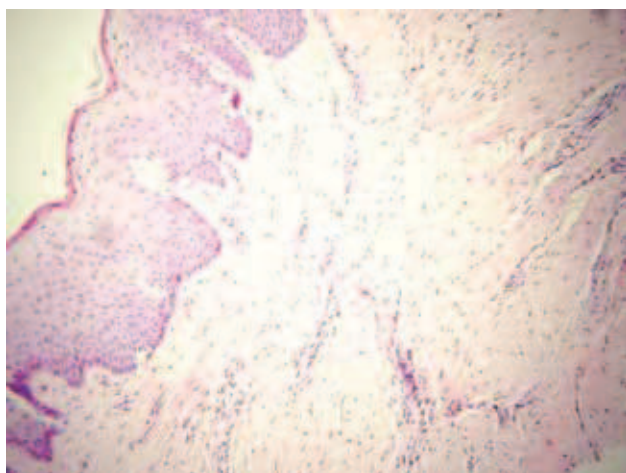


Figure 3

ARCHIVES OF HELLENIC MEDICINE 2012, 29(3):382–383  
ΑΡΧΕΙΑ ΕΛΛΗΝΙΚΗΣ ΙΑΤΡΙΚΗΣ 2012, 29(3):382–383

**N.G. Nikitakis,  
A.P. Tripodakis,  
S. Titsinides,  
A. Sklavounou-Andrikopoulou**

*Department of Oral Medicine and  
Pathology, School of Dentistry, National  
and Kapodistrian University of Athens,  
Athens, Greece*



**Figure 4**

breathing, and suboptimal restorations and oral appliances, may result in prominent gingival overgrowth, also termed chronic hyperplastic gingivitis. The latter may be induced or exacerbated by systemic factors, such as diabetes and hormonal influences during puberty and pregnancy. Other systemic conditions associated with diffuse gingival enlargement include hereditary diseases (gingival fibromatosis), hematologic malignancies (leukemia), Wegener granulomatosis, scurvy, as well as specific drug intake. A biopsy of persistent or atypical hyperplastic gingiva is often necessary in order to establish the final diagnosis.

The prevalence of medication-related gingival hyperplasia (or, more accurately, enlargement or overgrowth) cannot be accurately assessed due to factors such as lack of specific criteria of gingival enlargement assessment, simultaneous administration of other medications and variable level of oral hygiene and underlying periodontal conditions. Drugs associated with gingival enlargement can be broadly divided into three categories: anticonvulsants (mainly phenytoin), immunosuppressants (mainly cyclosporine) and calcium channel blockers. Although the pharmacologic properties of each drug category are distinctly different, all seem to exert a similar effect on the gingival connective tissue, causing diffuse enlargement. Clinical manifestation of gingival enlargement may appear within 1 to 3 months after initiation of treatment, usually beginning at the interdental papillae and progressively extending and possibly interfering not only with esthetics, but also with oral hygiene, mastication and speech. Microscopic examination of drug-induced gingival enlargement demonstrates hyperplastic connective tissue with abundant collagen bundles, admixed with variable numbers of inflammatory cells; the overlying epithelium frequently exhibits hyperplasia with elongated rete ridges. Discontinuation of the medication, if possible, along with appropriate oral hygiene and

professional tooth cleaning, may result in restoration of the gingival architecture in a few weeks. In persistent cases of excessive gingival overgrowth, surgical removal (e.g. gingivectomy and gingivoplasty) may become necessary; however, the condition may recur with continuation of the offending drug, especially if rigorous oral hygiene is not maintained.

Various types of calcium channel blockers, one of the most commonly prescribed drug classes for the management of hypertension, are implicated in gingival enlargement. About 25% of patients receiving nifedipine develop gingival overgrowth, with fewer cases associated with the use of amlodipine, felodipine, verapamil, and diltiazem. The frequency of occurrence, severity and distribution of the gingival enlargement are multifactorial related with individual patient's susceptibility and local factors, primarily plaque control. Although there are conflicting data, most studies have not reported a significant association with dosage. On the other hand, interactions between simultaneously administered medications affecting gingival enlargement have been reported. More significantly, the severity of drug-induced gingival enlargement correlates well with poor plaque control, so that excellent oral hygiene may prevent or reduce the severity of the gingival overgrowth.

Uncontrolled diabetes mellitus is a known risk factor for the development of periodontal disease. Specifically, the frequency, severity and progression rate of periodontal disease in diabetic patients are higher compared to non-diabetics. Similarly, diabetes may predispose to the development of chronic hyperplastic gingivitis. In the case presented here, diabetes and amlodipine use, along with suboptimal oral hygiene and lack of dental professional care following implant placement, may have acted synergistically in inducing significant gingival enlargement.

## References

1. MARSHALL RI, BARTOLD PM. A clinical review of drug-induced gingival overgrowths. *Aust Dent J* 1999, 44:219–232
2. NAKIB N, ASHRAFI SS. Drug-induced gingival overgrowth. *Dis Mon* 2011, 57:225–230
3. ELLIS JS, SEYMOUR RA, STEELE JG, ROBERTSON P, BUTLERTJ, THOMASON JM. Prevalence of gingival overgrowth induced by calcium channel blockers: A community-based study. *J Periodontol* 1999, 70:63–67

Corresponding author:

N.G. Nikitakis, Department of Oral Pathology and Medicine, School of Dentistry, National and Kapodistrian University of Athens, 2 Thivon street, GR-115 27 Athens, Greece, tel.: +30 210 7461003, fax: +30 210 7461220  
e-mail: nnikitakis1@yahoo.com

**Diagnosis:** Gingival hyperplasia (drug-induced and diabetes-associated) combined with perimplantitis