

> NIKOLAOS G. NIKITAKIS¹, ARIS-PETROS TRIPODAKIS², PROKOPIOS ARGYRIS³, ALEXANDRA SKLAVOUNOU⁴

Department of Oral Pathology and Medicine, School of Dentistry, National and Kapodistrian University of Athens (Greece)

¹ DDS, PhD

³ DDS

⁴ DDS, MS, Dr. Dent.

² Department of Prosthodontics, School of Dentistry, National and Kapodistrian University of Athens (Greece)

DDS, MS, Dr. Dent.

Jaw exostoses associated with osseointegrated dental implants. Report of three cases of a newly described phenomenon

ABSTRACT

Background Various irritating factors may cause activation of the periosteum resulting in peripheral bone deposition and exostosis formation. However, dental implant placement has not been associated with development of exostoses. In the present clinical report, three cases of exostoses developing subsequent to dental implant placement are reported and the possible pathogenetic role of periosteal activation is discussed.

Case reports In Case 1, a 51 years old Caucasian woman developed bilateral hard buccal maxillary swellings, about six months after immediate dental implant placement into the extraction sockets, without raising a flap. The swellings remained asymptomatic but showed progressive enlargement during a 5-year follow-up period reaching a maximum diameter of 2 cm. Panoramic radiograph and dental computed tomography showed expansion of the buccal cortical plate and increased bone density. Histopathological examination of the lesion revealed mature compact bone. In Case 2, a 63 years old Caucasian woman presented with an anterior palatal hard tissue swelling; a dental implant had been placed in the left central incisor area two years before, following the same surgical method for implant placement as in Case 1. Case 3 was a 54 years old male with a hard swelling of the buccal side of the mandible in the area of the first and second molar, adjacent to dental implants placed about 2 years before. In this case, the immediate implants were placed after flap elevation.

Conclusion Hard tissue swellings presenting as jaw exostoses in areas of previously placed dental implants are possibly due to periosteal activation caused by the mechanical trauma, mild inflammatory reaction and/or occlusal overload associated with the implant. The exact etiopathogenesis, the frequency and the clinical relevance of periosteal activation and new bone formation in the context of dental implant osseointegration demand further investigation.

KEYWORDS Bone formation; Dental implants; Exostoses; Periosteal reaction.

INTRODUCTION

Exostoses present as localized bony protuberances arising from the cortical plate of the jaws (1, 2). Depending on their location and clinical presentation, they are classified into various categories. The most common variants are the torus palatinus and torus mandibularis, the etiology of which is considered multifactorial, encompassing both genetic and environmental (e.g. masticatory stress) influences (1, 2). Other described subtypes include the multiple buccal exostoses, arising along the facial aspect of the upper or lower alveolar ridge, and the palatal exostoses, affecting the lingual aspect of the maxillary tuberosities; both buccal and palatal exostoses usually present in a bilateral fashion (1, 2). Solitary exostoses may also develop, frequently attributed to local irritation such as the placement of a gingival or skin graft; similarly, the close association of the alveolar crestal bone with the pontic of a bridge may result in the development of a localized bony protuberance, which is termed reactive subpontine exostosis (1, 3). Various local irritating factors could theoretically induce the osteogenic activity of the periosteum resulting in new bone formation. However, the clinical presentation of an exostosis, in association with dental implant placement has not been previously described, to the best of our knowledge.

The purpose of the present report is to present 3 cases of bone enlargement with clinical features of exostoses that developed adjacent to osseointegrated dental implants and to discuss

the possible mechanisms of pathogenesis.

CASE REPORTS

In all 3 cases, jaw exostoses developed in areas adjacent to dental implants in a period of 6-12 months after the final prosthesis was in place.

The medical history was non-contributory in all 3 cases. Immediate placement of the endosseous implants (Brånemark System®, Mk III Groovy, Nobel Biocare, Gothenburg, Sweden) with or without flap elevation was performed by the same prosthodontist adhering to the same surgical and prosthetic protocol in all 3 cases.

noticed about 12 months following the dental implant placement and 7 months after the final prosthesis was in place. They remained asymptomatic although progressively increasing in size. On clinical examination, the lesions were found to be covered by normal mucosa, hard in consistency, each measuring about 2 cm in maximum with a height of approximately 0.7 cm (Fig. 1). Periodic radiographic examination consisted of panoramic radiographs and dental computed tomography (local volumetric tomography, Aquitomo, Morita, Japan). Dental CT images were comparable, because they were taken with the same hardware and were digitally processed so to be three-dimensionally oriented along the long axis of the implants and perpendicularly to the tangent of the curve of the

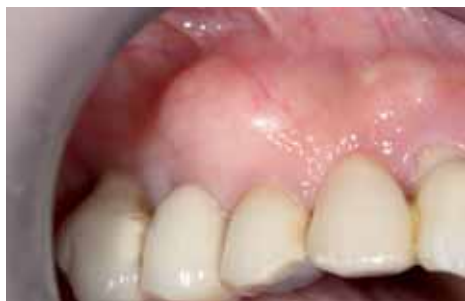

Fig. 1 Clinical features of the right sided exostosis of Case 1 showing an ovoid lesion of hard consistency covered by normal mucosa in the premolar area of the maxillary buccal cortex.

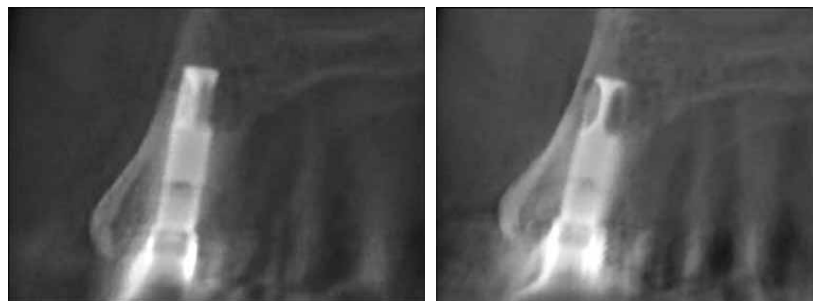


Fig. 2 Dental computed tomography (dental scan) of the right sided exostosis of Case 1 depicting progressive expansion of the cortical plate and increased bone density (A, 2 years after implant placement; B, 3 years after implant placement).

Case 1

A 51 years old Caucasian woman presented with two bilateral hard swellings of the buccal cortical plates of the maxilla in the premolar areas. Dental implants had been placed in these areas about 5 years before, into the extraction sockets immediately after the periodontally hopeless teeth were removed, without raising a flap. The screw retained prosthesis was inserted 5 months after the placement, directly attached on the implants without the application of a transmucosal abutment. The lesions had been first

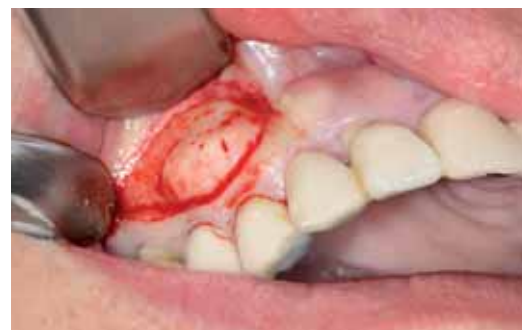

Fig. 3 Intra-operative view during surgical removal of the right sided lesion of Case 1.

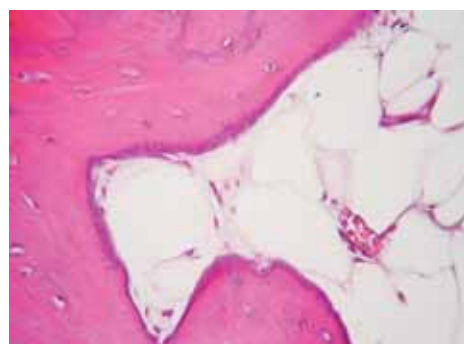


Fig. 4 Histopathologic examination of the excised right sided lesion of Case 1 revealing mature compact bone (A) with limited amount of fibrofatty bone marrow (B) (A and B, hematoxylin-eosin, 400x).

dental arch. Progressive expansion of the cortical plate and increased bone density were noticed (Fig. 2). The right sided lesion was removed surgically (Fig. 3) and submitted to histopathologic examination, which revealed mature compact bone with limited amount of fibrofatty bone marrow; a few dispersed chronic inflammatory cells were also seen (Fig. 4). The final diagnosis was exostosis.

Case 2

A 63 years old Caucasian woman complained of a hard tissue swelling on the palatal side in the anterior maxilla, present for the last year. The swelling was located adjacent to the dental implant placed 2 years ago in the area of the missing left central incisor. The surgical and prosthetic procedures were the same as described in Case 1 involving flapless intrasocket immediate implant placement followed by a cross-arch splinted screw retained ceramometal prosthesis. Considering the cross-arch stabilization of the eight implants supporting the fixed prosthesis, the possibility of occlusal overloading in the area of the anterior maxilla is non relevant. The asymptomatic lesion was covered by normal mucosa measuring 1 cm in maximum diameter and 0.5 cm in height. A clinical diagnosis of exostosis was made.

Case 3

A 54 years old man noticed a hard swelling of recent onset in the right posterior mandible. The swelling was covered by normal mucosa and was asymptomatic, measuring 1 cm in maximum diameter and 0.5 cm in height. It was located on the buccal cortical bone of the right mandible in the molar area, where dental implants had been placed about 2 years before. The surgical technique in this case was different from the technique applied in the two previous cases. Two 10 mm implants were surgically placed immediately after the removal of a fractured endodontically treated molar #46 by raising a full thickness flap. Flap elevation was also performed in a second stage surgery to uncover the implants. The prosthetic procedures were those described in the previous cases. The fact that two implants were used to functionally replace one molar in a fully dentulous oral cavity minimizes the possibility of overloading. A clinical diagnosis of exostosis was made.

DISCUSSION

Exostoses are relatively common lesions, considered to develop as a result of both genetic and environmental influences (1, 2). Especially in cases of solitary exostoses, usually developing in adults, a local irritating factor, such as a gingival graft or the pontic of a bridge, is usually implicated (1-3). Even mild irritation may cause osteoblastic activity of the

periosteum resulting in new bone formation on the cortical surface. The clinical sequela of the periosteal activation and the ensuing bone deposition is the expansion of the cortex and the development of a hard tissue swelling appearing as an exostosis. In the cases presented here, the likely cause of the observed hard tissue swelling was the periosteal reaction associated with the placement of dental implants, an association not previously reported.

The inner surface of the periosteum contains pluripotential mesenchymal cells, which under the influence of growth factors and other signaling molecules may differentiate in osteoblasts (4). This osteogenic capacity of the periosteum has significant implications for bone physiology and plays an important role in the healing and recontouring of bone surfaces (4). Moreover, periosteal reaction may accompany a number of pathologic conditions ranging from reactive (such as local trauma) to infectious (such as osteomyelitis) (1, 4). Benign (such as hemangioma) or malignant neoplasms (such as osteosarcomas, chondrosarcomas and Ewing's sarcomas) may activate the periosteum causing characteristic radiographic patterns of periosteal bone reaction (e.g. the sun-ray pattern of osteosarcomas or the onion skin appearance of the Ewing's sarcomas) (1, 4). Notwithstanding these clinically significant and sometimes morbid causes of periosteal activation, osteoblastic activity of the periosteum has been also described in association with mild inflammatory conditions, such as in the case of Garre's osteomyelitis (or osteomyelitis with proliferative periostitis), usually attributed to periapical or periodontal inflammation without a significant intrabony osteomyelitis component (1, 5). More interestingly, cases of proliferative periostitis have been described in the absence of an obvious source of inflammation, sometimes in areas of close proximity to an unerupted tooth (1, 6). Based on these observations, we extrapolate that the placement of a dental implant may also serve as a mild stimulus capable of inducing the osteogenic activity of the adjacent periosteum. It is important to note that all presented cases involved immediate implants after the extraction of periodontally hopeless teeth. In the two maxillary cases the surgical placement was accomplished without flap elevation. Whether there is a correlation between variations in the surgical technique used for implant placement and the risk of periosteal activation and subsequent exostosis formation remains unknown.

The mechanisms by which the placement of a dental implant may result in periosteal activation are unclear. Aberrations in the integration process of endosseous implants have been described as uncommon events that may be either reversible or irreversible resulting in implant failure (7-9). Wiskott et al. (9) classified these aberrations into four categories:

> infectious lesions, such as peri-implantitis,

- intraosseous infectious foci, and septic voids;
- > transitory lesions;
- > lesions related to occlusal overload;
- > healing defects.

Implant periapical lesions have been characterized as disorders of the area surrounding the apex of a dental implant, with a multifactorial etiology such as vascular impairment or ischemia, overheating of bone during drilling, and implant surface contamination (10-12). Such implant-induced periapical lesions may evolve into more diffuse and clinically significant cases of osteomyelitis, a well-known cause of periosteal reaction (13-15). However, no clinical or radiographic evidence of periapical lesions and/or osteomyelitis were noticed in any of the presented cases. On the other hand, it is conceivable that dental implant-related aberrations and/or lesions of mild severity and/or transitory nature may not be sufficient to produce detectable intrabony lesions or cause implant failure but could act as a stimulus for periosteal activation through induction of relevant molecular events. In this regard, it is interesting that other lesions of purported periosteal origin, such as peripheral giant cell granulomas, have been associated with dental implants (16-18).

CONCLUSION

The present clinical reports highlight the previously unreported possibility of exostoses formation in areas of the jaws bearing dental implants. Based on the clinical features and progression of the exostoses in the presented cases, it appears that these lesions are asymptomatic and rather indolent but can exhibit a progressive slow growth. Observation, recording and publication of similar cases are recommended in order to better characterize the clinical features and the exact nature and etiopathogenesis of this condition. Factors such as the demographic profile and medical status of the patients, history of the edentulous sites, the material and type of implants used, the surgical technique, and the possible association with occlusal factors, may be related to the development of exostoses associated with dental implants and need to be further analyzed. Moreover, the study of periosteal activation following implant placement may contribute to our understanding of the interaction between dental implant-related changes in the local microenvironment and induction of osteogenic activity.

REFERENCES

1. Neville BW, Damm DD, Allen CW, Bouquot JE. *Oral and maxillofacial pathology*. 3rd ed. Philadelphia: W.B. Saunders Co; 2009. p.19-23,148-150, 933.
2. Jankittivong A, Langlais RP. Buccal and palatal exostoses: prevalence and concurrence with tori. *Oral Surg Oral Med Oral Pathol Oral Radiol Endod* 2000;90(1):48-53.
3. Frazier KB, Baker PS, Abdelsayed R, Potter B. A case report of subpontic osseous hyperplasia in the maxillary arch. *Oral Surg Oral Med Oral Pathol Oral Radiol Endod* 2000;89(1):73-6.
4. Malizos KN, Papatheodorou LK. The healing potential of the periosteum molecular aspects. *Injury* 2005;36 Suppl 3:S13-9.
5. Kawai T, Murakami S, Sakuda M, Fuchihata H. Radiographic investigation of mandibular periostitis ossificans in 55 cases. *Oral Surg Oral Med Oral Pathol Oral Radiol Endod* 1996;82(6):704-12.
6. Oulis C, Berdousis E, Vadiakas G, Goumenos G. Garre's osteomyelitis of an unusual origin in a 8-year-old child. A case report. *Int J Paediatr Dent* 2000;10(3):240-4.
7. Esposito M, Thomsen P, Ericson LE, Lekholm U. Histopathologic observations on early oral implant failures. *Int J Oral Maxillofac Implants*. 1999;14(6):798-810.
8. Esposito M, Hirsch JM, Lekholm U, Thomsen P. Biological factors contributing to failures of osseointegrated oral implants. (II). Etiopathogenesis. *Eur J Oral Sci* 1998;106(3):721-64.
9. Wiskott HW, Dubrez B, Scherrer SS, Belser UC. Reversible and irreversible peri-implant lesions: report and etiopathogenic analysis of 7 cases. *J Oral Implantol* 2004;30:255-66.
10. Peñarrocha-Diago M, Boronat-Lopez A, García-Mira B. Inflammatory implant periapical lesion: etiology, diagnosis, and treatment-presentation of 7 cases. *J Oral Maxillofac Surg* 2009;67(1):168-73.
11. Cheung LK, Leung AC. Dental implants in reconstructed jaws: implant longevity and peri-implant tissue outcomes. *J Oral Maxillofac Surg* 2003;61(11):1263-74.
12. Heitz-Mayfield LJ. Peri-implant diseases: diagnosis and risk indicators. *J Clin Periodontol* 2008;35(8 Suppl):292-304.
13. O'Sullivan D, King P, Jagger D. Osteomyelitis and pathological mandibular fracture related to a late implant failure: a clinical report. *J Prosthet Dent* 2006;95(2):106-10.
14. Rokadiya S, Malden NJ. An implant periapical lesion leading to acute osteomyelitis with isolation of *Staphylococcus aureus*. *Br Dent J* 2008;205(9):489-91.
15. Kesting MR, Thurmüller P, Ebsen M, Wolff KD. Severe osteomyelitis following immediate placement of a dental implant. *Int J Oral Maxillofac Implants*. 2008;23(1):137-42.
16. Scarano A, Iezzi G, Artese L, Cimorelli E, Piattelli A. Peripheral giant cell granuloma associated with a dental implant. A case report. *Minerva Stomatol* 2008;57(10):529-34.
17. Hirshberg A, Kozlovsky A, Schwartz-Arad D, Mardinger O, Kaplan I. Peripheral giant cell granuloma associated with dental implants. *J Periodontol*. 2003;74(9):1381-4.
18. Cloutier M, Charles M, Carmichael RP, Sándor GK. An analysis of peripheral giant cell granuloma associated with dental implant treatment. *Oral Surg Oral Med Oral Pathol Oral Radiol Endod* 2007;103(5):618-22.