

THE CEREBRUM

Albert L. Rhoton, Jr., M.D.

Department of Neurological Surgery, University of Florida, Gainesville, Florida

Correspondence:

Albert L. Rhoton, Jr., M.D.,
Department of Neurological Surgery, University of Florida, McKnight Brain Institute, P.O. Box 100265, 100 South Newell Drive, Building 59, L2-100, Gainesville, FL 32610-0265.
Email:
rhoton@neurosurgery.ufl.edu

KEY WORDS: Basal ganglia, Cerebral hemispheres, Cerebrum, Craniotomy, Fiber dissections, Frontal lobe, Insula, Internal capsule, Lateral ventricles, Occipital lobe, Optic pathways, Parietal lobe, Sylvian fissure, Temporal lobe

Neurosurgery 51[Suppl 1]:1–51, 2002

DOI: 10.1227/01.NEU.0000028086.48597.4F

www.neurosurgery-online.com

The cerebrum is a remarkably beautiful and delicate structure (Fig. 1.1). The goal of the study of microsurgical anatomy is to perform gentle, precise, and accurate neurosurgery and to be able to navigate safely around and through the cerebrum and intracranial space. Essential to proceeding through the cranium and the brain's surface to the depths is an awareness of the site of the most valuable and vulnerable cortical and subcortical areas and the location of these eloquent areas in relation to the cranial and cerebral landmarks. This requires that the surgeon have a see-through x-ray-type microsurgical knowledge that visualizes deep structures in relation to the surface area exposed and weighs the value of tissue along each route to the targeted intracranial and intracerebral sites. The tentorium cerebelli, a dural projection, divides the intracranial space into supra- and infratentorial compartments. The posterior cranial fossa located below the tentorium in the infratentorial compartment was the subject of the Millennium issue of *Neurosurgery* (5). The supratentorial area and the anterior and middle cranial base are the focus of this issue.

In developing the concept of see-through x-ray-type knowledge of the supratentorial area, the location of selected deep structures are described in relation to the cranial and superficial cerebral landmarks. In numerous stepwise dissections, the author has tried not only to peel away and describe each layer, but also to clarify the relationships between structures in different layers (Fig. 1.2). One example is the relationship of the ventricles to the cerebral convexity. The frontal horn is located deep to the inferior frontal gyrus, the atrium is deep to the supramarginal gyrus, and the temporal horn is deep to the medial temporal gyrus. Another example is the relationship of the foramen of Monro to more superficial structures. At the cranial surface, the foramen of Monro is located deep to a point approximately 2 cm above the pterion, just behind the lower third of the coronal suture; at the cerebral surface, it is located deep to the central part of the pars opercularis of the inferior frontal gyrus; and at the insular level, it is located deep to the central part of the second short insular gyrus (Fig. 1.2). Many other relationships between superficial and deep structures are examined. In describing these relationships, the use of the terms superior, inferior, anterior, and posterior is the same as commonly applied in naming the cere-

bral gyri and sulci. The directional terms used are as follows: superior or above, situated toward the cranial vertex; inferior or below, situated toward the cranial base; anterior to or in front of, situated toward the frontal pole; and posterior or behind, situated toward the occipital pole.

THE HEMISPHERES

The paired cerebral hemispheres constitute the largest part of the brain. They are separated by the longitudinal fissure, interconnected by the corpus callosum, and merged with the diencephalon to establish continuity with the brainstem and the spinal cord. They encase the lateral and third ventricles. The cerebral hemispheres have three surfaces: lateral, medial, and basal; three margins: superior, inferior, and medial; three poles: frontal, temporal, and occipital; three types of white matter fibers: projection, commissural, and association; and five lobes: frontal, parietal, temporal, occipital, and the hidden insula. The most important landmarks for orienting surgery are the three borders, the three poles, the sylvian and interhemispheric fissures, and the central sulcus. The cerebral hemispheres have their greatest transverse diameter across the parietal lobes. The longitudinal fissure, the deep cleft separating the upper part of the paired hemispheres, contains a sickle-shaped process of dura called the falx cerebri that separates the anterior and posterior parts of the hemispheres (Fig. 1.2). The anterior portion of the falx cerebri is not as wide as its posterior part, leaving a wide space anteriorly between the free falx margin and the corpus callosum, where the medial surface of the hemispheres face each other and not the falx. Further posteriorly, the free margin slopes toward and becomes closely applied to the corpus callosum. The anterior part of the cingulate gyrus is below the free margin of the falx cerebri and is free to shift across the midline, whereas the middle and posterior parts have progressively less of the gyrus below and more above the free margin, where its displacement across the midline is limited by the rigidity of the falx (4). The shifts related to the tentorial incisura were reviewed in the Millennium issue of *Neurosurgery* (6).

Hemispheric Surfaces

The cerebral hemispheres have three surfaces: lateral, medial, and basal (Fig. 1.3). The lateral surface, referred to as the

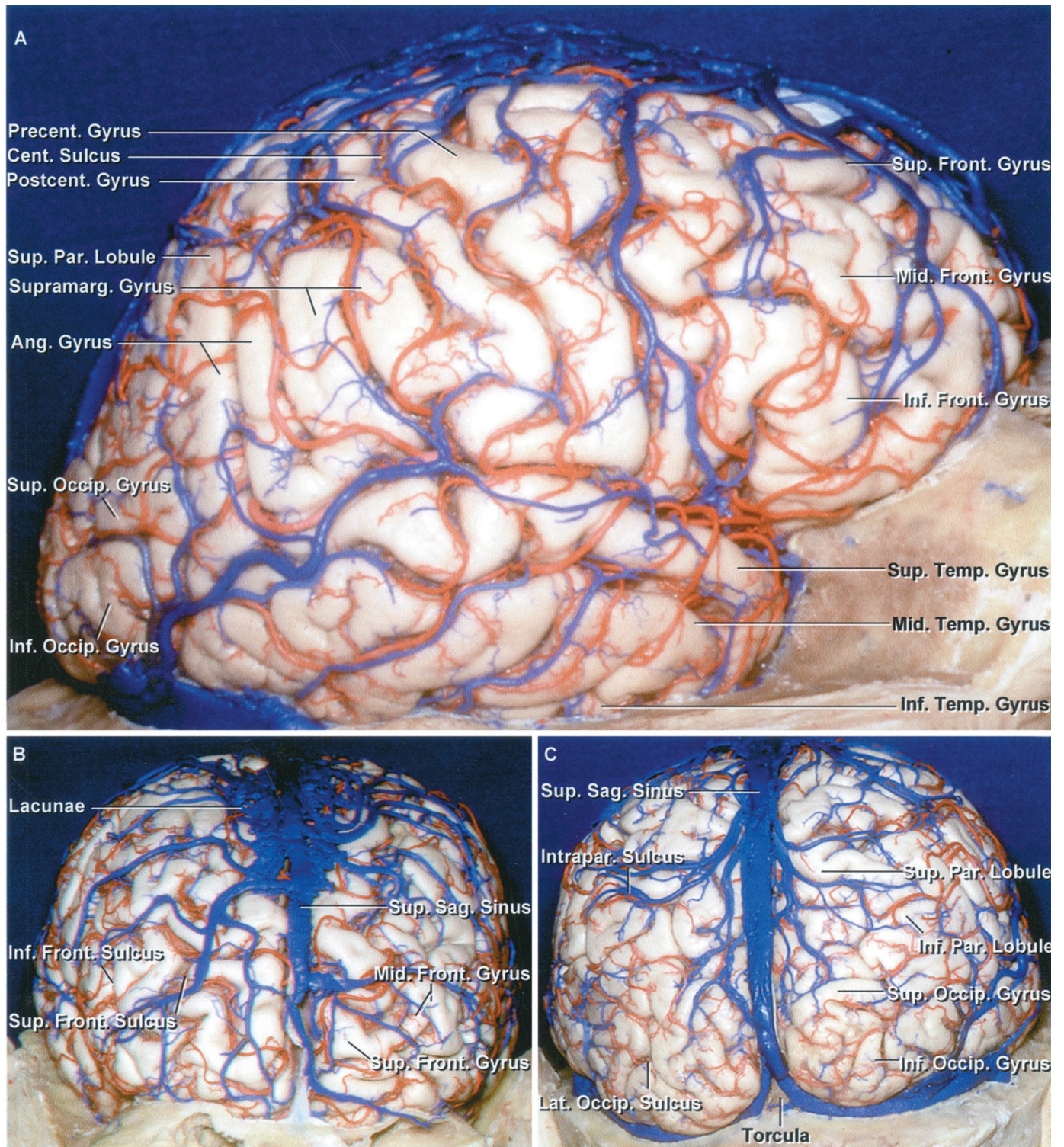


FIGURE 1.1. Lateral view of the right cerebral hemisphere. A, the brain, when exposed carefully and accurately, is a remarkably beautiful structure. The arteries, veins, gyri, and sulci are organized in a complex array. The frontal convexity is made up of the superior, middle, and inferior frontal and precentral gyri. The parietal convexity is composed of the postcentral gyrus and the superior and inferior parietal lobules. The inferior parietal lobule is made up of the supramarginal and angular gyri. The temporal convexity is composed of the superior, middle, and inferior temporal gyri. The occipital convexity is formed by the superior and inferior occipital gyri. B, anterior view. The superior and middle frontal gyri are separated by the superior frontal sulcus. The inferior frontal sulcus courses between the middle and inferior frontal gyri.

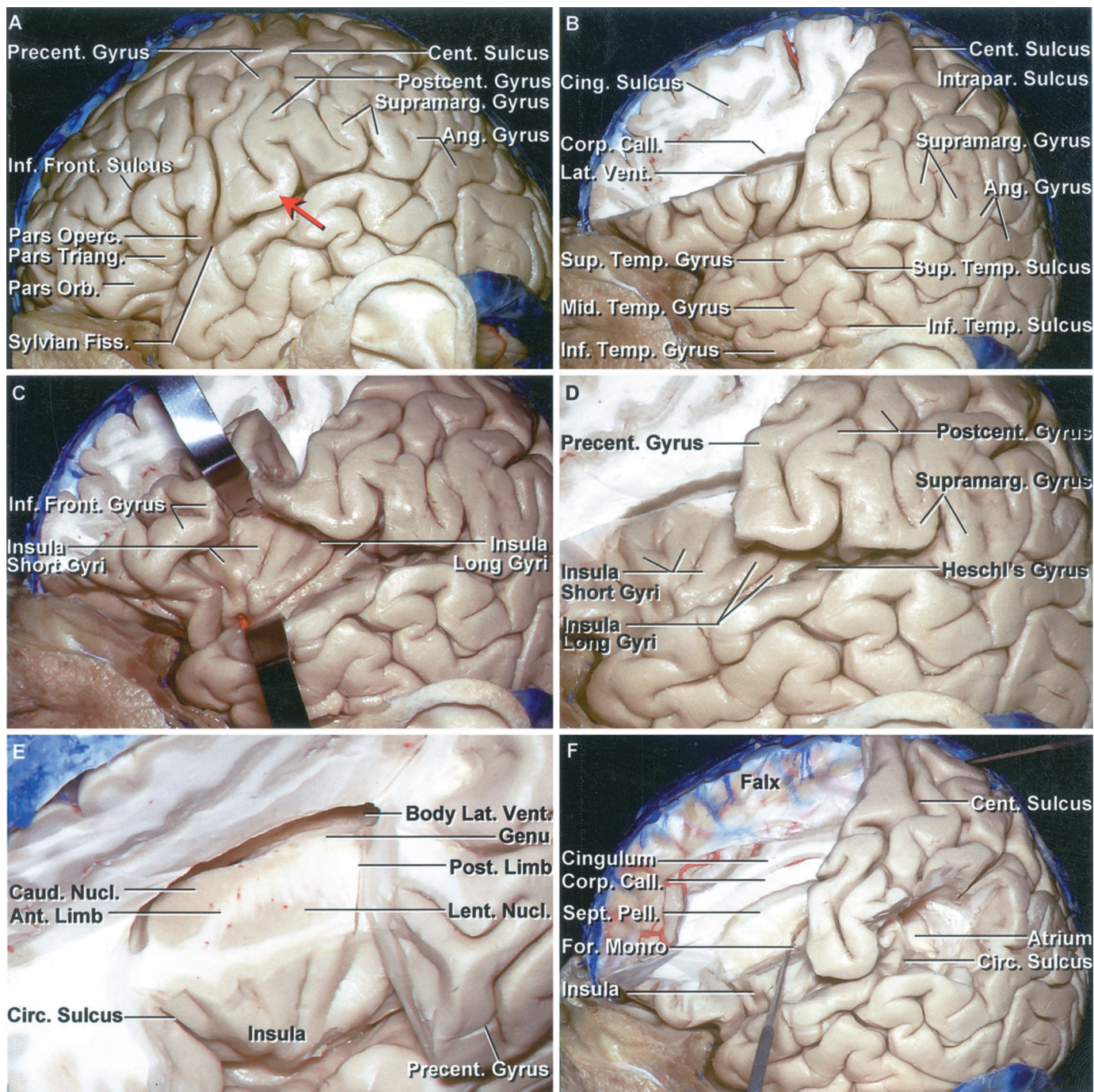


FIGURE 1.2. Stepwise dissection of the left cerebral hemisphere. A, the inferior frontal gyrus is composed of the pars orbitalis, pars opercularis, and pars triangularis. The precentral gyrus borders the sylvian fissure behind the pars opercularis. The sylvian fissure extends (Legend continues on next page.)

←

The veins from the anterior part of the hemisphere are directed backward to reach the superior sagittal sinus. A large venous lacunae extends over the superior margin of the frontal lobe adjacent to the superior sagittal sinus. C, posterior view of the hemisphere. The lateral occipital sulcus divides the lateral aspect of the occipital lobe into the superior and inferior occipital gyri. The veins from the occipital convexity are directed forward to enter the superior sagittal sinus. The posterior part of the parietal lobe is divided by the intraparietal sulcus into the superior and inferior parietal lobules. Ang., angular; Cent., central; Front., frontal; Inf., inferior; Intrapar., intraparietal; Lat., lateral; Mid., middle; Occip., occipital; Par., parietal; Postcent., postcentral; Precent., precentral; Sag., sagittal; Sup., superior; Supramarg., supramarginal; Temp., temporal.

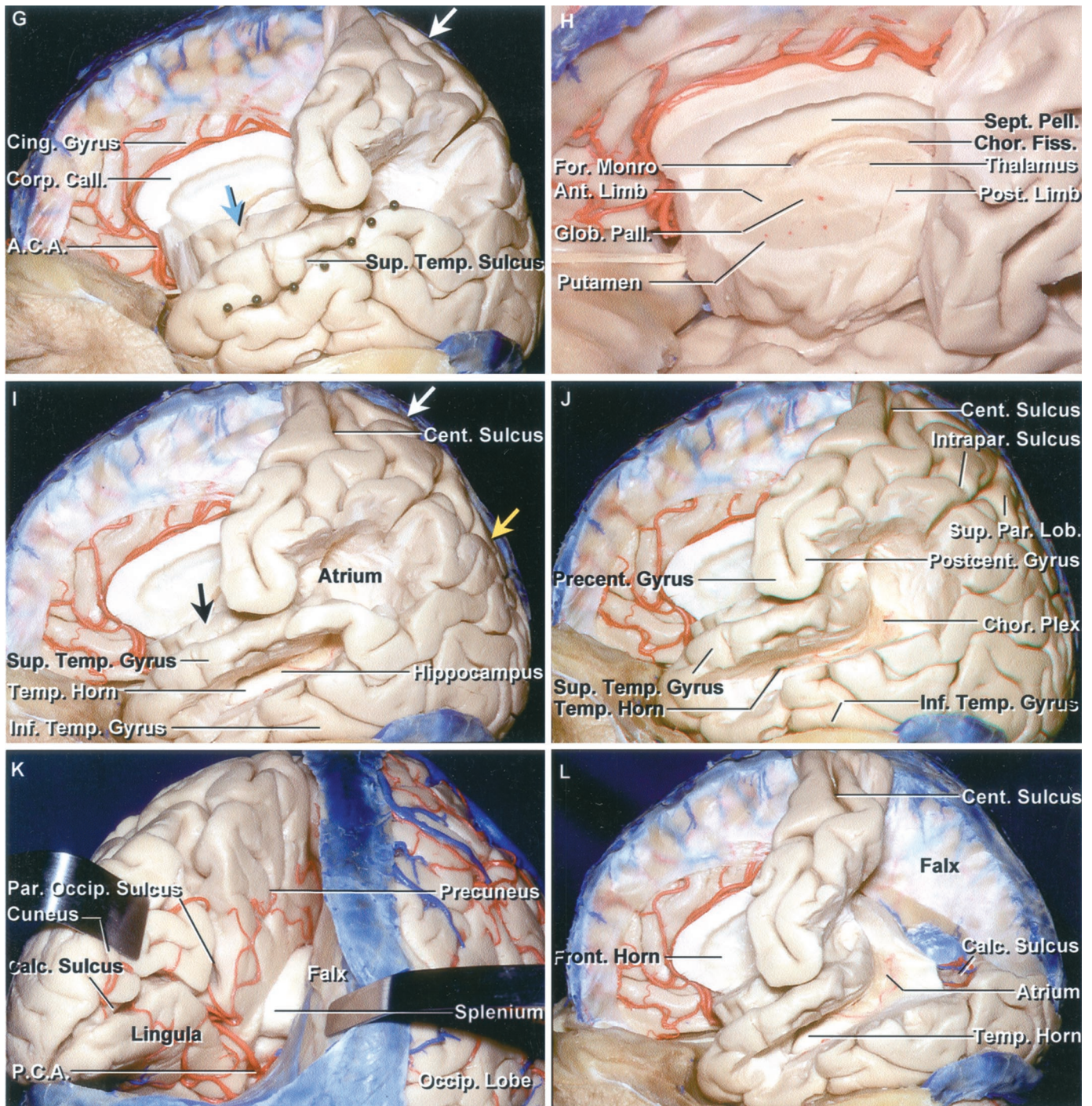


FIGURE 1.2. Continued

backward and turns up into the supramarginal gyrus at its posterior end. The lower part of the postcentral gyrus is positioned in front of the anterior bank of the supramarginal gyrus. The posterior bank of the supramarginal gyrus is continuous with the superior temporal gyrus. The central sulcus ascends between the pre- and postcentral gyri. There is commonly a gyral bridge (red arrow) connecting the pre- and postcentral gyri below the lower end of the central sulcus, so that the central sulcus does not open directly into the sylvian fissure. Often, with the limited craniotomy opening, the whole sylvian fissure is not exposed to aid in identification of the pre- and postcentral gyri and the central sulcus. The position of the lower end of the pre- and postcentral gyri can be approximated by identifying the pars opercularis just in front of the precentral gyrus and the anterior bank of the supramarginal gyrus just in back of the postcentral sulcus. The angular gyrus wraps around the upturned posterior end of the superior temporal sulcus. B, the part of the frontal lobe above the inferior frontal gyrus and in front of the precentral sulcus has been removed while preserving a thin layer of the medial part of the hemisphere. The inferior frontal sulcus is located on the convexity at the deep level of the lower margin of the corpus callosum and roof of the frontal horn.

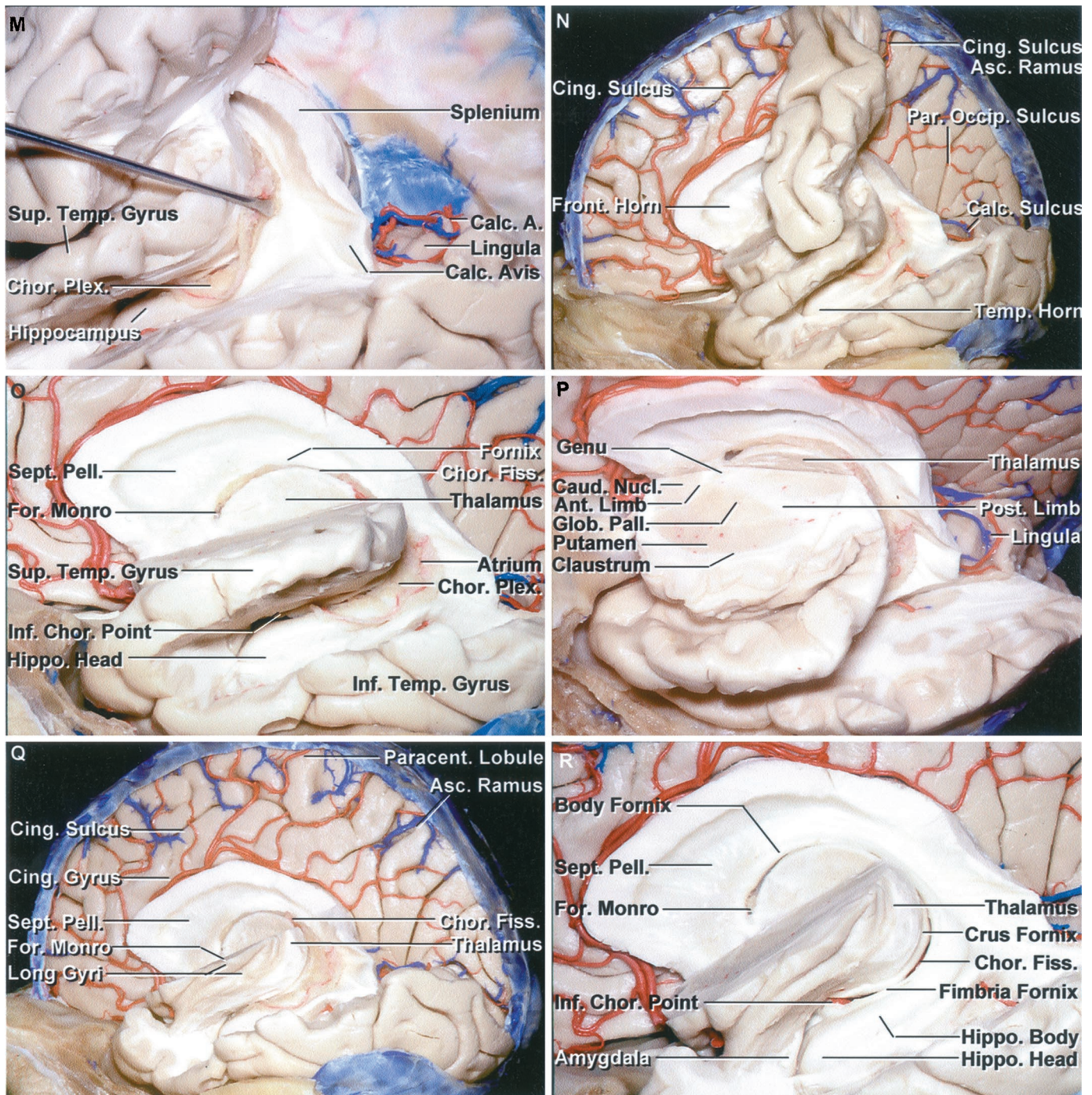


FIGURE 1.2. Continued

The gray matter of the cingulate sulcus is exposed above the corpus callosum. C, the opercular lips have been retracted to expose the insula, which is defined at its outer margin by the circular or limiting sulcus. The short gyri are located anteriorly and the long gyri posteriorly. D, enlarged view with the brain in front of the precentral gyrus removed. The insular gyri radiate upward and backward from the anteroinferior angle situated just lateral to the limen insulae. The short gyri are located deep to the pars triangularis and opercularis. Heschl's gyrus, the most anterior of the transverse temporal gyri, faces the lower end of the postcentral gyrus across the Sylvian fissure. E, anterosuperior view of the central core of the hemisphere located deep to the insulae. The lentiform nucleus is exposed deep to the insula and is separated from the caudate nucleus by the anterior limb of the internal capsule. The circular sulcus surrounds the insula. F, the supramarginal gyrus has been removed to show its location superficial to the atrium. The posterior margins of the insula and circular sulcus are positioned superficial to the anterior edge of the atrium. The pre- and postcentral gyri are located lateral to the body of the ventricle and the splenium of the corpus callosum. The foramen of Monro is located deep to a point on the pars opercularis approximately 1 cm above the Sylvian fissure and deep to the midlevel of the short gyri of the insula. (Legend continues on next page.)

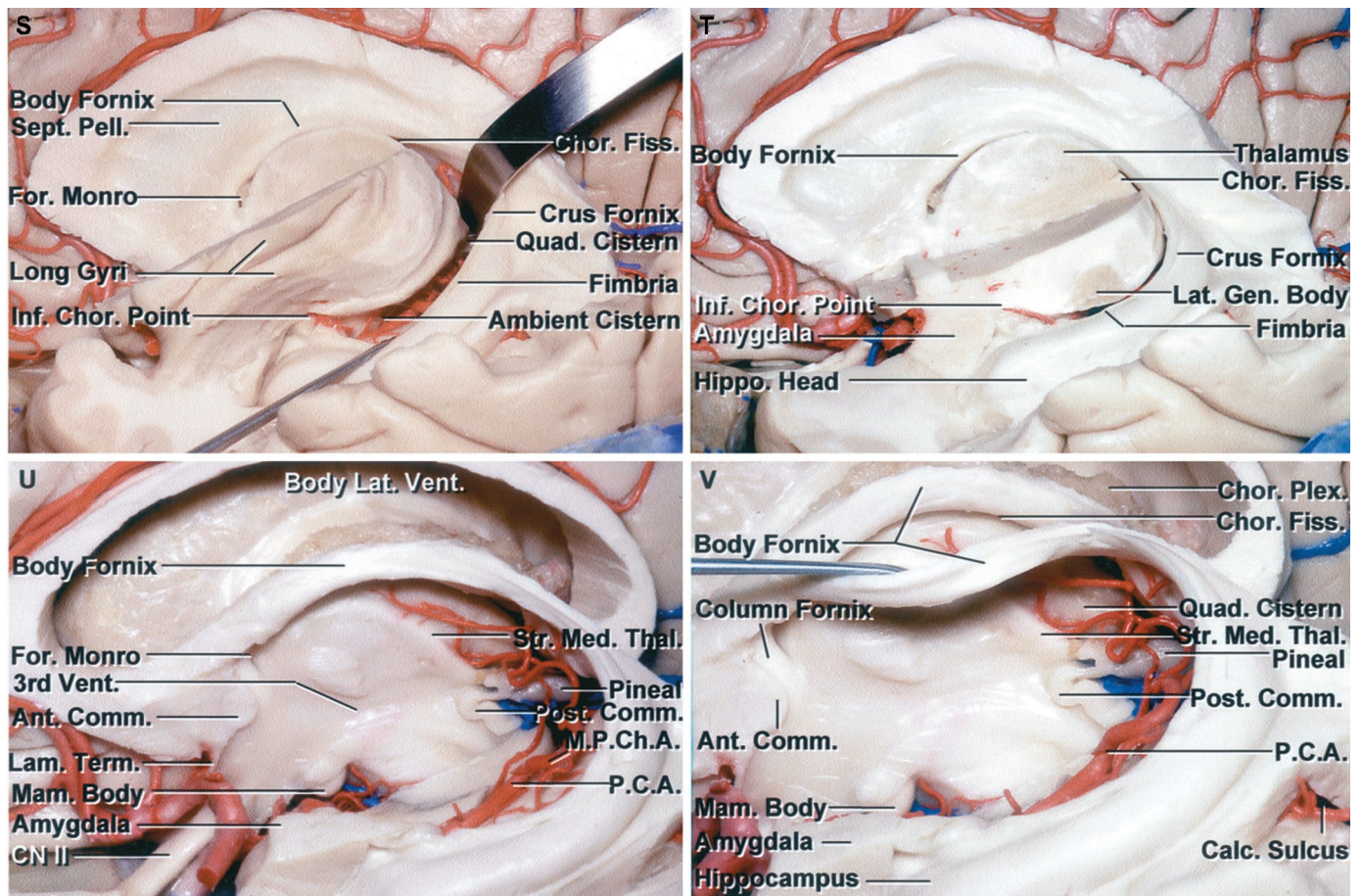


FIGURE 1.2. Continued

G, colored pins have been placed along a line that corresponds to the lower margin of the insula, which is located deep to the superior temporal sulcus. A blue arrow has been placed on the foramen of Monro, which is located deep to the central part of the insula. The white arrow is located at the site where the upper end of the ascending ramus of the cingulate sulcus reaches the superior hemispheric border. The ascending ramus courses on the medial surface along the posterior margin of the paracentral lobule. H, the anterior limb of the internal capsule is located between the lentiform nucleus, formed by the putamen and globus pallidus, and the caudate nucleus. The posterior limb is located between the thalamus and lentiform nucleus. The genu of the internal capsule is located just lateral to the foramen of Monro. The choroidal fissure, along which the choroid plexus is attached, is situated between the fornix and thalamus. I, the temporal horn and hippocampus are located medial to the middle temporal gyrus, a segment of which has been removed. The hippocampus sits in the floor of the temporal horn. The atrium is deep to the supramarginal gyrus. The black arrow is on the foramen of Monro. The white arrow is located where the upper end of the ascending ramus of the cingulate sulcus reaches the superior hemispheric border. The yellow arrow is where the upper end of the parieto-occipital sulcus reaches the superior border. J, the remaining bridge of the superior temporal gyrus located superficial to the junction of the atrium and temporal horn has been removed. K, posterior view of the left hemisphere. The splenium is located deep in the interhemispheric fissure. The parieto-occipital and calcarine sulcus converge behind the splenium to give the medial surface a Y-shaped configuration. The parieto-occipital sulcus separates the pre-cuneus and cuneus, and the calcarine sulcus separates the cuneus and lingula. L, the parietal lobe, above the level of the calcarine sulcus, has been removed. The upper lip of the calcarine sulcus, formed by the cuneus, has been removed to expose the lingula that forms the lower bank of the calcarine sulcus. The calcar avis is a prominence in the lower part of the medial atrial wall overlying the calcarine sulcus. M, the glomus of the choroid plexus has been reflected forward to expose the medial wall of the atrium. The lingula that forms the lower bank of the calcarine sulcus has been preserved. The calcar avis overlies the deep end of the calcarine sulcus. N, the falx has been removed to expose the medial part of the right hemisphere. The ascending ramus of the cingulate sulcus reaches the superior border of the hemisphere behind the paracentral lobule. O, the pre- and postcentral gyri have been removed while preserving the superior temporal gyrus. The choroidal fissure, the cleft between the thalamus and fornix, extends from the foramen of Monro through the body, atrium, and temporal horn to the inferior choroidal point located just behind the head of the hippocampus. P, superolateral view of the cross section of the central area of the hemisphere, positioned between the insula laterally and the ventricles medially. The central core of the hemisphere, the area between the insula laterally and the ventricles in the midline, includes the caudate and lentiform nucleus, thalamus, and anterior and posterior limbs and genu of the internal capsule. The claustrum is positioned between the insular cortex and the lentiform nucleus. Q, the superior temporal gyrus has been removed while preserving the long gyri of the insula. The ascending ramus of the cingulate sulcus marks the posterior edge of the paracentral lobule, the extension of the pre- and postcentral gyri onto the medial surface of the hemisphere. R, enlarged view of the choroidal fissure. The choroidal fissure extends from the foramen of Monro to the inferior choroidal point located behind the head of the hippocampus. The choroid plexus, which attaches along the choroidal fissure, has been removed. The outer edge of the choroidal fissure is formed by the body of the fornix in the body of the ventricle, the crus of the fornix in the atrium, and the fimbria of the fornix in the temporal horn. S, a retractor has been placed between the thalamus and the crus of the fornix to open the choroidal fissure. Opening the choroidal fissure in the body of the ventricle exposes the third ventricle.

convexity, faces the cranial cap laterally. The medial surface of the frontal, parietal, and occipital lobes faces the falx cerebri medially, and the medial surface of the temporal lobe faces the lateral aspect of the midbrain. The basal surface faces the floor of the anterior and middle cranial fossae and the tentorium. The three borders separate the three cerebral surfaces. The superior border follows along the course of the superior sagittal sinus and upper edge of the interhemispheric fissure from the frontal to the occipital pole and separates the lateral convexity from the medial surface. The lateral border has anterior and posterior parts. The anterior part extends from the frontal pole along the lateral border of the basal surface of the frontal lobe to the sylvian fissure and separates the lateral and orbital surfaces of the frontal lobe. The posterior part of the lateral border has a gentle upward convexity that extends along and conforms with the lateral edge of the middle fossa floor and tentorium, and anteriorly turns upward around the temporal pole to reach the sylvian fissure. It separates the lateral surface of the temporal and occipital lobes from the basal surface that rests on the cranial base and tentorium. The medial border extends from the frontal to the occipital pole and has frontal and occipital parts. The frontal part extends in a straight line from the frontal pole to the lamina terminalis and separates the medial from the orbital surface of the frontal lobe. The occipital part of the medial border lies in the angle between the falx cerebri and tentorium cerebelli and extends parallel to the straight sinus from the occipital pole to just below the splenium of the corpus callosum, separating the medial and basal surfaces of the occipital lobe.

The frontal, occipital, and temporal lobes expand to all three cerebral surfaces (Fig. 1.3). The parietal lobe borders only two surfaces, the lateral and medial. The frontal lobe includes approximately a third of the hemispheric surface. It extends from the frontal pole to the central sulcus and is separated from the temporal lobe by the sylvian fissure. On the medial surface, the frontal lobe is separated from the corpus callosum by the callosal sulcus and from the parietal lobe by a line extending downward from the upper end of the central sulcus

to the corpus callosum. The entire surface facing the orbital roof and referred to as the orbital surface belongs to the frontal lobe. The lateral surface of the parietal lobe is bounded anteriorly by the central sulcus, posteriorly by the upper half of the parietotemporal line that runs from the impression of the upper end of the parieto-occipital sulcus on the lateral surface to the preoccipital notch, and inferiorly by the posterior end of the sylvian fissure and the extended sylvian line that extends backward along the long axis of the sylvian fissure to the lateral parietotemporal line. On the medial surface, the boundary between the frontal and parietal lobes is a line extending downward from the upper end of the central sulcus to the corpus callosum. Between the parietal and occipital lobes is the parieto-occipital sulcus. The occipital lobe lies behind the parietotemporal line on the lateral surface and the parieto-occipital sulcus on the medial surface. On the basal surface, the occipital lobe is situated behind the lines extending from the junction of the calcarine and parieto-occipital sulci medially to the preoccipital notch laterally.

Boundaries and Surfaces of the Lobes

The frontal lobe presents four surfaces: three formed by a part of the lateral, medial, and basal cerebral surfaces, and a fourth sylvian surface facing the deep compartments of the sylvian fissure (Fig. 1.3). That latter surface, with the sylvian surface of the parietal lobe, forms the roof of the deep part of the sylvian fissure and faces the sylvian surface of the temporal lobe and the insula that form the floor and medial wall of the deep sylvian compartments. The temporal lobe also has four surfaces: larger lateral and basal surfaces, a smaller medial surface facing the brainstem, and a sylvian surface. The medial surface of the temporal lobe is formed by the part of the uncus, parahippocampal, and dentate gyri facing the midbrain. The upper surface of the temporal lobe forms the floor of the deep sylvian compartments and faces the sylvian surface of the frontal and parietal lobes and the insula. The parietal lobe has three surfaces: lateral, medial, and a sylvian surface that faces the sylvian surface of the temporal lobe and

Opening the choroidal fissure between the pulvina and crus of the fornix exposes the quadrigeminal cistern, and opening the fissure between the lower surface of the thalamus and the fimbria of the fornix exposes the ambient cistern. T, the remaining insula has been removed to expose the thalamus forming the inner rim of the choroidal fissure. The lateral geniculate body is exposed at the lower margin of the thalamus. The optic radiations pass laterally above the hippocampus in the roof of the temporal horn and posteriorly around the lateral margin at the atrium to reach the calcarine sulcus. The anterior wall of the temporal horn is formed by the amygdala, which tilts backward above, but is separated from the hippocampal head by the temporal horn. U, the thalamus has been removed to expose the third ventricle. The body, crus, and fimbria of the fornix, forming the outer margin of the choroidal fissure, have been preserved. Opening the choroidal fissure in front of the crus of the fornix exposes the pineal region and quadrigeminal cistern. Opening the choroidal fissure adjacent to the body of the fornix exposes the third ventricle. Opening the choroidal fissure in the temporal horn exposes the ambient cistern and posterior cerebral arteries. The medial posterior choroidal arteries are exposed in the quadrigeminal cistern. The striae medullaris thalami marks the lower edge of the velum interpositum, in which the internal cerebral veins course. V, the left half of the body of the fornix has been folded downward to expose the right half of the body and medial aspect of the contralateral choroidal fissure located between the body of the fornix and the upper surface of the thalamus. The pineal gland and posterior commissure are exposed at the posterior margin and the anterior commissure and columns of the fornix are exposed at the anterior margin of the third ventricle. A., artery; A.C.A., anterior cerebral artery; Ang., angular; Ant., anterior; Asc., ascending; Calc., calcar, calcarine; Call., callosum; Caud., caudate; Cent., central; Chor., choroid, choroidal; Cing., cingulate; Circ., circular; CN, cranial nerve; Comm., commissure; Corp., corpus; Fiss., fissure; For., foramen; Front., frontal; Gen., geniculate; Glob., globus; Hippo., hippocampal; Inf., inferior; Intrapar., intraparietal; Lam., lamina; Lat., lateral; Lent., lenticular, lentiform; Lob., lobule; M.P.Ch.A., medial posterior choroidal artery; Mam., mamillary; Med., medullaris; Mid., middle; Nucl., nucleus; Occip., occipital; Operc., opercularis; Orb., orbital; P.C.A., posterior cerebral artery; Pall., pallidus; Par., parietal; Paracent., paracentral; Par. Occip., parieto-occipital; Pell., pellucidum; Plex., plexus; Post., posterior; Post-cent., postcentral; Precent., precentral; Quad., quadrigeminal; Sept., septum; Str., striae; Sup., superior; Supramarg., supramarginal; Temp., temporal; Term., terminalis; Thal., thalamic, thalamus; Triang., triangularis; Vent., ventricle.

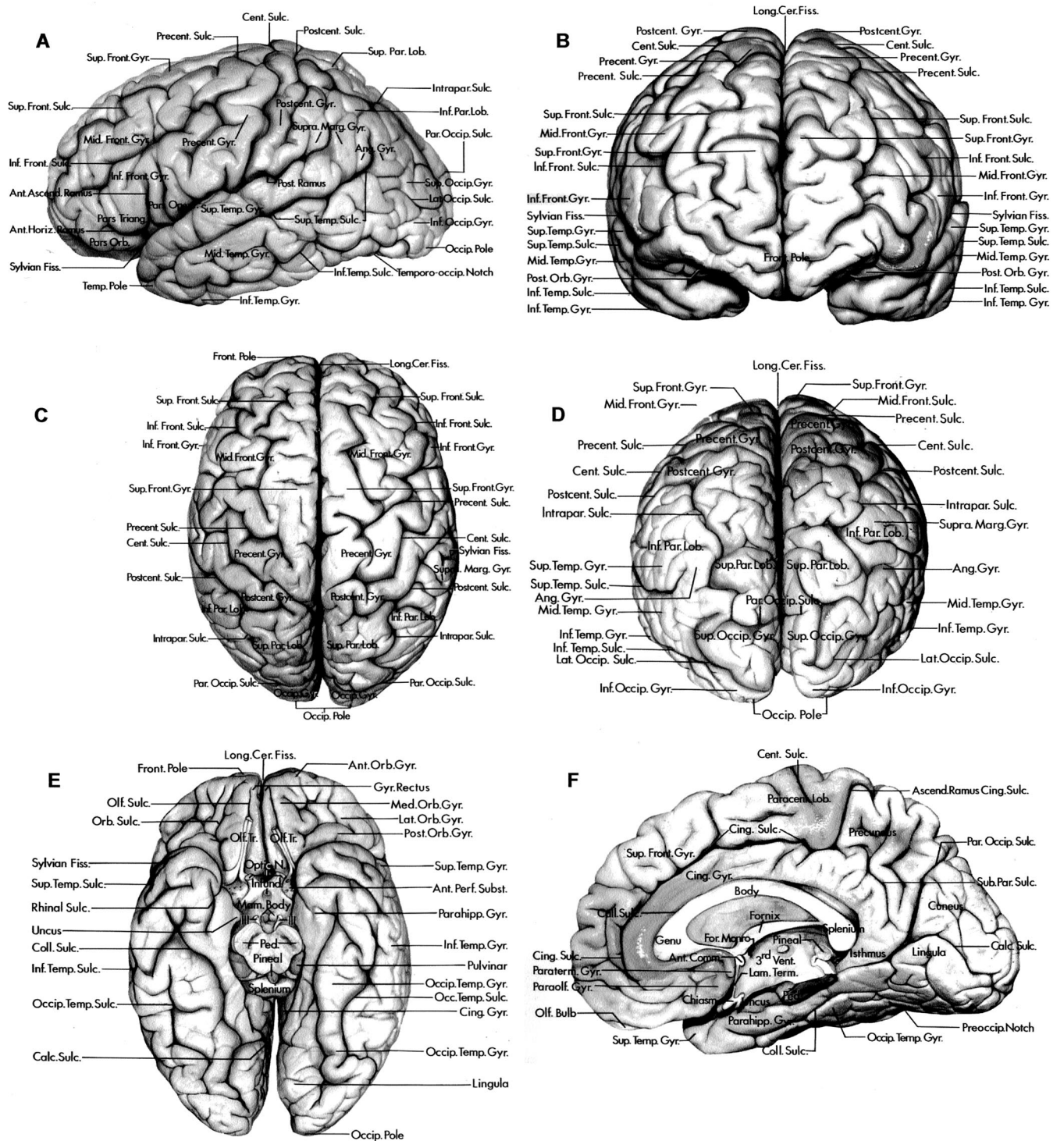


FIGURE 1.3. Lateral, medial, and inferior surfaces of the cerebral hemispheres. A–D, lateral surface (A, lateral view; B, anterior view; C, superior view; D, posterior view). E, inferior surface. F, medial surface. A–F, the longitudinal cerebral fissure separates the cerebral hemispheres. The lateral surface of the frontal lobe extends from the frontal pole to the central sulcus and is demarcated inferiorly by the sylvian fissure. The precentral gyrus is situated between the central and precentral sulcus. The superior and inferior frontal sulci divide the part of the lateral surface in front of the precentral gyrus into the superior, middle, and inferior frontal gyri. The inferior frontal gyrus is divided by the anterior horizontal and the anterior ascending rami of the sylvian fissure into the pars orbitalis, pars triangularis, and pars opercularis. The parietal lobe is demarcated anteriorly by the central sulcus and posteriorly by a line extending from the superior limit of the parieto-occipital sulcus to the preoccipital notch. The anterior part of the parietal lobe is formed by the postcentral gyrus, which is situated between the central and postcentral sulci.

the insula. The occipital lobe has three surfaces: lateral, medial, and basal, all formed by parts of the cerebral surfaces.

Sulci and Gyri

Although differences in the gyri and sulci can be identified between any two hemispheres, close inspection reveals a basic arrangement within which variations exist. The differences in the course and pattern of the sulci and gyri exist not only from person to person, but also between the hemispheres of the same brain. The greatest variability can be seen in the frontal and parieto-occipital regions (3). Commonly, the major sulci are discontinuous or have small side branches that create a significant variation in the shape and pattern of the gyri. Ono et al. (3) have classified the cerebral sulci into three groups based on their degree of continuity: the first group are those that are commonly continuous or uninterrupted; the second group are those that have low interruption rates; and the third group are those that are regularly interrupted. In our studies, the sulci that were uniformly continuous, not broken into several segments by gyral bridges crossing the sulcus, were the sylvian fissure and the callosal and parieto-occipital sulci. Another group that has a high, but not 100%, rate of continuity are the central, collateral, and calcarine sulci. Those sulci that are less commonly but still regularly interrupted are the postcentral, superior, and inferior frontal, superior temporal, cingulate, occipitotemporal, and the intraparietal sulci. Those that are usually interrupted by gyral bridges that break up their continuity are the precentral and inferior temporal sulci.

SYLVIAN FISSURE

The sylvian fissure and central sulcus are the most important landmarks on the lateral surface. The sylvian fissure is the most distinct and consistent landmark on the lateral surface. It

is a complex fissure that carries the middle cerebral artery and its branches and provides a surgical gateway connecting the cerebral surface to the anterior part of the basal surface and cranial base (1).

The sylvian fissure is not a simple longitudinal cleft as its name implies (Fig. 1.4). It crosses both the basal and lateral cerebral surface and has a superficial and a deep part. The superficial part is visible on the surface of the brain and the deep part, often referred to as the sylvian cistern, is hidden below the basal surface. The superficial part has a stem and three rami; the stem begins medially at the anterior clinoid process and extends laterally along the sphenoid ridge between the junction of the frontal and temporal lobes to the pterion, where the stem divides into anterior horizontal, anterior ascending, and the posterior rami. The posterior ramus, the longest, represents the posterior continuation of the fissure. It is directed backward and upward, separating the frontal and parietal lobes above from the temporal lobe below. Its posterior end turns more sharply upward to terminate in the inferior parietal lobule, where the supramarginal gyrus wraps around its upturned posterior end.

The deep part of the sylvian fissure, hidden below the surface, is referred to as the sylvian cistern. It is more complex than the superficial part and is divided into sphenoidal and opercular compartments. The sphenoidal compartment extends laterally from the cistern around the internal carotid artery, between the frontal and temporal lobes. The roof of the sphenoidal compartment is formed by the posterior part of the orbital surface of the frontal lobe and the anterior perforated substance. The caudate and lentiform nuclei and the anterior limb of the internal capsule are located above the roof. The floor is formed by the anterior part of the planum polare, an area free of gyri on the upper temporal pole, where a shallow cupped trench accommo-

←

The area behind the postcentral sulcus is divided by the intraparietal sulcus into the superior and inferior parietal lobules. The inferior parietal lobule includes the supramarginal gyrus, which surrounds the upturned end of the posterior ramus of the sylvian fissure, and the angular gyrus, which surrounds the upturned posterior end of the superior temporal sulcus. The lateral occipital sulcus divides the lateral aspect of the occipital lobe into the superior and inferior occipital gyri. The lateral surface of the temporal lobe behind the temporal pole is divided into the superior, middle, and inferior temporal gyri by the superior and inferior temporal sulci. The inferior surface of the frontal lobe is formed by the gyrus rectus and the orbital gyri. The olfactory tract courses in the olfactory sulcus, which separates the gyrus rectus from the orbital gyri. The orbital sulci divide the orbital surface of the frontal lobe into the anterior, medial, lateral, and posterior orbital gyri. The inferior surface of the temporal lobe, proceeding from medial to lateral, is formed by the parahippocampal, occipitotemporal, and inferior temporal gyri. The occipitotemporal sulcus separates the occipitotemporal and inferior temporal gyri. The collateral and rhinal sulci separate the parahippocampal and occipitotemporal gyri. A narrow strip of cortex at the posterior end of the parahippocampal gyrus, called the isthmus of the cingulate gyrus, wraps around the splenium of the corpus callosum and connects the posterior ends of the parahippocampal and cingulate gyri. On the medial surface of the hemisphere, the callosal sulcus separates the corpus callosum from the cingulate gyrus. The cingulate sulcus separates the cingulate gyrus from the superior frontal gyrus. The ascending ramus of the cingulate sulcus ascends along the posterior margin of the paracentral lobule. The subparietal sulcus separates the precuneus and the cingulate gyrus. The parieto-occipital sulcus separates the precuneus and the cuneus. The calcarine sulcus extends forward from the occipital pole and divides the medial surface of the occipital lobe between the cuneus and lingula. The paraterminal and paraolfactory gyri are situated below the corpus callosum in front of the lamina terminalis and anterior commissure. The inferior surface of the occipital lobe is formed by the lower part of the lingula and inferior occipital gyrus and the posterior part of the occipitotemporal gyrus. The mamillary bodies and infundibulum are in the floor of the third ventricle below the foramen of Monro. The oculomotor nerves arise on the medial surface of the cerebral peduncles. The optic nerves are situated at the medial ends of the sylvian fissures. Ang., angular; Ant., anterior; Ascend., ascending; Calc., calcarine; Cent., central; Cer., cerebral; Cing., cingulate; Coll., collateral; Comm., commissure; Fiss., fissure; For., foramen; Front., frontal; Gyr., Gyrus; Horiz., horizontal; Inf., inferior; Infund., infundibulum; Intrapar., intraparietal; Lam., lamina; Lat., lateral; Lob., lobule; Long., longitudinal; Mam., mamillary; Marg., marginal; Med., medial; Mid., middle; N., nerve; Occip., occipital; Olf., olfactory; Operc., opercularis; Orb., orbital; Par., parietal; Par. Occip., parieto-occipital; Paracent., paracentral; Parahipp., parahippocampal; Paraolf., paraolfactory; Paraterm., paraterminal; Ped., peduncle; Perf., perforated; Post., posterior; Postcent., postcentral; Precent., precentral; Preoccip., preoccipital; Sub. Par., subparietal; Subst., substance; Sulc., sulcus; Sup., superior; Supra. Marg., supramarginal; Temp., temporal; Temporo-occip., temporo-occipital; Term., terminalis; Tr., tract; Triang., triangularis; Vent., ventricle.

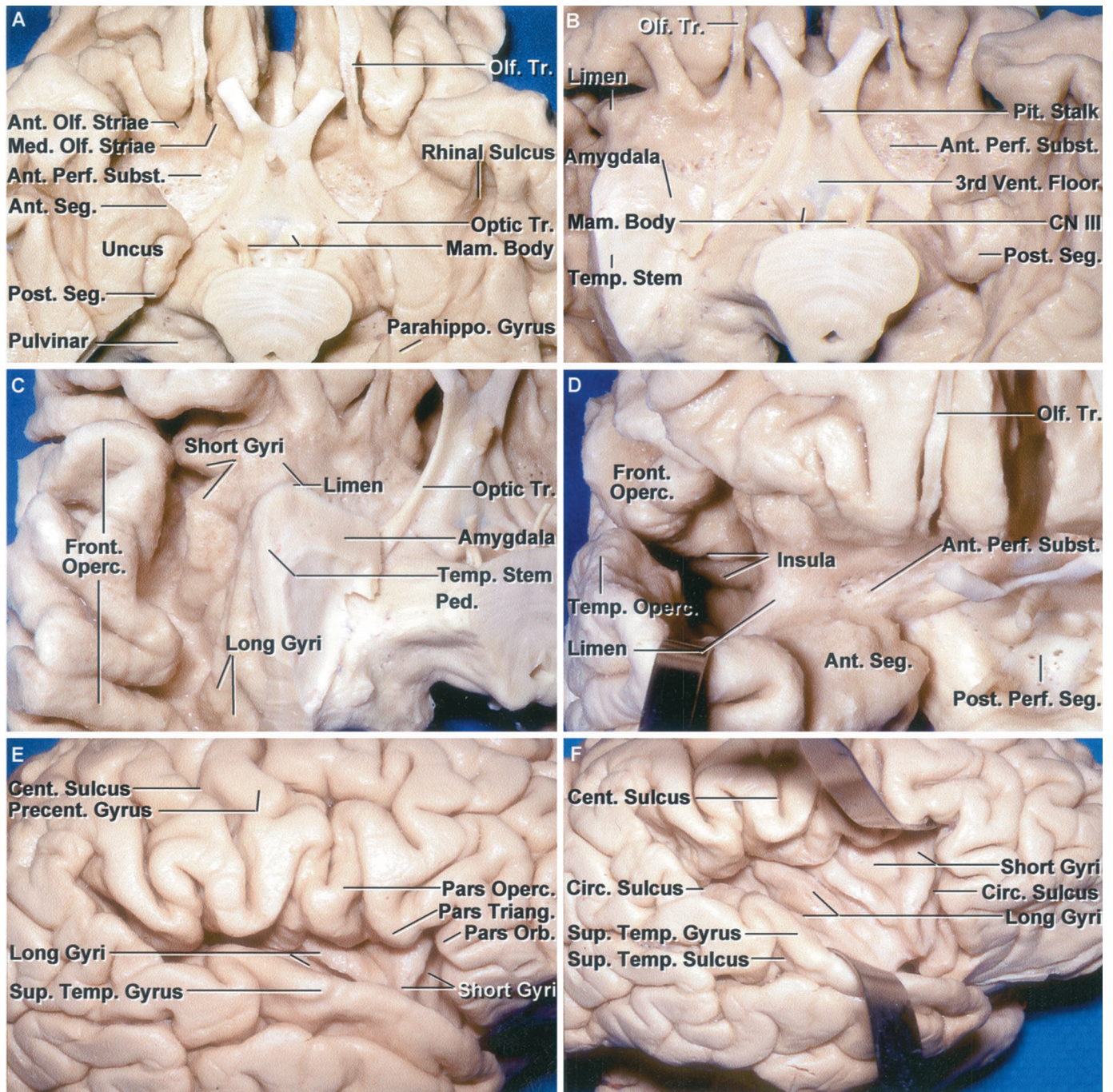


FIGURE 1.4. Anterior perforated substance and sylvian fissure. A, inferior view. The anterior perforated substance forms of the roof of the sphenoidal compartment of the sylvian fissure. It extends from the olfactory striae anteriorly to the optic tract and stem of the temporal lobe posteriorly. On the medial side, it extends to the interhemispheric fissure and laterally to the limen insula. The anterior uncus segment faces the anterior perforated substance. The posterior segment faces the cerebral peduncle. B, the right temporal pole has been removed down to the level of the stem of the temporal lobe that forms the posterolateral margin of the anterior perforated substance. The limen insula is situated at the lateral margin of the anterior perforated substance anterior to the stem of the temporal lobe. On the left side, the lower part of the posterior uncus segment has been removed to expose the upper part formed largely by the hippocampal head. The anterior perforated substance has a salt-and-pepper appearance, created by small openings through which the perforating arteries and veins penetrate the hemisphere. The area where a third ventriculostomy is performed is located in front of the mammillary bodies. C, the view has been directed lateral to the limen to the insula and frontal operculum. The lower ends of the short and long gyri of the insula are exposed lateral to the stem of the temporal lobe and medial to the gyri on the frontal operculum. D, anterior view with the lips of the opening into the operculoinsular component of the sylvian fissure retracted. The sylvian fissure, lateral to the limen, extends backward and upward, and between the insula medially and the frontal and temporal opercula laterally.

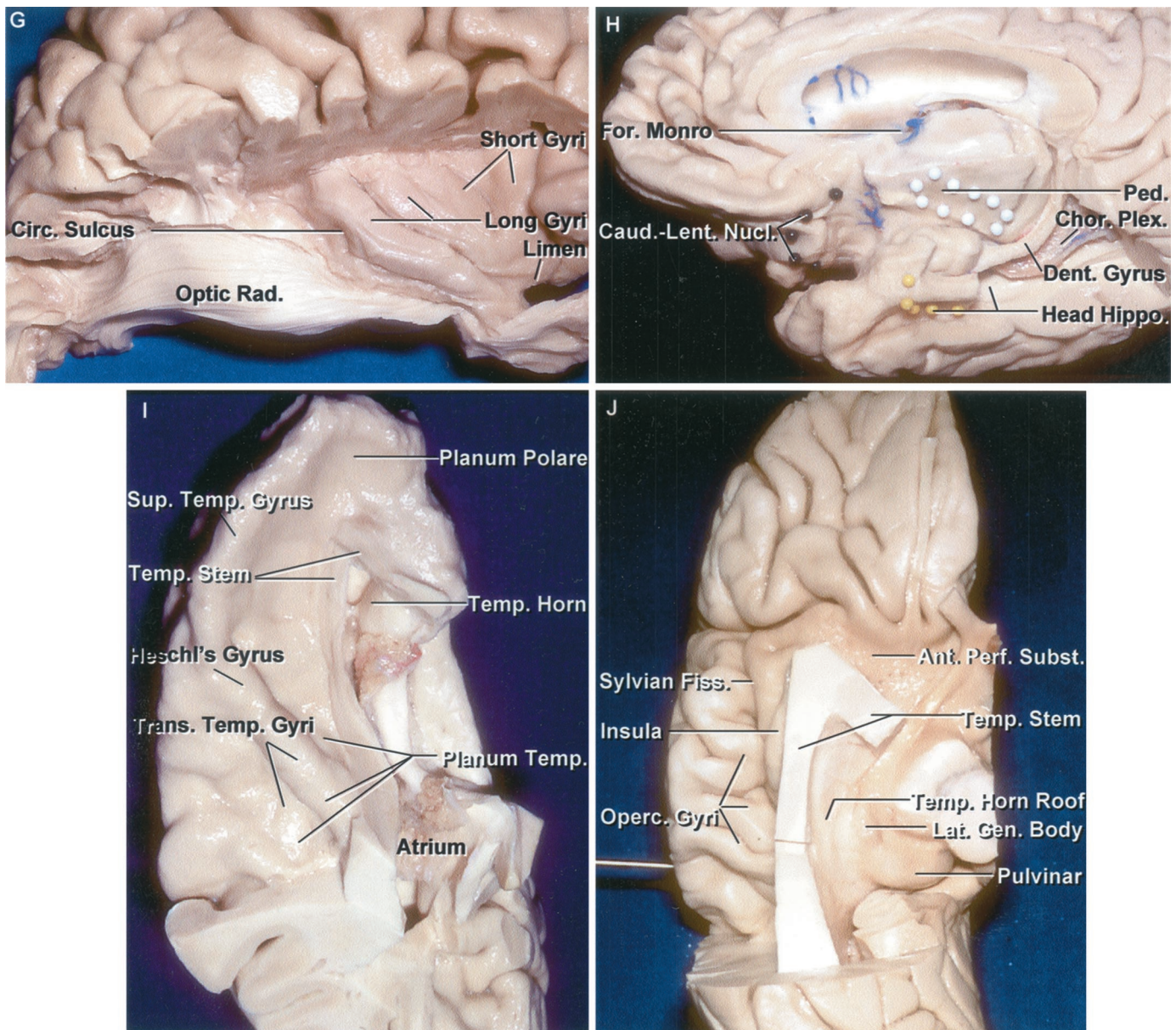


FIGURE 1.4. Continued

The posterior perforated substance is located between the cerebral peduncles. E, lateral view of the right hemisphere. In this hemisphere, the frontal and parietal opercula do not meet the temporal operculum, thus exposing the inferior part of the long and short gyri of the insula. F, the opercular lips have been retracted to expose the long and short gyri of the insula and the circular sulcus at the outer insular border. G, the temporal lobe has been removed and the optic radiations preserved. The lower margin of the insula is located superficially at approximately the deep level of the lateral geniculate body. The fibers of the optic radiation pass through the stem of the temporal lobe on their way back to the calcarine sulcus. H, inferomedial view of the basal frontal and medial temporal lobes. The white dots outline the fibers descending to form the cerebral peduncle. Black pins outline the deep position of the caudate and lentiform nuclei above the anterior perforated substance and basal surface of the frontal lobe. The yellow pins outline the anterior margin of the head of the hippocampus. The posterior part of the head of the hippocampus has been exposed by removing the medial part of the parahippocampal gyrus. I, superior view of the upper surface of the temporal lobe that forms the floor of the sylvian fissure. The transverse temporal gyri, the most anterior of which is Heschl's auditory projection area, form the posterior part of the upper surface of the temporal lobe, called the planum temporale. The anterior part of the upper surface, called the planum polare, is free of gyri and has a shallow trough to accommodate the course of the middle cerebral artery. The lateral edge of the planum polare is formed by the superior temporal gyrus. The stem of the temporal lobe, the relatively thin layer of white and gray matter that connects the temporal lobe to the lower insula, is positioned above the lateral and anterior edge of the temporal horn. J, inferior view of the frontoparietal operculum. The gyri on the lateral surface extend around the lower border of the frontal and parietal lobes to form the upper lip of the sylvian fissure. The optic radiations pass laterally from the lateral geniculate body and course in the roof of the temporal horn along the temporal stem and lateral to the atrium to reach the calcarine sulcus on the medial aspect of the occipital lobe. Ant., anterior; Caud., caudate; Cent., (Legend continues on next page.)

dates the course of the middle cerebral artery. The anterior segment of the uncus, the site of the amygdala, is located at the medial part of the floor. The limen insulae, the prominence overlying the cingulum, a prominent fiber bundle connecting the frontal and temporal lobes, is located at the lateral edge of the sphenoidal compartment. This compartment communicates medially through the sylvian vallicula, a tubular opening between the medial end of the opposing temporal and frontal lips of the fissure, through which the middle cerebral artery passes and provides a communication between the sylvian fissure and the cisterns around the optic nerve and carotid artery.

The operculoinsular compartment is formed by two narrow clefts: opercular and insular (*Fig. 1.4*). The opercular cleft is situated where the sylvian surfaces of the frontal lobe, and the parietal lobes above, face the sylvian surface of the temporal lobe below. The deep part of the surfaces of the three lobes that face each other across the opercular cleft are also oriented so that they come to face the lateral surface of the insula. The insular cleft has a superior limb, located between the insula and the opercula of the frontal and parietal lobes, and an inferior limb, located between the insula and the temporal operculum (*Fig. 1.4*) (1). Anteriorly, the superior limb has a greater vertical height than the inferior limb, but posteriorly, the height of the inferior limb is the same as or greater than the height of the superior limb. The upper lip of the opercular cleft is formed by the gyri of the frontal and parietal lobes that continue medially around the upper edge of the fissure to form the roof of the sylvian cistern and are, from anterior to posterior, the pars orbitalis, triangularis, and opercularis, and the precentral, postcentral, and supramarginal gyri (*Fig. 1.4, C and J*). The lower lip of the opercular cleft is formed, from posterior to anterior, by the planum temporale, composed of the transverse temporal gyri the most anterior and longest of which is Heschl's gyrus, and the part of the planum polare lateral to the insula (*Fig. 1.4I*). Heschl's gyrus and the adjoining part of the superior temporal gyrus serve as the primary auditory receiving area. The posterior edge of the insular surface approximates the position of the posterior edge of the pulvinar at a deeper level. The transverse temporal gyri seem to radiate anterolaterally from the posterior insular margin, widening as they progress toward the cortical surface. The plenum temporale has a more horizontal orientation than the plenum polare, which, from lateral to medial, slopes downward and conforms more to the convexly rounded insular surface.

The medially directed arterial apex, created by the most posterior middle cerebral artery branch turning sharply away from the insula, called the sylvian point, points medially toward the atrium, just as does the medial apex of the posterior convergence of the transverse temporal gyri. Each gyrus of the frontoparietal opercula faces and rests in close proximity to its counterpart on the temporal side. The supramarginal gyrus

faces the gyri forming the posterior part of the planum temporale, the postcentral gyrus faces Heschl's gyrus, and the precentral gyrus and the pars opercularis, triangularis, and orbitalis are related to the lateral edge of the planum polare formed by the upper edge of the superior temporal gyrus. The site on the posterior ramus of the sylvian fissure, where the postcentral gyrus meets the Heschl's gyrus, is projected in the same coronal plane of the external acoustic meatus.

The medial wall of the sylvian fissure, formed by the insula, is seen only when the lips of the sylvian fissure are widely separated, except in the area below the inferior angle of the pars triangularis, which is often retracted upward to expose a small area of the insular surface (*Fig. 1.4*). The natural upward retraction of the apex of the pars triangularis commonly creates the largest opening in the superficial compartment of the sylvian fissure and provides an area on the convexity where the sylvian fissure is widest, and where it is often safest to begin opening the fissure. The apex of the pars triangularis is sited directly lateral to the antero-inferior part of the circular sulcus and the anterior limit of the basal ganglia.

Anterior Perforated Substance

The anterior perforated substance is a flat, smooth, area of gray matter located in the roof of the sphenoidal compartment of the sylvian fissure (*Fig. 1.4*). It is named for the numerous minute orifices created by numerous perforating arteries from the internal carotid, anterior choroidal, and anterior and middle cerebral arteries penetrating its surface to reach the basal ganglia, anterior portion of the thalamus, and the anterior limb, genu, and posterior limb of the internal capsule. It is also the exit site for the inferior striate veins.

The anterior perforated substance is a rhomboid-shaped area buried deep in the roof of the stem of the sylvian fissure. It is bounded anteriorly by the medial and lateral olfactory striae, posterolaterally by the stem of the temporal lobe, laterally by the limen insulae, and posteromedially by the optic tract. Medially, the anterior perforated substance extends above the optic chiasm to the anterior edge of the interhemispheric fissure. The frontal horn, the caudate head, the anterior part of the lentiform nucleus, and the anterior limb of the internal capsule are located above the anterior perforated substance. Just as the insula can be understood as the outer covering of the internal capsule, basal ganglia, and thalamus, the anterior perforated substance can be seen as the "floor" of the anterior half of the basal ganglia. The anterior perforated substance is where the basal ganglia reach the brain's surface.

FIGURE 1.4. Continued

central; Chor., choroid, choroidal; Circ., circular; CN, cranial nerve; Dent., dentate; Fiss., fissure; For., foramen; Front., frontal; Gen., geniculate; Hippo., hippocampus; Lat., lateral; Lent., lentiform, lenticular; Mam., mamillary; Med., medial; Nucl., nucleus; Olf., olfactory; Operc., operculum, opercularis; Orb., orbitalis; Parahippo., parahippocampal; Ped., peduncle; Perf., perforated; Pit., pituitary; Plex., plexus; Post., posterior; Precent., precentral; Rad., radiations; Seg., segment; Subst., substance; Sup., superior; Temp., temporal, temporale; Tr., tract; Trans., transverse; Triang., triangularis; Vent., ventricle.

Insula

The insula has a triangular shape with its apex directed anterior and inferiorly toward the limen insulae, a slightly raised area overlying the uncinate fasciculus, covered by a thin layer of gray matter, at the lateral border of the anterior perforated substance (Figs. 1.2 and 1.4). The limen is located at the junction of the sphenoidal and operculoinsular compartments of the sylvian fissure. The insula is encircled and separated from the frontal, parietal, and temporal opercula by a shallow limiting sulcus. The limiting sulcus, although roughly triangular in shape to conform to the shape of the insula, is commonly referred to as the circular sulcus because it encircles the insula. The sulcus has three borders: superior, inferior, and anterior; and three angles: anteroinferior, anterosuperior, and posterior where the borders join. The anterior border is located deep to the pars triangularis of the inferior frontal gyrus; the superior or upper border is nearly horizontal and separates the upper border of the insula and the sylvian surface of the frontal and parietal lobes; and the inferior or lower border is directed anteroinferiorly from the posterior apex and separates the insula from the sylvian surface of the temporal lobe. The anteroinferior angle, referred to as the insular apex, is located below the apex of the pars triangularis; the anterosuperior angle is located deep to the upper anterior edge of the pars triangularis; and the posterior angle is located deep to where the supramarginal gyrus wraps around the posterior end of the sylvian fissure. The anterosuperior angle is located directly lateral to the frontal horn and the posterior angle is located lateral to the atrium and corresponds to the sylvian point, the site at which the most posterior branch of the insular segment of the middle cerebral artery turns laterally between the opercular lips to reach the cortical surface, and the antero-inferior angle points to the lateral edge of the anterior perforated substance.

The sulci and gyri of the insula are directed superiorly and posteriorly in a radial manner from the apex at the limen insulae. The deepest sulcus, the central sulcus of insula, is a relatively constant sulcus that extends upward and backward across the insula, nearly parallel and deep to the central sulcus on the convexity. It divides the insula into a large anterior part that is divided by several shallow sulci into three to five short gyri, and a posterior part that is formed by the anterior and posterior long gyri. The insula covers the lateral surface of the central core of the hemispheric core formed by the extreme, external, and internal capsules, claustrum, lentiform (putamen plus globus pallidus), and caudate nuclei, and thalamus. It is approximately coextensive with the claustrum and putamen.

The upper margin of the insula is located superficial to the midlevel of the body and head of the caudate nucleus. The posterosuperior angle of the insula, the site of the sylvian point, is situated superficial to the anterior margin of the upper part of the atrium where the crus of the fornix wraps around the pulvinar. The majority of the atrium is located behind the level of the posterosuperior part of the circular sulcus. A surface landmark paralleling the lower border of the insula is the superior temporal sulcus, and a deep landmark

paralleling the lower border is the optic tract coursing in the roof of the ambient cistern near the midline.

SULCI AND GYRI

Central Sulcus

The central sulcus, which separates the motor and sensory areas and the frontal and parietal lobes, follows in constancy after the sylvian fissure (Figs. 1.1–1.3 and 1.5). It begins at the superior border of the lateral surface extending onto the medial surface of the hemisphere in nearly 90% of cases. It intersects the upper hemispheric border approximately 2 cm behind the midpoint between the frontal and occipital poles. Below, it usually ends approximately 2.0 to 2.5 cm behind the anterior ascending ramus of the sylvian fissure without intersecting the sylvian fissure. From its upper end, it is directed laterally, inferiorly, and anteriorly, forming an angle of approximately 70 degrees with the anterior portion of the superior border of the hemisphere. It has two somewhat sinusoidal curves, the superior curve, or genu, has its convexity directed posteriorly, and an inferior curve, or genu, that is convex anteriorly, and together they resemble the shape of an inverted letter S (8). The upper genu is more well defined than the lower. The inferior end of the central sulcus often does not reach the sylvian fissure because a small gyral bridge frequently connects the lower ends of the precentral and postcentral gyri. Irregular limbs of the pre- and postcentral sulci may open into the central sulcus, in which case the pre- and postcentral gyri are divided into upper and lower or multiple segments.

The precentral gyrus, located between the central and precentral sulci, begins at the medial surface of the cerebrum, above the level of the splenium of the corpus callosum, and runs medially to laterally and posteriorly to anteriorly. It is positioned lateral to the following deep structures: body of the lateral ventricle, thalamus, posterior limb of the internal capsule, posterior part of the lentiform nucleus, and the midportion of the insula, to reach the sylvian fissure.

Lateral Convexity

The frontal, parietal, temporal, and occipital lobes contribute to the lateral convexity.

Frontal Lobe

The frontal lobe includes approximately a third of the hemispheric surface (Figs. 1.3, 1.5, and 1.6). The lateral surface of the frontal lobe is bounded behind by the central sulcus and above by the superior hemispheric border. The lower border has an anterior part, the superciliary border, that faces the orbital roof, and a posterior part, the sylvian border, that faces the temporal lobe across the sylvian fissure. The lateral surface is traversed by three sulci, the precentral and the superior and inferior frontal sulci, that divide it into one vertical gyrus and three horizontal gyri. The precentral gyrus, the vertical gyrus, parallels the central sulcus and is bounded behind by the central sulcus and in front by the precentral sulcus. The sur-

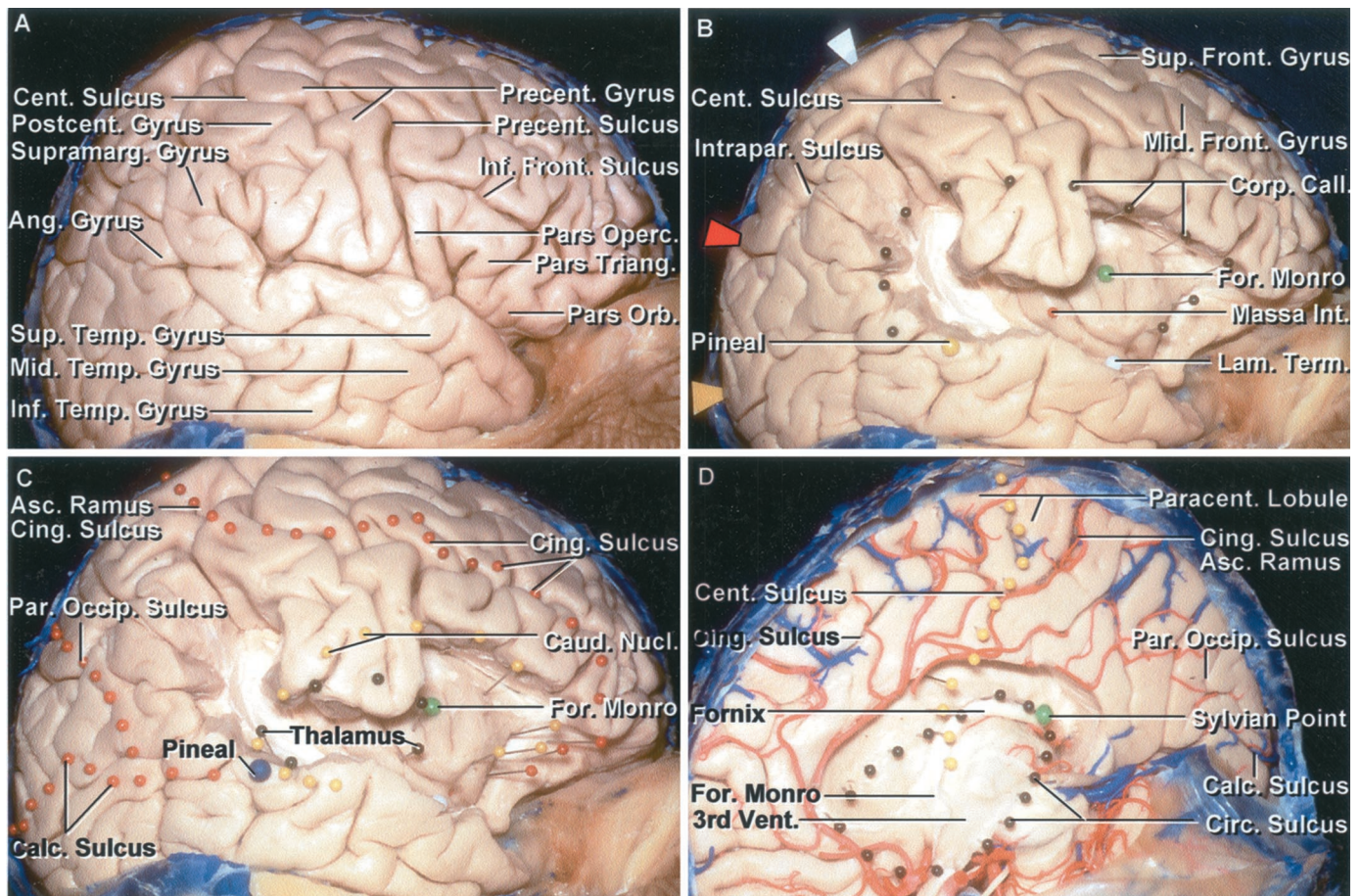


FIGURE 1.5. Relationships between the medial and lateral surface. A, lateral view, right cerebrum. The inferior frontal gyrus is formed by the pars orbitalis, triangularis, and opercularis. The pre- and postcentral gyri are located between the pars opercularis anteriorly and supramarginal gyrus posteriorly. The precentral gyrus is broken into two gyral strips. B, the pars opercularis, triangularis, and orbitalis, and the superior temporal gyrus and part of the supramarginal gyrus have been removed to expose the insula. A number of pins have been placed on the cortical surface to identify the deep location of various structures: the green pin indicates the foramen of Monro; the red pin, the massa intermedia; yellow pin, the pineal gland; white pin, the lamina terminalis. The ovoid group of dark pins identifies the outer margin of the corpus callosum. The arrows along the posterior half of the superior margin identify the site at which sulci on the medial surface intersect the superior margin as follows: white arrow, the ascending (marginal) ramus of cingulate sulcus that marks the posterior edge of the paracentral lobule; red arrow, the parieto-occipital sulcus; and yellow arrow, the calcarine sulcus. C, red pins have been placed on the convexity directly lateral to the course of the calcarine and parieto-occipital sulci and the cingulate sulcus and its ascending ramus on the medial surface. The ascending ramus of the cingulate sulcus extends along the posterior edge of the paracentral lobule formed by the upper end of the pre- and postcentral gyrus overlapping onto the medial surface of the hemisphere. The parieto-occipital and calcarine sulci on the medial surface converge and join in a Y-shaped configuration. Small black pins outline the thalamus. The yellow pins outline the outer margin of the caudate nucleus. The large blue pinhead is located at the level of the pineal, and the green pin is located directly lateral to the foramen of Monro. D, medial surface of the same hemisphere. The yellow pins mark the location of the central sulcus. The lower end of the central sulcus is located just behind the foramen of Monro as is also shown in B and C. The dark pins outline the circular sulcus of the insula. The green pin is positioned at the Sylvian point where the last branch of the middle cerebral artery turns laterally from the surface of the insula to reach the cortical surface. Ang., angular; Asc., ascending; Calc., calcarine; Call., callosum; Caud., caudate; Cent., central; Cing., cingulate; Circ., circular; Corp., corpus; For., foramen; Front., frontal; Inf., inferior; Int., intermedia; Intrapar., intraparietal; Lam., lamina; Mid., middle; Nucl., nucleus; Operc., opercularis; Orb., orbitalis; Par. Occip., parieto-occipital; Paracent., paracentral; Postcent., postcentral; Precent., precentral; Sup., superior; Supramarg., supramarginal; Temp., temporal; Term., terminalis; Triang., triangularis; Vent., ventricle.

face in front of the precentral sulcus is divided by two sulci, the superior and inferior frontal sulci, that nearly parallel the superior border and divide the area into three roughly horizontal convolutions, the superior, middle, and inferior frontal gyri. The inferior frontal convolution, situated between the Sylvian fissure and the inferior frontal gyrus, is divided, from

anterior to posterior, into the pars orbitalis, pars triangularis, and pars opercularis by the anterior horizontal and anterior ascending rami of the Sylvian fissure. The middle frontal gyrus is located between the inferior and superior frontal sulci, and the superior frontal gyrus is situated between the superior frontal sulcus and the superior margin of the hemi-

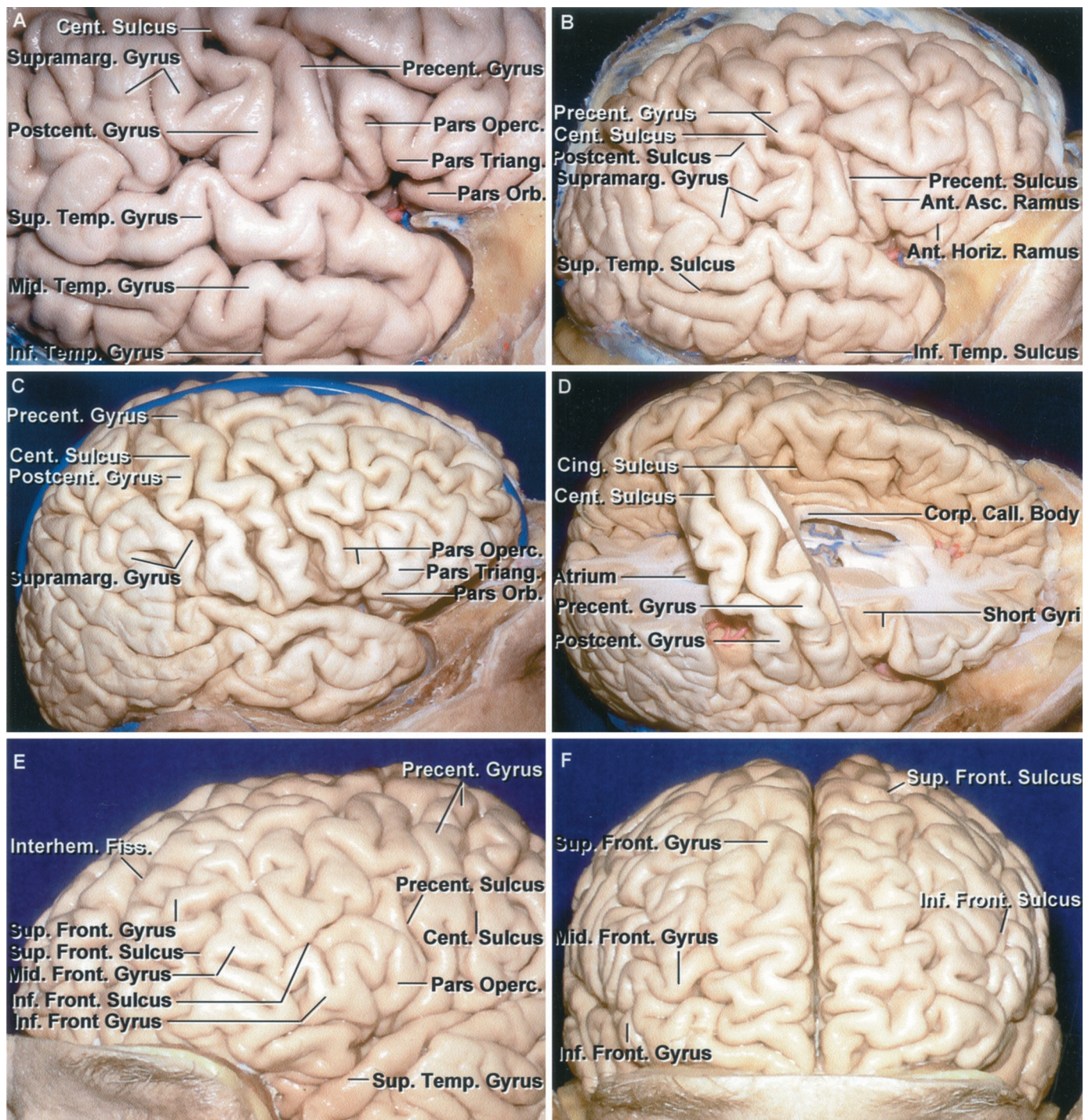


FIGURE 1.6. Identification of the pre- and postcentral gyri and variations in the frontal and temporal lobe. A, right frontotemporal area adjoining the Sylvian fissure. This is the area that would be exposed in a sizable frontotemporal craniotomy. The limited exposure may make it difficult to determine the site of the central sulcus and the precentral and postcentral gyri. Usually, the pre- and postcentral gyri can be located by examining the gyral pattern along the upper lip of the Sylvian fissure. From anteriorly, the pars orbitalis, triangularis, and opercularis can be identified. The precentral gyrus is usually located at the posterior margin of the pars opercularis. The Sylvian fissure also can be followed backward to its upturned posterior end that is capped by the supramarginal gyrus. Usually, the postcentral gyrus is the next gyrus along the Sylvian fissure anterior to the supramarginal gyrus. B, overview of the right hemisphere shown in A. The central sulcus can be followed to the superior margin of the hemisphere. The precentral gyrus is broken up into several segments by crossing sulci. The relationships of the pars opercularis to the precentral gyrus and the supramarginal gyrus to the postcentral gyrus are quite consistent and are helpful in identifying the central sulcus and the pre- and postcentral gyri during the limited operative (Legend continues on next page.)

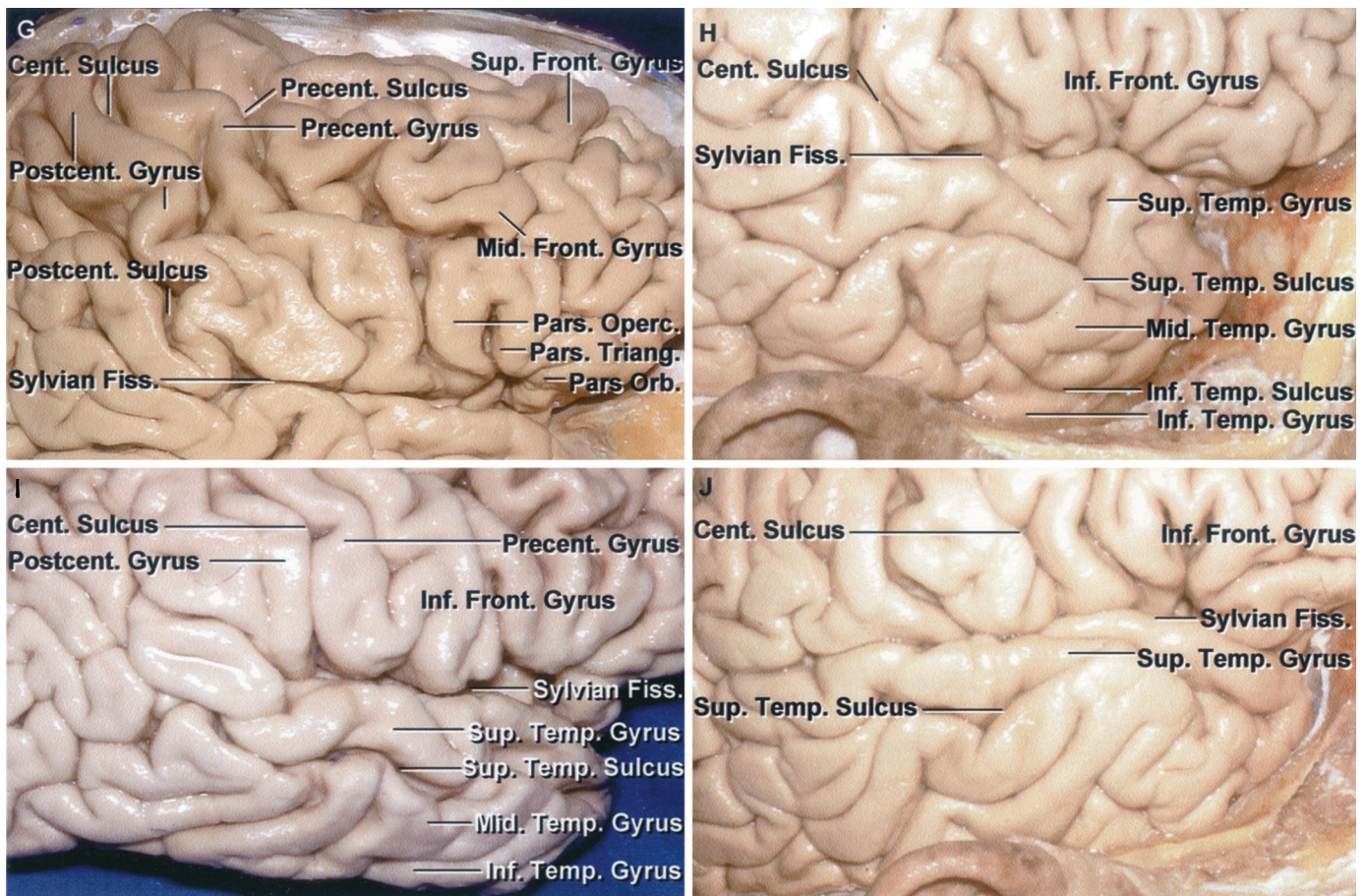


FIGURE 1.6. Continued

exposures along the Sylvian fissure. The anterior horizontal ramus of the Sylvian fissure separates the pars orbitalis and triangularis and the anterior ascending ramus separates the pars triangularis and opercularis. C, another right hemisphere. The lower end of the precentral gyrus is located behind a somewhat lobulated pars opercularis. The postcentral gyrus is located at the anterior edge of the supramarginal gyrus, which wraps around the upturned posterior end of the Sylvian fissure. D, the part of the right frontal and parietal lobes in front of and behind the pre- and postcentral gyri and central sulcus has been removed. The precentral gyrus is located lateral to the posterior part of the body of the ventricle. The postcentral gyrus is located lateral to the anterior part of the atrium. Both gyri adjoining the Sylvian fissure are positioned lateral to the splenium of the corpus callosum. E–G, sulci and gyri of the frontal lobe. E, superolateral view of the left frontal lobe. The frontal lobe is often depicted as being split into three gyri, superior, middle, and inferior, by two sulci, superior and inferior. Often, as shown, the superior frontal gyrus is split into medial and lateral segments by irregular sulci and gyri. The middle frontal gyrus does not have a smooth, unbroken surface, but is broken up into multiple, tortuous segments. On the inferior frontal gyrus, formed by the pars orbitalis, triangularis, and opercularis, there can be multiple variations in the size and shape of the contributions from each part. The precentral gyrus, in this case, is broken up into several segments by limbs of the precentral sulcus. F, anterior view. A portion of the right superior frontal gyrus is broken into two longitudinal gyral strips. The left superior frontal gyrus is composed of multiple gyri that extend medially and laterally across the superior frontal area. The superior frontal sulci are continuous along both frontal lobes. The middle frontal gyri on both hemispheres are made up of numerous worm-like gyral segments. G, lateral view of another right frontal lobe. The pars triangularis and opercularis of the inferior frontal gyrus have a somewhat similar triangular appearance. Usually there is a gyral bridge at the lower margin of the central sulcus, but in this case the central sulcus opens into the Sylvian fissure. The precentral gyrus is continuous from its lower to its upper margin and is not broken up into multiple segments as shown in B and E. The middle frontal gyrus is made up of multiple irregular convolutions. H–J, variations in the sulcal and gyral patterns of the temporal lobe. H, right temporal lobe with a more typical pattern in which the three temporal gyri, superior, middle and inferior, are separated by two sulci, superior and inferior. The sulci have an irregular, tortuous course, but are largely continuous along the lateral temporal lobe from anterior to posterior. I, the superior temporal gyrus located above the superior temporal sulcus is easily identifiable. The part of the temporal lobe below the superior temporal sulcus is broken up into multiple obliquely oriented gyri that do not fit easily into a pattern of the expected middle and inferior gyri. J, the superior temporal gyrus is broken up into several segments but is fairly continuous. The middle and inferior temporal regions are formed by multiple obliquely oriented gyri and there is no clear inferior temporal sulcus. Ant., anterior; Asc., ascending; Call., callosum; Cent., central; Cing., cingulate; Corp., corpus; Fiss., fissure; Front., frontal; Horiz., horizontal; Inf., inferior; Interhem., interhemispheric; Mid., middle; Operc., opercularis; Orb., orbitalis; Postcent., postcentral; Precent., precentral; Sup., superior; Supramarg., supramarginal; Temp., temporal; Triang., triangularis.

sphere. The superior frontal gyrus extends around the superior margin of the hemisphere to form the upper part of the medial surface of the lobe. It is frequently incompletely subdivided into an upper and lower part. The middle frontal gyrus may also be divided into upper and lower parts.

The middle frontal gyrus on the lateral surface is situated lateral to the cingulate gyrus on the medial surface, and the two are separated by the deep white matter forming the centrum semiovale. The inferior frontal sulcus is located at the level of the upper margin of the anterior part of the corpus callosum, and the posterior part of the inferior frontal gyrus is positioned lateral to the frontal horn, caudate head, and anterior part of the insula. The pars orbitalis is continuous medially with the orbital surface of the frontal lobe. The lower part of the pars opercularis may be connected by a gyral bridge to the lower part of the precentral gyrus. The pars opercularis and adjacent triangularis are frequently referred to as Broca's speech area. The apex of the pars triangularis is directed inferiorly toward the junction of the three rami—the anterior ascending, horizontal, and posterior rami—of the sylvian fissure; this junctional point coincides with the anterior part of the circular sulcus of the insula in the depth of the sylvian fissure. It also marks the anterior limit of the basal ganglia and the frontal horn of the lateral ventricle.

Parietal Lobe

The lateral surface of the parietal lobe is limited anteriorly by the central sulcus, superiorly by the interhemispheric fissure, inferolaterally by the sylvian fissure and a line, referred to as the extended sylvian line, extending posteriorly along the long axis of the sylvian fissure, and posteriorly by the line extending from the upper end of the parieto-occipital fissure to the preoccipital notch. Its two main sulci, the postcentral and intraparietal sulci, divide the lateral surface into three parts (Figs. 1.1, 1.3, and 1.5). The postcentral sulcus divides the parietal lobe into an anterior convolution, the postcentral gyrus, situated behind and parallel to the central sulcus, and a large posterior part subdivided by the horizontal sulcus, the intraparietal sulcus, into superior and inferior parietal lobules. The postcentral sulcus is similar to the central sulcus in shape, but is frequently broken into several discontinuous parts by gyral bridges. The intraparietal sulcus is oriented anteroposteriorly, parallel, and 2 to 3 cm lateral to the superior border of the hemisphere. The depth of the intraparietal sulcus is directed toward the roof of the atrium and the occipital horn. The superior parietal lobule extends from the intraparietal sulcus to the superior margin of the hemisphere.

The inferior parietal lobule, the larger of the two lobules, is divided into an anterior part formed by the supramarginal gyrus, which arches over the upturned end of the posterior ramus of the sylvian fissure, and a posterior part formed by the angular gyrus, which arches over the upturned end of the superior temporal sulcus. The inferior parietal lobule blends posteriorly into the anterior part of the occipital lobe. The supramarginal gyrus arching over the upturned posterior end of the sylvian fissure forms the most posterior opercular lips of the sylvian fissure. The supramarginal gyrus is located lateral

to the atrium of the lateral ventricle. The part of the supramarginal gyrus above the posterior end of the sylvian fissure is continuous in front with the lower end of the postcentral sulcus, and the part below the sylvian fissure is continuous with the superior temporal gyrus. The part of the angular gyrus above the superior temporal sulcus is continuous with the superior temporal gyrus, and below the superior temporal sulcus is continuous with the middle temporal gyrus.

Occipital Lobe

The occipital convexity is not separated from the temporal and parietal lobes by any clearly defined sulci (Figs. 1.1 and 1.3). It is composed of a number of irregular convolutions with considerable variability. The most consistent sulci, the lateral occipital sulcus, which is short and horizontal, divides the lobe into superior and inferior occipital gyri. The transverse occipital sulcus descends on the lateral surface behind the posterior part of the parieto-occipital arcus, a U-shaped gyrus that caps the short segment of the parieto-occipital sulcus that overlaps from the medial surface onto the lateral hemispheric surface. The anterior part of the arcus is parietal lobe and the posterior part is occipital lobe. The lambdoid suture joins the sagittal suture at approximately the parieto-occipital junction, but slopes downward across the occipital lobe behind the parieto-occipital junction. The calcarine sulcus, the most important sulcus on the occipital lobe, is located on the medial surface slightly below the midlevel of the lateral occipital surface at approximately the level of a line extending posteriorly along the long axis of the superior temporal sulcus.

Temporal Lobe

The lateral temporal surface, located below the sylvian fissure and the extended sylvian line and anterior to the line connecting the preoccipital notch and parieto-occipital sulci, is divided into three parallel gyri, the superior, middle, and inferior temporal gyri, by two sulci, the superior and inferior temporal sulci (Figs. 1.1, 1.3, and 1.6). Both the gyri and sulci parallel the sylvian fissure. The superior temporal gyrus lies between the sylvian fissure and the superior temporal sulcus and is continuous around the lip of the fissure with the transverse temporal gyri, which extend obliquely backward and medially toward the posterosuperior angle of the insula to form the lower wall of the posterior part of the floor of the sylvian fissure. The middle temporal gyrus lies between the superior and inferior temporal sulci. The temporal horn and the ambient and the crural cisterns are located deep to the middle temporal gyrus. The inferior temporal gyrus lies below the inferior temporal sulcus and continues around the inferior border of the hemisphere to form the lateral part of the basal surface. The angular gyrus, a parietal lobe structure, caps the upturned posterior end of the superior temporal sulcus. One or more of the temporal gyri are frequently separated into two or three sections by sulcal bridges, giving the related gyri an irregular discontinuous appearance. The variation is greater with the middle and inferior temporal gyri than with the superior temporal gyrus. The inferior temporal gyrus is often composed

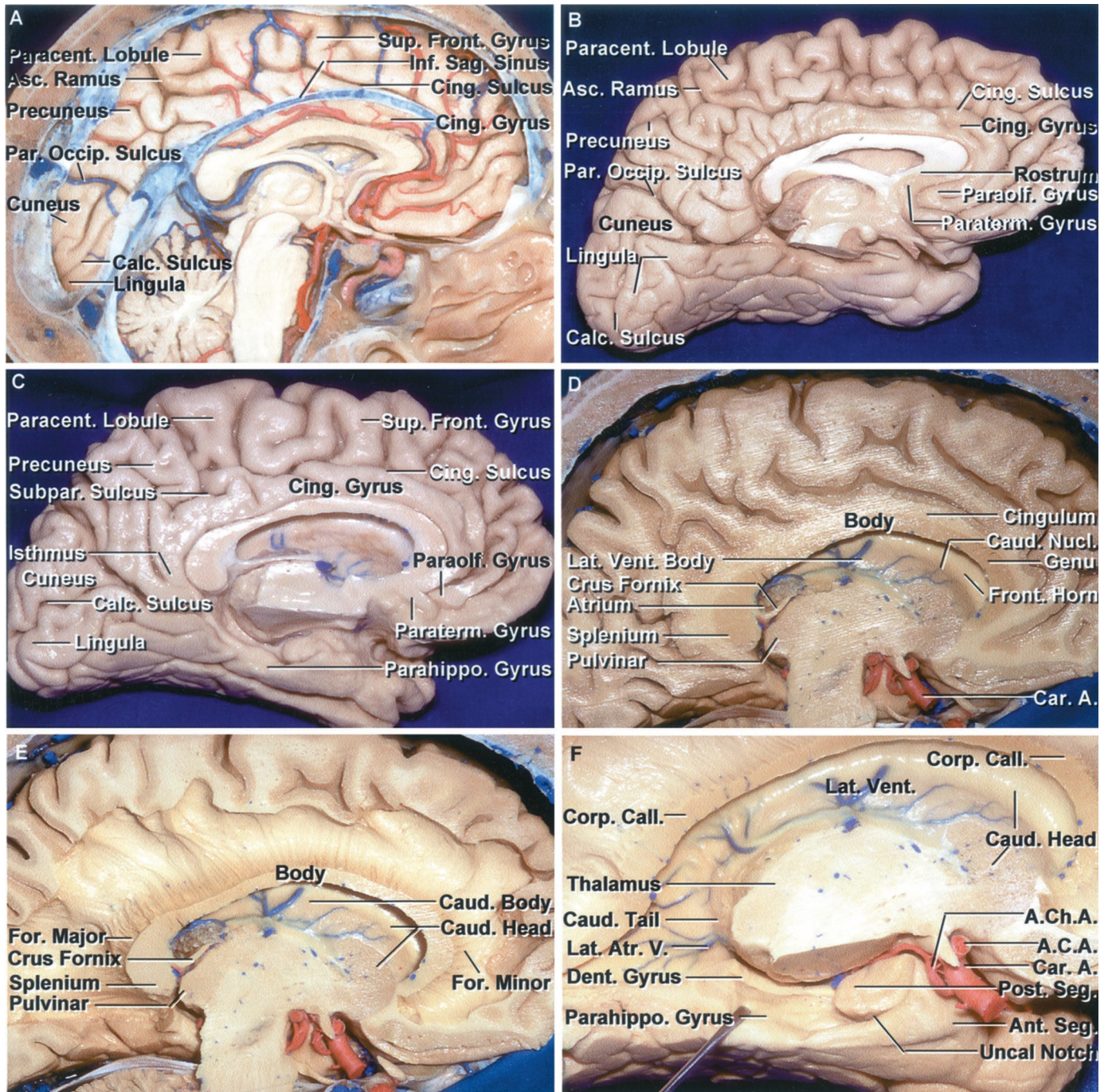


FIGURE 1.7. A–C, medial surface of the right cerebral hemisphere. A, the falx, except for the inferior sagittal sinus, has been removed. The majority of the medial surface of the frontal lobe is formed by the cingulate and superior frontal gyri that are separated by the cingulate sulcus. The ascending ramus of the cingulate sulcus passes behind the paracentral lobule, the site of the extension of the pre- and postcentral gyri onto the medial surface of the hemisphere. The medial surface behind the paracentral lobule is formed by the precuneus, cuneus, and lingula and the posterior part of the cingulate sulcus. The precuneus is located between the paracentral lobule and parieto-occipital sulcus. The cuneus is located between the parieto-occipital and the calcarine sulci. The lingual gyrus (lingula) is located below the calcarine sulcus. B, medial surface of another hemisphere. The paraterminal and paraolfactory gyri are located below the rostrum of the corpus callosum. The precuneus is located between the ascending ramus of the cingulate sulcus, the parieto-occipital sulcus, and the subparietal sulcus, a posterior extension of the cingulate sulcus. The cuneus is located between the parieto-occipital and calcarine sulci, and the lingula is located below the calcarine sulcus. The parieto-occipital and calcarine sulci join to create a Y-shaped configuration. The parahippocampal gyrus forms the majority of the medial surface of the temporal lobe. C, another hemisphere. The medial surface is formed by the paraterminal, paraolfactory, superior frontal, and cingulate gyri and the paracentral lobule, precuneus, cuneus, lingula, and parahippocampal gyrus. The cingulate sulcus narrows

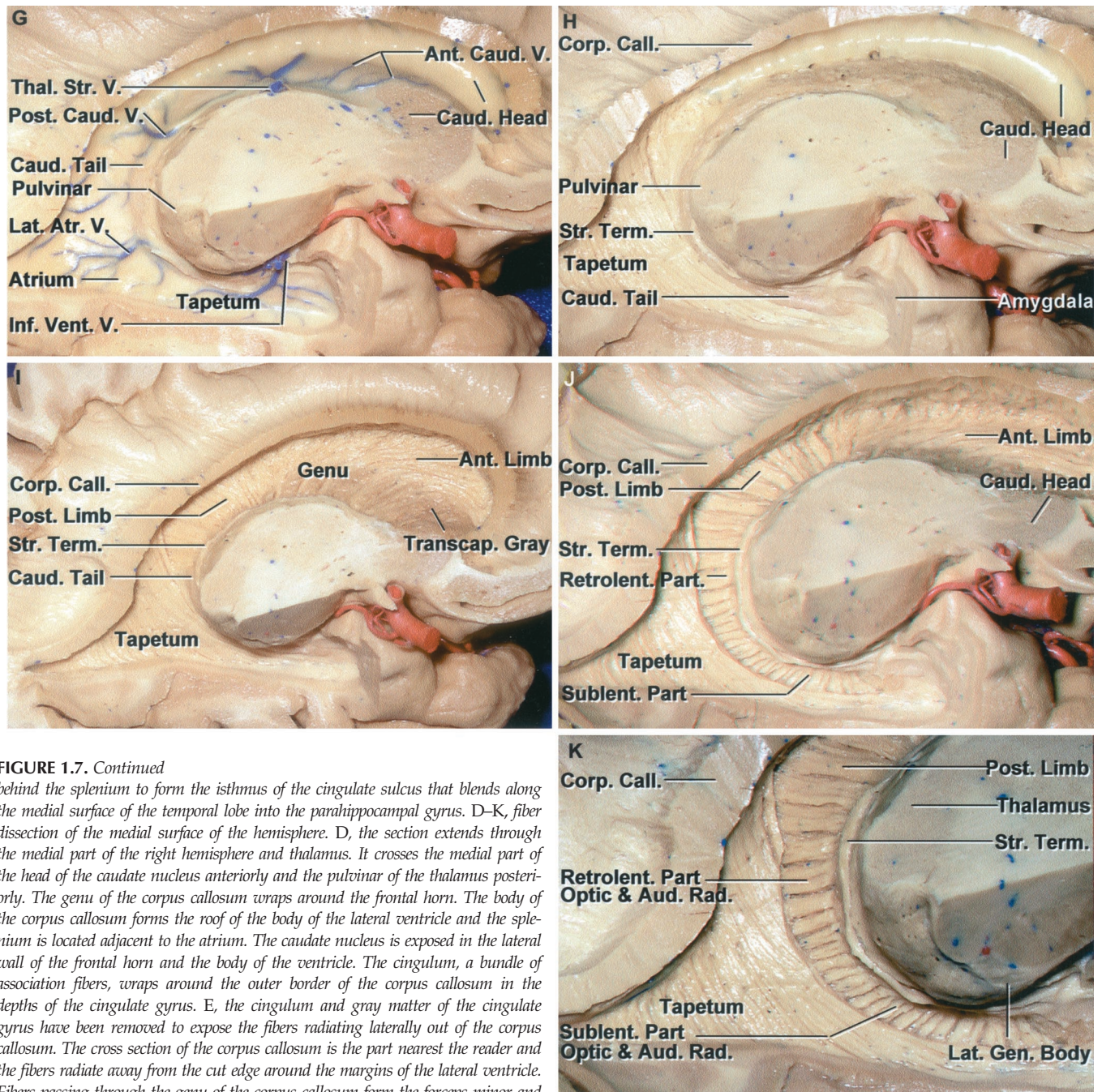


FIGURE 1.7. Continued

behind the splenium to form the isthmus of the cingulate sulcus that blends along the medial surface of the temporal lobe into the parahippocampal gyrus. D–K, fiber dissection of the medial surface of the hemisphere. D, the section extends through the medial part of the right hemisphere and thalamus. It crosses the medial part of the head of the caudate nucleus anteriorly and the pulvinar of the thalamus posteriorly. The genu of the corpus callosum wraps around the frontal horn. The body of the corpus callosum forms the roof of the body of the lateral ventricle and the splenium is located adjacent to the atrium. The caudate nucleus is exposed in the lateral wall of the frontal horn and the body of the ventricle. The cingulum, a bundle of association fibers, wraps around the outer border of the corpus callosum in the depths of the cingulate gyrus. E, the cingulum and gray matter of the cingulate gyrus have been removed to expose the fibers radiating laterally out of the corpus callosum. The cross section of the corpus callosum is the part nearest the reader and the fibers radiate away from the cut edge around the margins of the lateral ventricle. Fibers passing through the genu of the corpus callosum form the forceps minor and the anterior wall of the frontal horn and the large bundle passing posteriorly from the splenium forms the forceps major creating a prominence, the bulb of the corpus callosum, in the medial wall of the atrium. The crus of the fornix wraps around the pulvinar in the anterior wall of the atrium. F, the brainstem has been removed to expose the uncus, which has anterior and posterior segments. The anterior segment faces the internal carotid artery. The posterior segment, facing posteromedially, is divided into an upper and lower part by the uncus notch. Removing the brainstem also exposes the parahippocampal and dentate gyri. The crus of the fornix and splenium have been removed to expose the caudate tail extending around the pulvinar. G–K, fiber dissection of the medial surface of the hemisphere. G, the posterior segment of the uncus has been removed while preserving the anterior segment. The thalamostriate, anterior and posterior caudate, lateral atrial, and inferior ventricular veins cross the wall of the ventricle. The thalamostriate vein courses in the sulcus between the caudate nucleus and thalamus on the outer surface of the stria terminalis. The caudate tail extends around the pulvinar and into the roof of the temporal horn. H, the ependymal wall of the ventricle has been removed to expose the fibers in a subependymal area. The caudate tail is exposed below the pulvinar. The stria terminalis courses between the caudate and thalamus. The tapetum of the corpus callosum forms the roof and lateral wall of the atrium and temporal horn. The amygdala is located in the anterior segment of the uncus and forms the anterior wall of the temporal horn. (Legend continues on next page.)

of multiple fragmented gyri and may blend into the middle temporal gyrus without a clear sulcal demarcation.

Medial Hemispheric Surface

The frontal, parietal, occipital, and temporal lobes have medial surfaces (Fig. 1.7). The medial surfaces of the frontal, parietal, and occipital lobes are flattened vertically against the falx cerebri, are interconnected below the falx in the floor of the interhemispheric fissure by the corpus callosum, and are separated from the corpus callosum by the callosal sulcus. The medial surface of the temporal lobe is much more complex (9). It wraps around the cerebral peduncle and upper brainstem and forms the lateral wall of the cisterns above the tentorial incisura.

The general organization of the gyri of the frontal, parietal, and occipital lobes on the medial surface can be compared with that of a three-layer roll: the inner layer is represented by corpus callosum, the intermediate layer by cingulate gyrus, and the outer layer, from anterior to posterior, by the medial surface of the superior frontal gyrus, the paracentral lobule, precuneus, cuneus, and the lingula (8). The cingulate gyrus wraps around and is separated inferiorly from the corpus callosum by the callosal sulcus. The cingulate gyrus is separated on its outer margin from the remainder of the medial surface of the superior frontal gyrus and the paracentral lobule by the cingulate sulcus and from the precuneus and remainder of the parietal lobe by the subparietal sulcus, an indistinct posterior continuation of the cingulate sulcus behind the marginal ramus. The cingulate gyrus begins below the rostrum of the corpus callosum, curves around the genu and body of the corpus callosum, and turns downward behind the splenium, where it is connected by a narrow gyral bridge, the isthmus of the cingulate gyrus, to the parahippocampal gyrus. Several secondary rami, of which the paracentral and ascending rami are the most important, ascend from the cingulate sulcus to divide the outer layer into several sections. The paracentral ramus ascends from the cingulate sulcus at the level of the midportion of the corpus callosum to separate the superior frontal gyrus anteriorly from the paracentral lobule posteriorly. The marginal or ascending ramus ascends from the cingulate sulcus at the level of the

posterior third of the corpus callosum and separates the paracentral lobule anteriorly from the precuneus posteriorly. The paracentral lobule, the extension of the pre- and postcentral gyri that wraps around the extension of the central sulcus onto the medial surface, is the site of the motor and sensory areas of the contralateral lower limb and perineal region and the voluntary control areas of defecation and micturition. The part of the paracentral lobule behind the central sulcus is a part of the parietal lobe. The paracentral lobule is located above the posterior half of the corpus callosum. The marginal ramus, present in almost all hemispheres, is an important aid in magnetic resonance imaging in locating the sensory or motor areas on the medial surface.

Frontal Lobe

The medial surface of the frontal lobe is formed predominantly by the medial surface of the superior frontal gyrus, the anterior half of the paracentral lobule, and the cingulate gyrus (Figs. 1.3 and 1.7). The superior frontal gyrus parallels the superior border and is separated from the cingulate gyrus by the cingulate sulcus. The cingulate sulcus parallels and is situated on the medial surface at the level of the superior frontal sulcus on the lateral surface. Anteriorly, the cingulate and the superior frontal gyri wrap around the genu and the rostrum of the corpus callosum and blend into the paraterminal and parolfactory gyri situated below the rostrum of the corpus callosum and in front of the lamina terminalis. The paraterminal gyrus is a narrow triangle of gray matter in front of the lateral edge of the lamina terminalis that is continuous with the indusium griseum, the thin lamina of gray matter that covers the upper surface of the corpus callosum. The paraterminal gyrus is separated at its anterior edge from the adjacent paraolfactory gyrus by the shallow posterior paraolfactory sulcus. The anterior paraolfactory sulcus, a short vertical sulcus, separates the paraolfactory gyrus from the anterior part of the frontal pole.

Parietal Lobe

The medial parietal surface is situated between the line from the upper end of the central sulcus to the corpus callo-

FIGURE 1.7. Continued

The anterior choroidal artery courses around the anterior and posterior segments of the uncus to reach the choroid plexus in the temporal horn. I, the caudate nucleus has been removed to expose the fibers constituting the internal capsule. The anterior thalamic peduncle and anterior limb of the internal capsule courses lateral to the caudate head. The anterior limb is crossed by bridges of transcapsular gray matter interconnecting the caudate and lentiform nuclei that gives it a prominent striate appearance and a deeper color than the posterior part of the internal capsule. The superior thalamic peduncle and genu of the internal capsule are exposed above the thalamus. The posterior thalamic peduncle and posterior limb of the internal capsule are exposed behind the genu. The upper part of the optic radiations course behind the pulvina in the retrolenticular part of the internal capsule. The tapetum sweeps downward to form the roof and lateral wall of the atrium and temporal horn. J, enlarged view. The stria terminalis wraps around the posterior margin of the thalamus and blends into the amygdala. The fibers forming the anterior and posterior limbs and the retro- and sublenticular parts of the internal capsule have been exposed. K, enlarged view. The sublenticular part of the optic and auditory radiations pass laterally and are separated from the temporal horn by only the tapetum. The retrolenticular part of the internal capsule contains some of the optic radiations. A., artery; A.C.A., anterior cerebral artery; A.Ch.A., anterior choroidal artery; Ant., anterior; Asc., ascending; Atr., atrial; Aud., auditory; Calc., calcarine; Call., callosum; Car., carotid; Caud., caudate; Cing., cingulate; Corp., corpus; Dent., dentate; For., forceps; Front., frontal; Gen., geniculate; Inf., inferior; Lat., lateral; Nucl., nucleus; Par. Occip., parieto-occipital; Paracent., paracentral; Parahippo., parahippocampal; Paraolf., paraolfactory; Paraterm., paraterminal; Post., posterior; Rad., radiations; Retrolent., retrolenticular; Sag., sagittal; Seg., segment; Str., stria; Sublent., sublenticular; Subpar., subparietal; Sup., superior; Term., terminalis; Thal. Str., thalamostriate; Transcap., transcapsular; V., vein; Vent., ventricle, ventricular.

sum anteriorly and the parieto-occipital sulcus posteriorly. It is formed by the precuneus and the posterior part of the cingulate gyrus and paracentral lobule (Figs. 1.3, 1.5, and 1.7). The precuneus is a quadrilateral area bounded anteriorly by the ascending ramus of the cingulate sulcus, posteriorly by the parieto-occipital sulcus above the superior hemispheric border, and inferiorly from the cingulate gyrus by the subparietal sulcus. The posterior part of the cingulate gyrus wraps around the splenium and is separated from the precuneus by the subparietal sulcus and from the splenium by the callosal sulcus. The posterior part of the paracentral lobule is a medial extension of the postcentral gyrus, and the precuneus is the medial extension of the superior parietal lobule. The subparietal sulcus is located at approximately the level of the interparietal sulcus on the lateral surface.

Occipital Lobe

The medial surface of the occipital lobe is separated from the parietal lobe by the parieto-occipital sulcus (Figs. 1.3, 1.5, and 1.7) (12). The calcarine fissure extends forward from the occipital pole toward the splenium and divides this surface into an upper part, the cuneus, and a lower part, the lingula. The cuneus is a wedge-shaped lobule, bounded in front by the parieto-occipital sulcus, below by the calcarine sulcus, and above by the superior border of the hemisphere. The lingula, a narrow convolution between the calcarine sulcus and the lower border of the medial surface, has, as its name suggests, a tongue-like appearance, with the tip of the tongue located at the occipital pole. The lingula blends anteriorly into the posterior part of the parahippocampal gyrus that extends backward from the temporal lobe.

The parieto-occipital sulcus is directed downward and forward from the superior border between the cuneus and precuneus at an angle of approximately 45 degrees. It descends to join the anterior part of the calcarine sulcus, giving the region a Y-shaped configuration. The parieto-occipital sulcus courses approximately parallel to the line on the convexity that connects the preoccipital notch and the upper end of the parieto-occipital sulcus.

The calcarine sulcus begins just above the occipital pole and courses forward with an upward convexity between the cuneus above and lingual below and joins the parieto-occipital sulcus. It continues anteriorly below the isthmus of the cingulate gyrus, where it may intersect the posterior part of the parahippocampal gyrus before terminating. The primary visual receiving area is located on the upper and lower banks and the depths of the posterior part of the calcarine sulcus. It may overlap for a short distance on the lateral aspect of the occipital pole, then continues anteriorly on the medial surface to intercept the isthmus of the cingulate gyrus. The portion of the calcarine sulcus anterior to the junction with the parieto-occipital sulcus extends so deeply into the medial surface of the hemisphere that it forms a prominence, the calcar avis, in the medial wall of the atrium. The part of the calcarine sulcus posterior to its junction with the parieto-occipital sulcus has the visual (striate) cortex on its upper and lower lips, and the part anterior to the junction with the parieto-occipital sulcus

has visual cortex only on its lower lip (8). The basal surface of the occipital lobe slopes upward from its lateral edge, thus placing the calcarine sulcus higher relative to the convexity than it is on the medial surface. Although located low on the medial occipital surface, the anterior end of the calcarine sulcus is located deep to the posterior part of the superior temporal gyrus, and the posterior part is located deep to the midportion of the lateral occipital surface (Fig. 1.5C).

Temporal Lobe

The medial surface of the temporal lobe is the most complex of the medial cortical areas (Figs. 1.8–1.10) (10). It is formed predominantly by the rounded medial surfaces of the parahippocampal gyrus and uncus. This medial surface is composed of three longitudinal strips of neural tissue, one located above the other, which are interlocked with the hippocampal formation. The most inferior strip is formed by the rounded medial edge of the parahippocampal gyrus, the site of the subicular zones; the middle strip is formed by the dentate gyrus, a narrow serrated strip of gray matter located on the medial surface of the hippocampal formation; and the superior strip is formed by the fimbria of the fornix, a white band formed by the fibers emanating from the hippocampal formation and directed posteriorly into the crus of the fornix. The parahippocampal and dentate gyri are separated by the hippocampal sulcus, and the dentate gyrus and the fimbria are separated by the fimbriodentate sulcus. The amygdala and the hippocampal formation lie just beneath and are so intimately related to the mesial temporal cortex that they are considered in this section. The dentate gyrus blends posteriorly behind the splenium into the fasciolar gyrus, which is continuous with the indusium griseum.

The parahippocampal gyrus deviates medially at the site of the uncus that projects medially above the tentorial edge. The parahippocampal gyrus also extends around the lower border to form the medial part of the basal surface of the temporal lobe, where it is separated from the medially projecting uncus by the rhinal sulcus. Posteriorly, the part of the parahippocampal gyrus below the splenium of the corpus callosum is intersected by the anterior end of the calcarine sulcus, which divides the posterior portion of the parahippocampal gyrus into an upper part that is continuous above and posteriorly with the isthmus of the cingulate gyrus and continuous below and posteriorly with the lingual gyrus.

The uncus, the medially projecting anterior part of the parahippocampal gyrus, when viewed from above or below, has an angular shape with anterior and posterior segments that meet at a medially directed apex (Figs. 1.8 and 1.9). The anterior segment of the uncus faces anteromedial and the posterior segment faces posteromedial. The anterior segment has an undivided medial surface, but the posterior segment is divided into upper and lower parts by the uncal notch, a short sulcus that extends from posteriorly into the medial aspect of the posterior segment. The medial face of the anterior segment faces the proximal part of the sylvian, the carotid cistern, and the internal carotid and proximal middle cerebral arteries. The posterior segment faces the cerebral peduncle and, with the

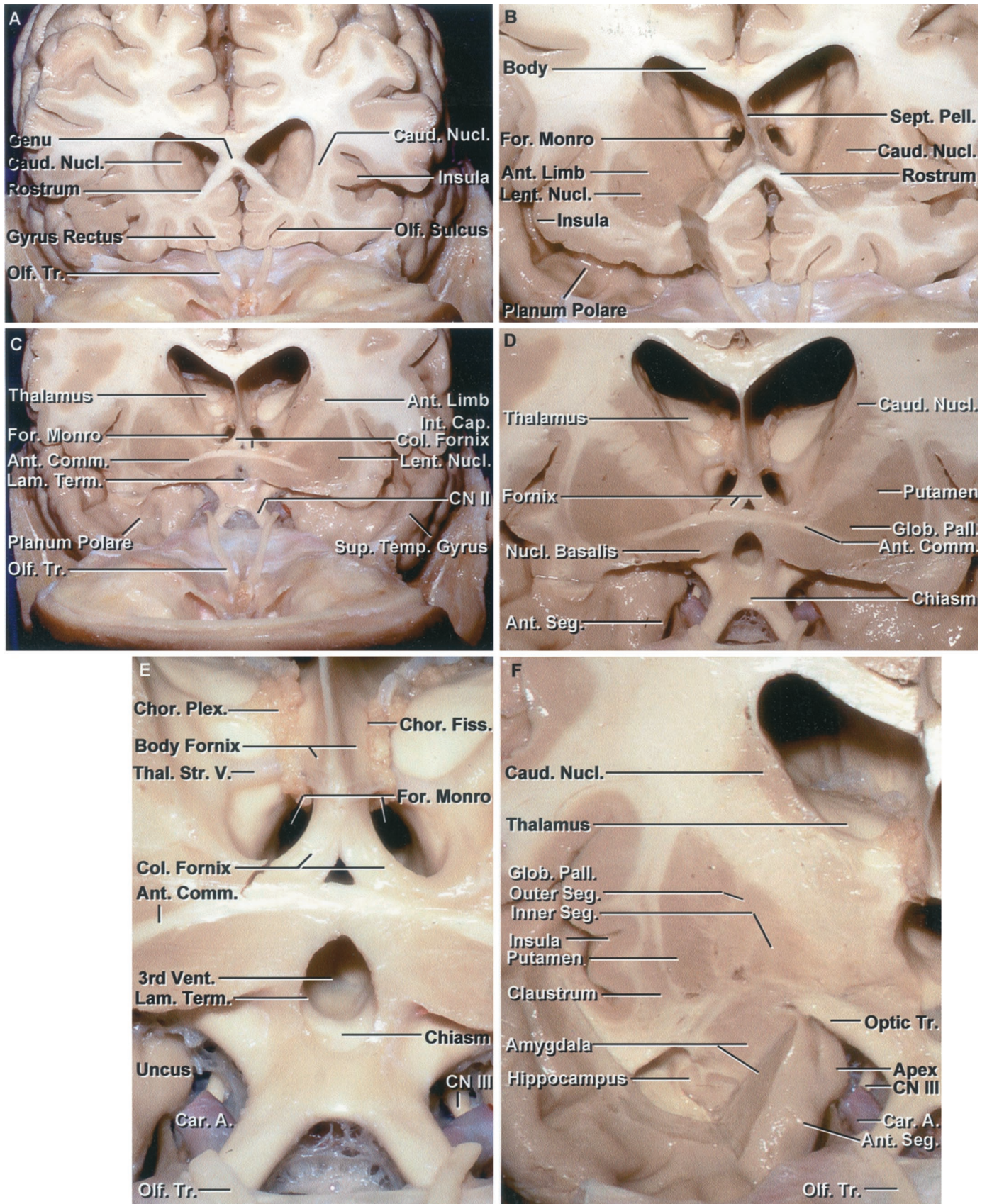


FIGURE 1.8. (See legend beginning on page S1-24.)

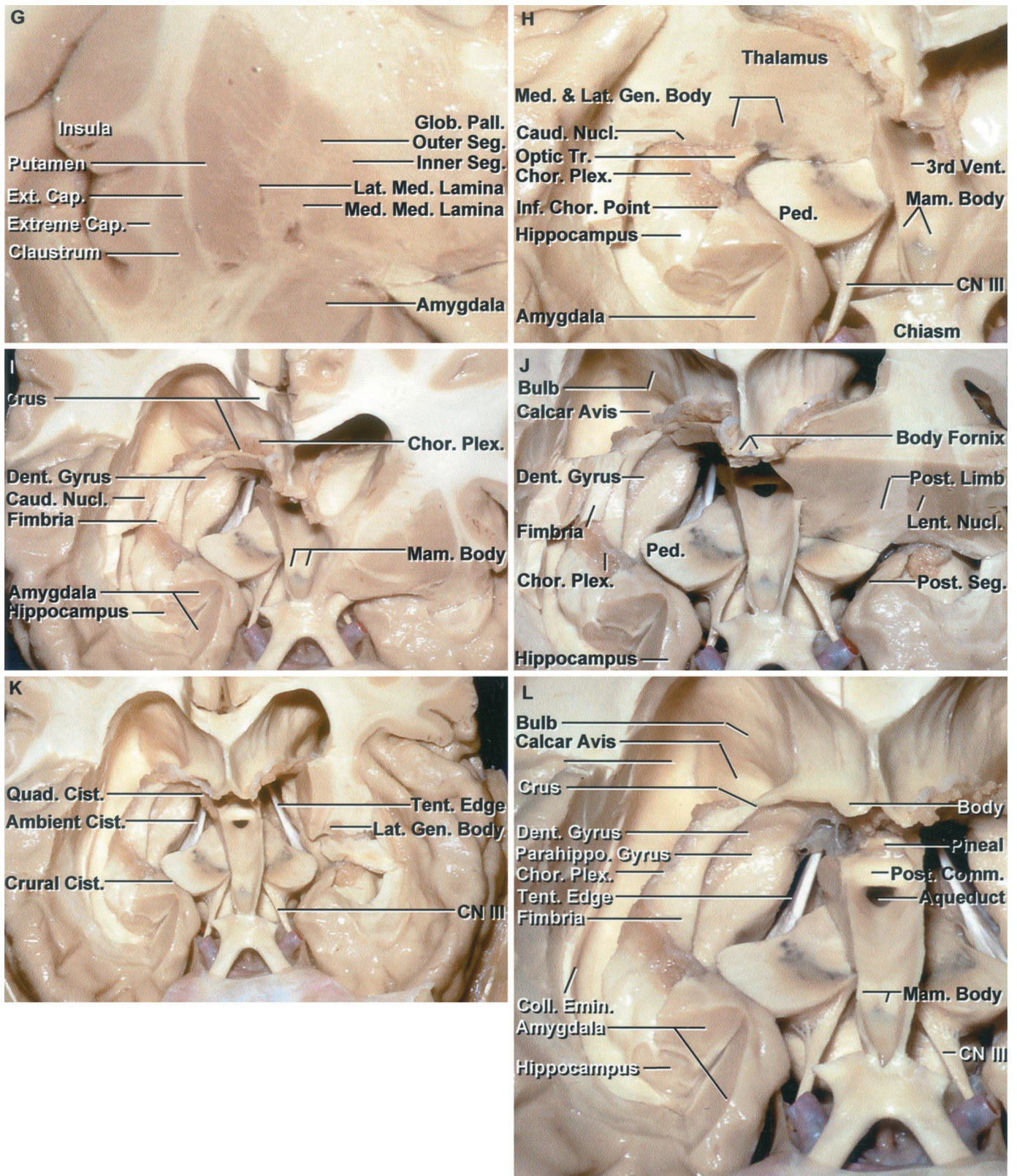


FIGURE 1.8. (See legend beginning on page S1-24.)

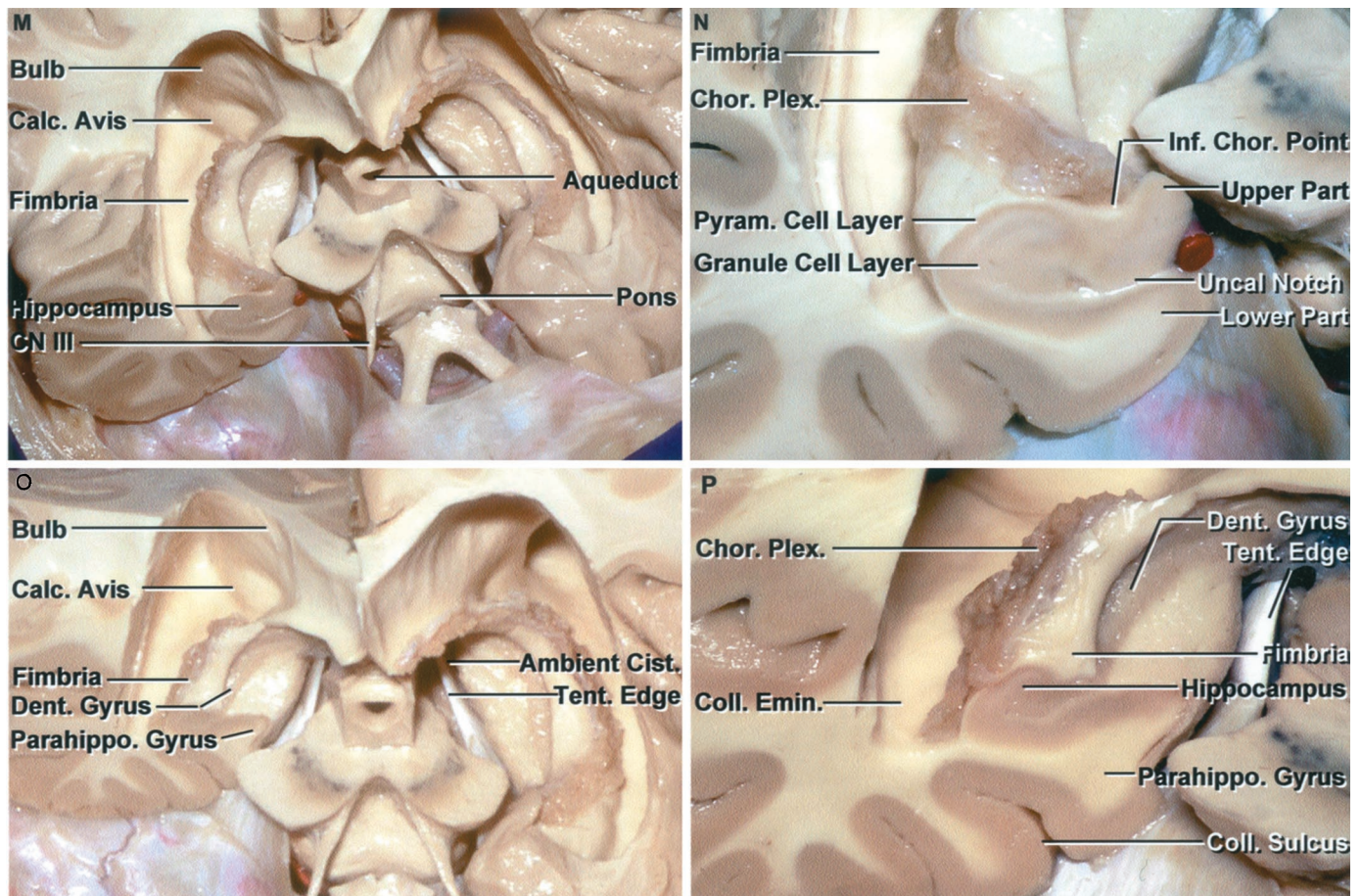


FIGURE 1.8. Stepwise dissection of the cerebral hemispheres, beginning anteriorly. A, coronal section at the level of the rostrum of the corpus callosum and anterior part of the frontal horn. The anterior wall and adjacent part of the roof of the frontal horn are formed by the genu of the corpus callosum, the floor by the rostrum, and the lateral wall by the caudate nucleus. The insular surface is small at this level. The gyrus rectus is located medial to the olfactory tracts. B, the section has been extended to the midportion of the frontal horn. The roof is formed by the body of the corpus callosum, the lateral wall by the caudate nucleus, the floor by the rostrum, and the medial wall by the septum pellucidum. The anterior limb of the internal capsule passes between the caudate and the lentiform nuclei. The caudate nucleus blends into the lentiform nucleus in the area below the anterior limb of the internal capsule. The planum polare on the upper surface of the anterior part of the temporal lobe is devoid of gyri and has a shallow trough along which the middle cerebral artery courses. C, the cross section has been extended posteriorly to the level of the lamina terminalis and the anterior commissure. The columns of the fornix pass around the anterior and superior margin of the foramen of Monro and turn downward behind the lamina terminalis toward the mammillary bodies. At this level, the lentiform nucleus has taken on its characteristic triangular or lens shape in cross section. D, enlarged view. The lamina terminalis has been opened. The anterior limb of the internal capsule separates the caudate and lentiform nuclei. The lentiform nucleus is formed by the putamen and globus pallidus. The anteroinferior part of the caudate and lentiform nuclei blends without clear demarcation into the large mass of gray matter above the anterior perforated substance and adjacent part of the orbital surface of the frontal lobe that also includes the nucleus basalis and accumbens. The nucleus basalis is located below the anterior commissure and the accumbens is located anterior to the basalis without clear demarcation between these two nuclei or the adjacent part of the lentiform and caudate nuclei. The anterior segment of the uncus is exposed lateral to the carotid artery. E, enlarged view. The olfactory nerves pass posteriorly above the optic nerves. The choroidal fissure, the cleft between the thalamus and body of the fornix along which the choroid plexus is attached, begins at the posterior edge of the foramen of Monro. The thalamostriate vein courses through the posterior margin of the foramen of Monro and between the thalamus and caudate nucleus. The oculomotor nerves are exposed behind the carotid arteries. F, the cross section has been extended backward to the level of the foramen of Monro. At this level the caudate nucleus is considerably smaller than anteriorly. The globus pallidus has a clearly defined inner and outer segment. The anterior part of the roof of the temporal horn has been removed to expose the amygdala and anterior part of the hippocampus. The amygdala, at its upper margin, blends into the globus pallidus. The combination of the globus pallidus and amygdala seem to wrap around the lateral aspect of the optic tract. The apex of the uncus protrudes medially toward the oculomotor nerve. The anterior uncal segment is located lateral to the carotid artery. The claustrum is located between the insula and the lentiform nucleus. The amygdala fills most of the anterior segment of the uncus and forms the anterior wall of the temporal horn. The amygdala tilts backward above the anterior part of the hippocampal head and roof of the temporal horn. G, enlarged view of the lentiform nucleus and amygdala. The extreme capsule separates the claustrum and insula, and the external capsule separates the claustrum and lentiform nucleus. The lateral medullary lamina separates the putamen from the outer segment of the globus pallidus and the medial medullary lamina separates the medial and lateral segments of the globus pallidus. H, the cross section of the right hemisphere has been extended behind the cerebral peduncle and across the terminal part of the optic tract and the lateral and medial geniculate bodies. The section of the midbrain extends through the cerebral peduncle and substantia nigra.

peduncle, forms the lateral and medial walls of the crural cistern through which the posterior cerebral, anterior choroidal, and medial posterior choroidal arteries pass. The optic tract passes above the medial edge of the posterior segment in the roof of the crural cistern. The amygdaloid nucleus forms almost all of the interior and comes to the medial surface of the upper part of the anterior segment. The upper part of the posterior segment is formed largely by the medial aspect of the head of the hippocampus. The apex, where the anterior and posterior segments meet, points medially toward the oculomotor nerve and posterior communicating artery. The head of the hippocampus reaches the medial surface in the upper part of the posterior segment at the anterior end of the dentate gyrus. Within the ventricle, a small medially projecting space, the uncal recess, situated between the ventricular surface of the amygdala and hippocampal head, is located lateral to the uncal apex.

The lower surface of the superior lip of the uncal notch is visible from below only after removing the lower lip formed by the parahippocampal gyrus (Fig. 1.9). The posterior segment is occupied by several small gyri that are continuations of the dentate gyri. The inferior choroidal point, the lower end of the choroidal fissure along which the choroid plexus is attached, is located just behind the upper edge of the posterior uncal segment, immediately behind the head of the hippocampus, at the site where the anterior choroidal artery passes through the choroidal fissure to enter the temporal horn. The anterior choroidal artery arises near the midlevel of the ante-

rior segment and hugs its surface, sloping gently upward, unless extremely tortuous. It continues to ascend as it courses posteriorly around the uncal apex and reaches the upper part of the posterior segment, where it passes through the fissure at the inferior choroidal point. The dentate gyrus, named for its characteristic tooth-like elevations, extends posteriorly from the upper part of the posterior segment and has the most prominent denticulations anteriorly. The dentate gyrus is continuous posteriorly below and behind the splenium of the corpus callosum with the fasciolar gyrus, a smooth grayish band that blends above into the indusium griseum.

The amygdala can be considered as being entirely located within the boundaries of the uncus (Figs. 1.8–1.10). It forms the anterior wall of the temporal horn. Superiorly, the amygdala blends into the claustrum and globus pallidus without any clear demarcation. The upper posterior portion of the amygdala tilts back above the hippocampal head and the uncal recess to form the anterior portion of the roof of the temporal horn. Medially, it is related to the anterior and posterior segments of the uncus. In coronal cross section, the optic tract sits medial to the junction of the amygdala and globus pallidus. The amygdala gives rise to the stria terminalis, which courses between the thalamus and caudate nucleus deep to the thalamostriate vein.

The hippocampus, which blends into and forms the upper part of the posterior uncal segment, is a curved elevation, approximately 5 cm long, in the medial part of the entire length of the floor of the temporal horn (Fig. 1.8). It has the dentate gyrus along

The inferior choroidal point, the lower end of the choroidal fissure and attachment of the choroid plexus in the temporal horn, is located just behind the head of the hippocampus. The oculomotor nerve arises on the medial side of the cerebral peduncle. I, the thalamus has been removed on the right side. The choroid plexus is attached along the choroidal fissure located between the fornix and thalamus. The tail of the caudate nucleus courses in the roof of the temporal horn above the hippocampus. J, the axial section on the left side has been extended through the midportion of the cerebral peduncle and the coronal section through the thalamus. The thalamus forms the floor of the body of the ventricle. At the midthalamic level, the lentiform nucleus is reduced markedly in size as compared with the more anterior levels where it forms a prominent part of the deep gray matter. As the cross section moves posteriorly, the thalamus forms a progressively greater part of the central core of the hemisphere located between the insula and ventricular surface. The temporal horn is located below the lentiform nucleus. The posterior segment of the uncus faces the cerebral peduncle. The bulb of the corpus callosum overlying the forceps major and the calcar avis overlying the calcarine sulcus are exposed in the medial wall of the atrium. K, all of the right thalamus and the medial part of the left thalamus have been removed to expose the crural, ambient, and quadrigeminal cisterns. The midbrain forms the medial wall and the parahippocampal and dentate gyri form the lateral wall of the ambient cistern. The crural cistern is located between the posterior uncal segment and the cerebral peduncle. The left lateral geniculate body has been preserved. The optic radiations arise in the lateral geniculate body and pass laterally above the temporal horn. L, enlarged view. The body of the fornix is in the lower medial part of the wall of the body of the lateral ventricles. The crus of the fornix forms part of the anterior wall of the atrium and the fimbria sits on the upper surface of the hippocampus in the floor of the temporal horn. The amygdala fills most of the anterior segment of the uncus and the hippocampal head extends into the posterior segment. The posterior commissure, aqueduct, and mamillary bodies are exposed in the walls of the third ventricle. The anterior part of the third ventricular floor between the mamillary bodies and the infundibular recess is quite thin and is the site frequently selected for a third ventriculostomy. M, oblique anterior view. The cross section of the right temporal lobe crosses the posterior uncal segment. The floor of the third ventricle has been removed back to the level of the aqueduct to expose the interpeduncular fossa located between the cerebral peduncles and above the pons. The posterior part of the floor of the third ventricle is formed by the midbrain. N, enlarged view of the medial part of the posterior segment of the uncus. The posterior uncal segment is divided by an uncal notch into upper and lower parts. The lower part is formed by the parahippocampal gyrus, which is the site of the subicular zones, and the upper part is formed predominantly by the hippocampal head. The inferior choroidal point, the lower end of the choroid plexus and choroidal fissure and the point where the anterior choroidal artery enters the temporal horn is located just behind the head of the hippocampus. The pyramidal and granule cell layers are organized to give the hippocampal formation its characteristic appearance. O, the cross section of the right temporal lobe has been extended back to the level of the midportion of the temporal horn. The ambient cistern is limited medially by the midbrain and laterally by the parahippocampal and dentate gyri. P, enlarged view. The collateral sulcus cuts deeply into the hemisphere and forms a prominence, the collateral eminence in the floor of the temporal horn on the lateral side of the hippocampus. A., artery; Ant., anterior; Calc., calcar; Cap., capsule; Car., carotid; Caud., caudate; Chor., choroid, choroidal; Cist., cistern; CN, cranial nerve; Col., column; Coll., collateral; Comm., commissure; Dent., dentate; Emin., eminence; Ext., external; Fiss., fissure; For., foramen; Gen., geniculate; Glob., globus; Inf., inferior; Int., internal; Lam., lamina; Lat., lateral; Lent., lentiform; Mam., mamillary; Med., medial, medullary; Nucl., nucleus; Olf., olfactory; Pall., pallidus; Parahippo., parahippocampal; Ped., peduncle; Pell., pellucidum; Plex., plexus; Post., posterior; Pyram., pyramidal; Quad., quadrigeminal; Seg., segment; Sept., septum; Sup., superior; Temp., temporal; Tent., tentorial; Term., terminalis; Thal. Str., thalamostriate; Tr., tract; V., vein; Vent., ventricle.

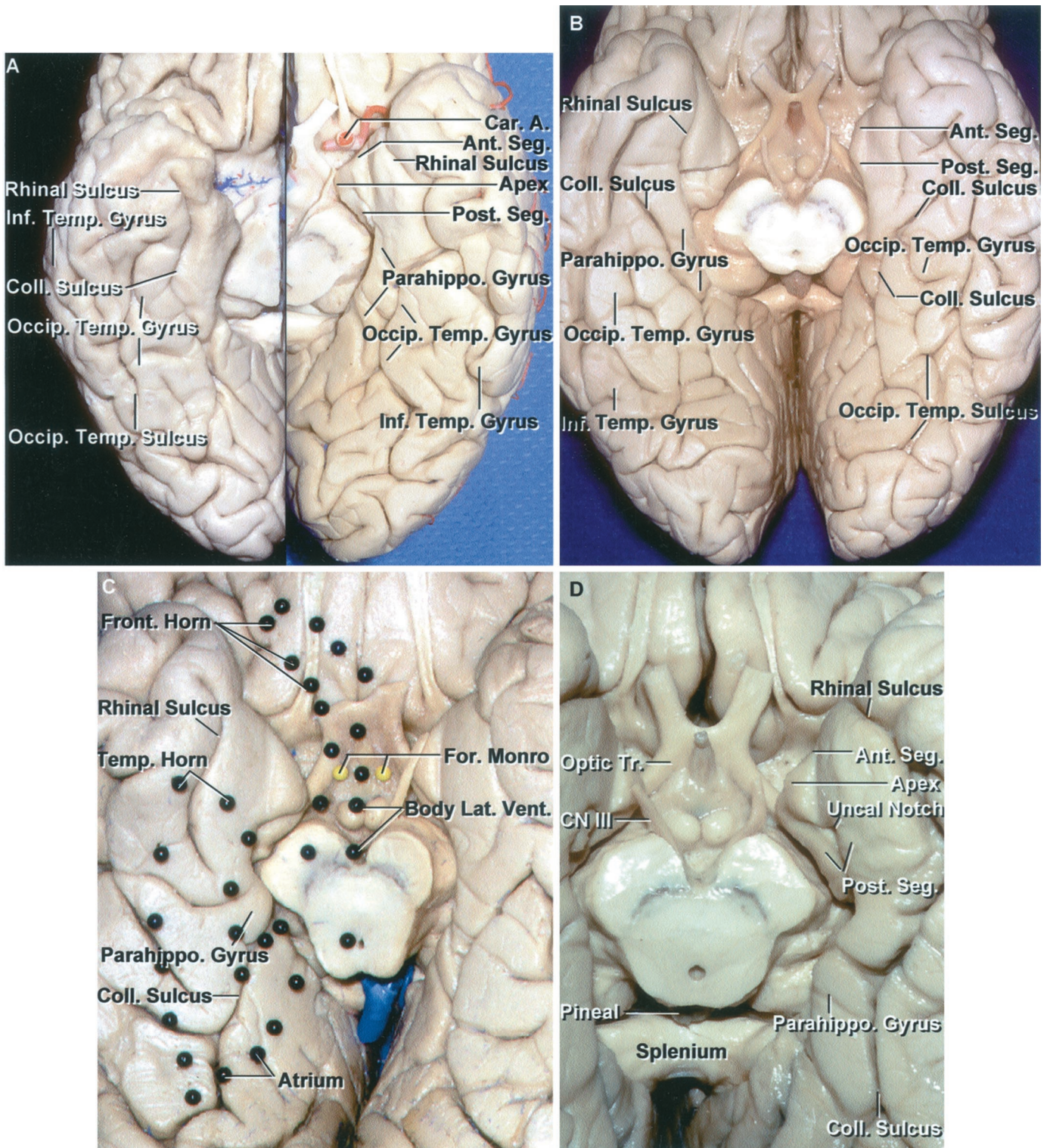
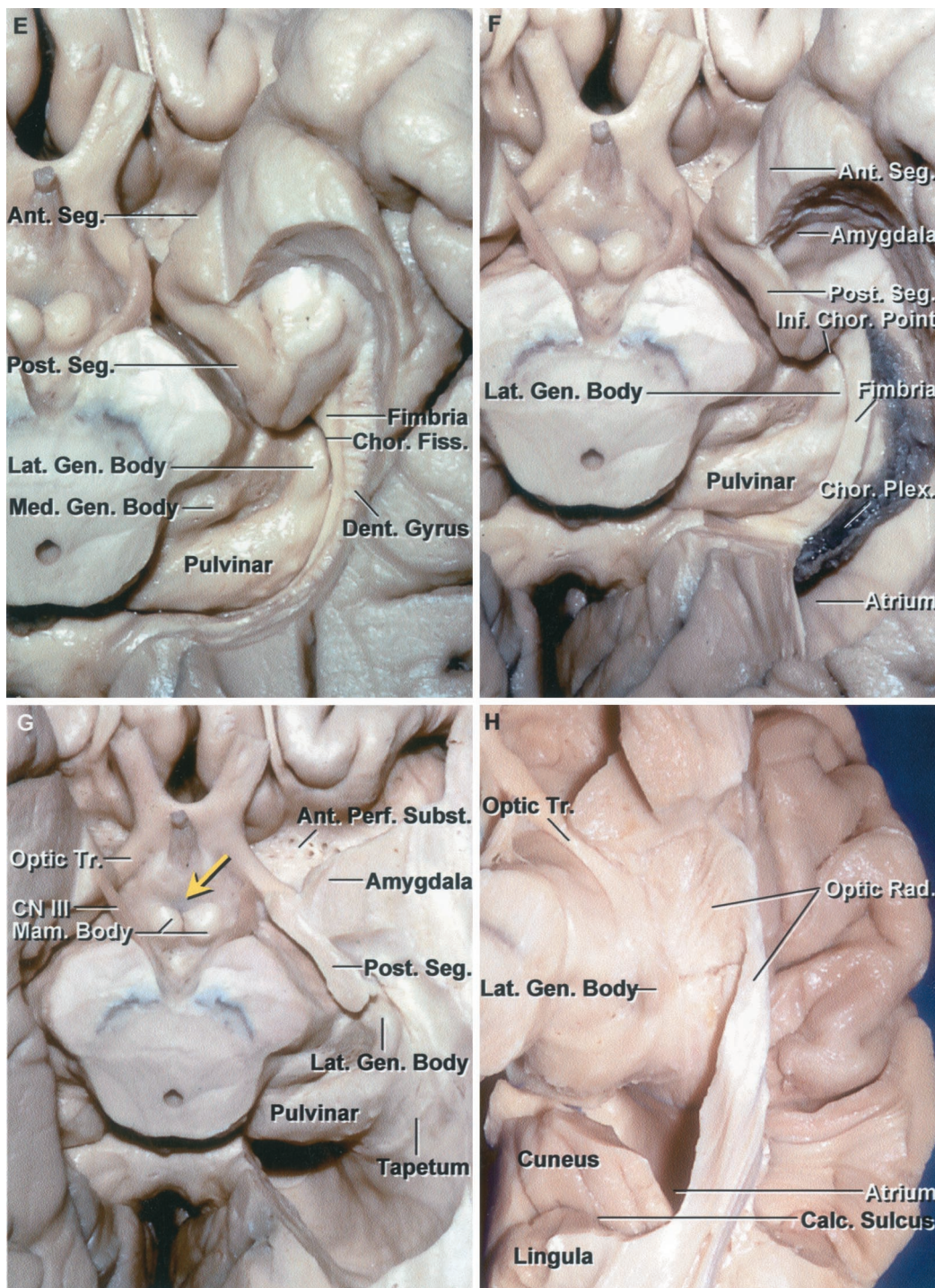


FIGURE 1.9. A, basal surface of the temporal and occipital lobes from two different brains. The collateral sulcus separates the parahippocampal and occipitotemporal gyri and extends backward onto the occipital lobe. The parahippocampal gyrus is broken up into several segments on both hemispheres by sulci crossing it from medial to lateral. The occipitotemporal gyri that form the middle strip along the long axis of the basal surfaces are discontinuous, as are the inferior temporal gyri that fold from the convexity around the lower margin of the hemispheres. The rhinal sulci that extend along the lateral margin of the uncus are in continuity with the collateral sulci. B, another cerebrum. The rhinal sulcus on both sides extends along the lateral uncal margin, but is not continuous with the collateral sulcus as in A.

FIGURE 1.9. Continued

The parahippocampal, occipitotemporal, and the inferior temporal gyri are broken up into multiple segments. C, enlarged view. Dark pins outline the position of the lateral ventricle above the basal surface. The frontal horn is located above the posteromedial part of the basal surface of the frontal lobe. The body of the ventricle is located above the midbrain and thalamus. The temporal horn is located above the collateral sulcus and parahippocampal gyrus. There are prominences, the collateral eminence, in the floor of the temporal horn and the collateral trigone, in the floor of the atrium, that overlie the deep end of the collateral sulcus. D, basal surface of another temporal lobe. The uncus has an anterior segment that faces forward toward the carotid cistern and entrance into the sylvian cistern and a posterior segment that faces posteriorly toward the cerebral peduncle and crural cistern. The apex between the anterior and posterior segment is located lateral to the oculomotor nerve. The medial part of the parahippocampal gyrus faces the ambient cistern located between the lateral side of the midbrain and the parahippocampal gyrus. The rhinal sulcus courses along the lateral margin of the anterior part of the uncus and is continuous with the collateral sulcus. The posterior segment of the uncus is divided into an upper and lower part by the uncus notch. E, the part of the posterior uncus segment below the uncus notch and the medial part of the parahippocampal gyrus have been removed to expose the lower surface of the upper half of the posterior segment that blends posteriorly into the beaded dentate gyrus. The fimbria is exposed above the dentate gyrus. The head of the hippocampus folds into the posterior segment of the uncus. The choroidal fissure located between the thalamus and fimbria extends along the lateral margin of the lateral geniculate body. F, the hippocampus and dentate gyrus have been removed while preserving the fimbria and choroid plexus attached along the choroidal fissure. The choroid plexus is attached on one side to the fimbria and on the opposite side to the lower margin of the thalamus. The amygdala forms the anterior wall of the temporal horn and fills the majority of the anterior segment of the uncus. The inferior choroidal point, the lower end of the choroidal fissure and choroid plexus, is located behind the uncus. G, the fimbria and choroid plexus have been removed to expose the roof of the temporal horn. The lower part of the anterior uncus segment has been removed to expose the amygdala. A small portion of the posterior segment sitting below the optic tract has been preserved. The inferior choroidal point, the most anterior attachment of the choroid plexus in the temporal horn and the lower end of the choroidal fissure, is located behind the head of the hippocampus in front of the lateral geniculate body and at the posterior edge of the cerebral peduncle. The tapetum of the corpus callosum forms the roof and lateral wall of the atrium. (Legend continues on next page.)



its medial edge and a curved collection of gray matter in its interior that is referred to as Ammon's horn. It sits above and is continuous below with the rounded medial surface of the parahippocampal gyrus referred to as the subicular surface. Ammon's horn is characterized in transverse sections of the hippocampal formation by its reversed C- or comma-shaped orientation and by its tightly packed pyramidal cell layer.

The hippocampus is divided into three parts: head, body, and tail (Figs. 1.8 and 1.9). The head of the hippocampus, the anterior and largest part, is directed anteriorly and medially, and forms the upper part of the posterior uncal segment. It is characterized by three or four shallow hippocampal digitations resembling that of a feline paw, giving it the name, *pes hippocampus*. The initial segment of the fimbria and the choroidal fissure are located at the posterior edge of the hippocampal head. Superiorly, the head of the hippocampus faces the posterior portion of the amygdala that is tilted backward above the hippocampal head to form the anterior part of the roof of the temporal horn. Anterior to the hippocampal head is the uncal recess, a cleft, located between the head of the hippocampus and the amygdala. The body of the hippocampus extends along the medial part of the floor of the temporal horn, narrowing into the tail that disappears as a ventricular structure at the anterior margin of the calcar avis, although histologically, the tail can be traced into a collection of gray matter that covers the inferior surface of the splenium.

The fimbria of the fornix arise on the ventricular surface of the hippocampus behind the head and just behind the choroidal fissure. The temporal horn extends into the medial part of the temporal lobe to just anterior to the hippocampal head and to just behind the amygdala. The temporal horn ends approximately 2.5 cm from the temporal pole. The inferior choroidal point, at the lower end of the choroidal fissure, is located just behind the head of the hippocampus and immediately lateral to the lateral geniculate body.

Basal Surface

The basal surface of the cerebrum has a smaller anterior part formed by the lower surface of the frontal lobe, which conforms to the orbital roof, and a larger posterior part formed by the lower surface of the temporal and occipital lobes, which conforms to the floor of the middle cranial fossa and the upper surface of the tentorium cerebelli.

Frontal Lobe

The entire inferior surface of the frontal lobe is concave from side to side and rests on the cribriform plate, orbital roof, and the lesser wing of the sphenoid bone (Figs. 1.3 and 1.11). The olfactory sulcus, which overlies the olfactory bulb and tract, divides

the orbital surface into a medial strip of cortex, the gyrus rectus, and a larger lateral part, the orbital gyri, an irregular group of convolutions. The orbital gyri are divided by the roughly H-shaped orbital sulcus into the anterior, medial, posterior, and lateral orbital groups. The anterior orbital gyri are situated between the anterior pole and the transverse limb of the H. The posterior orbital gyri extend posteriorly from the transverse part of the H to the anterior margin of the anterior perforated substance. The lateral orbital gyri are positioned lateral to the lateral vertical limb of the H. The medial orbital gyri are situated between the medial vertical limb of the H and the olfactory sulcus. At a deep level, the anterior part of the genu of the corpus callosum and frontal horn extend forward above the orbital surface to approximately the level of the transverse part of the H-shaped orbital sulcus. The anterior limb of the internal capsule and the caudate and lentiform nuclei are positioned above the anterior perforated substance and the posterior orbital gyri. In the subfrontal approach to the suprasellar area, the exposure extends below the frontal horn and the caudate and lentiform nuclei, which blend below and anteriorly with clear borders into the nucleus basal and accumbens to form a massive gray matter complex above the posterior orbital gyri and anterior perforated substance.

Temporal and Occipital Lobes

The basal surfaces of the temporal and occipital lobes are formed by the same gyri that continue from anterior to posterior across their uninterrupted border (Figs. 1.3 and 1.9). They are traversed longitudinally by the longer collateral and occipitotemporal sulci and the shorter rhinal sulcus that divide the region from medial to lateral into the parahippocampal and occipitotemporal gyri and the lower surface of the inferior temporal gyrus. The basal surface of the parahippocampal gyrus forms the medial part of the inferior surface. It extends backward from the temporal pole to the posterior margin of the corpus callosum. Its anterior end projects medially to form the uncus. It is continuous anteriorly with the uncus without a limiting border and continues posteriorly to blend into the isthmus of the cingulate gyrus and lingula.

The collateral sulcus, one of the most constant cerebral sulci, begins near the occipital pole and extends anteriorly, parallel and lateral to the calcarine sulcus. Posteriorly, it separates the lingula and occipitotemporal gyrus, and anteriorly, it courses between the parahippocampal and the occipitotemporal gyri. The collateral sulcus may or may not be continuous anteriorly with the rhinal sulcus, the short sulcus extending along the lateral edge of the uncus. The collateral sulcus is located below the temporal horn and indents deeply into the basal surface producing a prominence, the collateral eminence, in the floor

FIGURE 1.9. Continued

H, the tapetum fibers have been removed to expose the fibers of the optic radiation arising from the lateral geniculate body and passing across the roof and around the lateral wall of the temporal horn and the lateral wall of the atrium. Only a thin layer of tapetal fibers separate the optic radiations from the temporal horn and atrium as they pass posteriorly to reach the calcarine sulcus. The cuneus forms the upper bank and the lingula forms the lower bank of the calcarine sulcus. A., artery; Ant., anterior; Calc., calcarine; Car., carotid; Chor., choroid, choroidal; CN, cranial nerve; Coll., collateral; Dent., dentate; Fiss., fissure; For., foramen; Front., frontal; Gen., geniculate; Inf., inferior; Lat., lateral; Mam., mamillary; Med., medial; Occip., occipital; Parahippo., parahippocampal; Perf., perforated; Plex., plexus; Post., posterior; Rad., radiation; Seg., segment; Subst., substance; Temp., temporal; Tr., tract; Vent., ventricle.

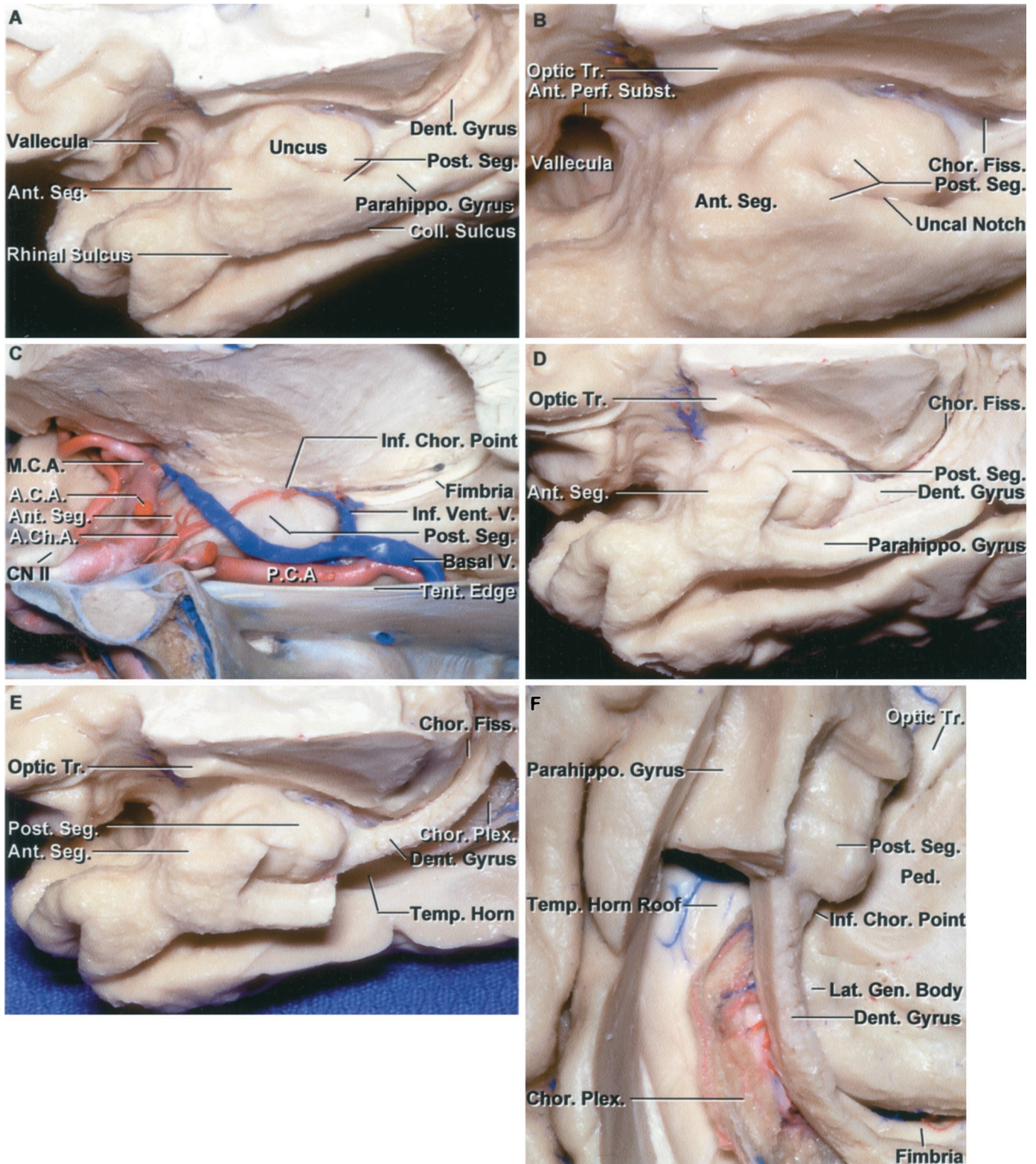


FIGURE 1.10. Medial surface of the temporal lobe and uncus. A, the uncus, a medial projection at the anterior end of the parahippocampal gyrus, has an anterior and posterior segment. The sylvian valleculla is the site where the middle cerebral artery exits the carotid cistern to enter the sylvian cistern. The collateral sulcus extends along the lateral margin of the parahippocampal gyrus, and the rhinal sulcus extends along the lateral edge of the uncus. (Legend continues on next page.)

of the temporal horn on the lateral side of the hippocampus. Posteriorly, in the area below the atrial floor, the collateral sulcus also indents deeply to produce a prominence in the triangular atrial floor called the collateral trigone. The temporal horn can be exposed from below by opening through the deep end of the collateral sulcus. The occipitotemporal sulcus courses parallel and lateral to the collateral sulcus and separates the occipitotemporal sulcus and basal surface of the inferior temporal gyrus.

The lower surface of the occipital lobe overlies the tentorium cerebelli (Figs. 1.3 and 1.9). It lies behind a line that extends laterally from the anterior end of the calcarine sulcus to the preoccipital notch. The inferior surface is formed by the lower part of the lingual gyrus or lingula, the posterior part of the occipitotemporal and the part of the lateral occipital gyri that overlap from the convexity onto the basal surface. The lingual gyrus blends anteriorly into the parahippocampal gyrus. The markings on the inferior surface of the occipital lobe are the posterior extension of the collateral and occipitotemporal sulci.

CENTRAL CORE

The central core of the hemisphere is located between the insula and the midline (Figs. 1.12 and 1.13). It is located deep to the pars triangularis and opercularis of the inferior frontal gyrus, the lower part of the pre- and postcentral gyri, anterior part of the supramarginal gyrus, and the superior temporal gyrus. The structures in the central core include the internal, external, and the extreme capsules, the caudate and lentiform nuclei, the claustrum and thalamus, and the fornix. All of the information passing between the cortex and the brainstem and spinal cord is relayed in or carried by fibers passing through the core.

In the core, medial to the anterior part of the insulae, the gray matter is formed predominantly by the caudate nucleus with a smaller contribution by the lentiform nucleus, and the

white matter is formed predominantly by the anterior limb of the internal capsule (Figs. 1.12–1.14). In proceeding backward from the anterior to the midinsular level and lateral to the foramen of Monro, the contribution of the caudate to the central core is greatly diminished, and that contributed by the lentiform nucleus (putamen plus globus pallidus) predominates. The contribution of the internal capsule to the size of the core also increases greatly in proceeding from the anterior to the midinsular level. In proceeding backward from the middle to the posterior insular level, the thalamus begins to predominate as the dominant gray matter in the core, and the mass of white matter, representing the posterior limb of the internal capsule, is much greater than in the anterior part of the core.

The core is attached to the remainder of the hemisphere by the cerebral isthmus. The isthmus is located deep to the circular sulcus of the insula. There is a portion of the isthmus deep to the full circumference of the circular sulcus. The anterior part of the isthmus that separates the circular sulcus and the frontal horn is formed by a relatively thin layer of white matter. In cross section, the lateral edge of the frontal horn and circular sulcus seem to project toward each other, separated only by the isthmus (Fig. 1.12, A–C). It is the same at the posterior isthmus, where the circular sulcus and atrium are separated by only the relatively thin layer of white matter forming the isthmus. The transverse temporal gyri converge posteriorly and medially toward the lateral edge of the isthmus. The lower isthmus that connects the temporal lobe to the remainder of the hemisphere is also referred to as the stem of the temporal lobe. The lower isthmus is positioned between the circular sulcus and the roof of the temporal horn. Opening through the isthmus with an incision directed slightly downward along the lower edge of the circular sulcus will expose the temporal horn, but at the midportion of the lower isthmus, the incision will cross the fibers of the optic and auditory radiations just lateral to where they leave the lateral and medial geniculate bodies. The upper part of the isthmus separates the upper part of the circular sulcus and the body of the

FIGURE 1.10. Continued

The rhinal and collateral sulci are frequently not continuous, although they are in this case. B, enlarged view. The posterior segment of the uncus is divided by the uncus notch into an upper and lower part. The lower part is formed by the parahippocampal gyrus and the upper part is formed predominantly by the hippocampal head. The dentate gyrus, at its anterior margin, blends into the upper part of the posterior segment. C, medial view of the uncus directed across the sella and tentorial edge. The carotid artery and middle cerebral artery face the anterior segment of the uncus. The posterior cerebral artery courses along the medial side of the posterior segment. The anterior choroidal artery ascends as it passes backward across the anterior segment to reach the upper part of the posterior segment. The anterior choroidal artery enters, and the inferior ventricular vein exits, the choroidal fissure by passing through the inferior choroidal point located just behind the head of the hippocampus and the posterior uncus segment. The inferior ventricular vein drains the roof of the temporal horn and empties in the basal vein. D, the medial part of the parahippocampal gyrus and the lower part of the posterior uncus segment have been removed to expose the dentate gyrus and the choroidal fissure. The beaded dentate gyrus blends into the posterior edge of the upper part of the posterior uncus segment and the medial side of the hippocampal head. E, additional parahippocampal gyrus has been removed while preserving the dentate gyrus to expose the choroid plexus in the temporal horn. The amygdala, partially enclosed in the anterior segment, forms the anterior wall of the temporal horn. F, inferior view of E. The part of the parahippocampal gyrus, lateral to the dentate gyrus, has been removed to expose the roof of the temporal horn, which is formed by the tapetum, the thin layer of fibers from the corpus callosum that separate the optic radiation from the wall of the temporal horn. The dentate gyrus and fimbria have been preserved. The choroid plexus is attached along the choroidal fissure located between the fimbria and lower margin of the thalamus. The inferior choroidal point at the lower end of the choroidal fissure is located behind the posterior uncus segment and the hippocampal head. The dentate gyrus and fimbria extend along the lateral edge of the lateral geniculate body. A.C.A., anterior cerebral artery; A.Ch.A., anterior choroidal artery; Ant., anterior; Chor., choroid, choroidal; CN, cranial nerve; Coll., collateral; Dent., dentate; Fiss., fissure; Gen., geniculate; Inf., inferior; Lat., lateral; M.C.A., medial cerebral artery; P.C.A., posterior cerebral artery; Parahippo., parahippocampal; Ped., peduncle; Perf., perforated; Plex., plexus; Post., posterior; Seg., segment; Subst., substance; Temp., temporal; Tent., tentorial; Tr., tract; V., vein; Vent., ventricular.

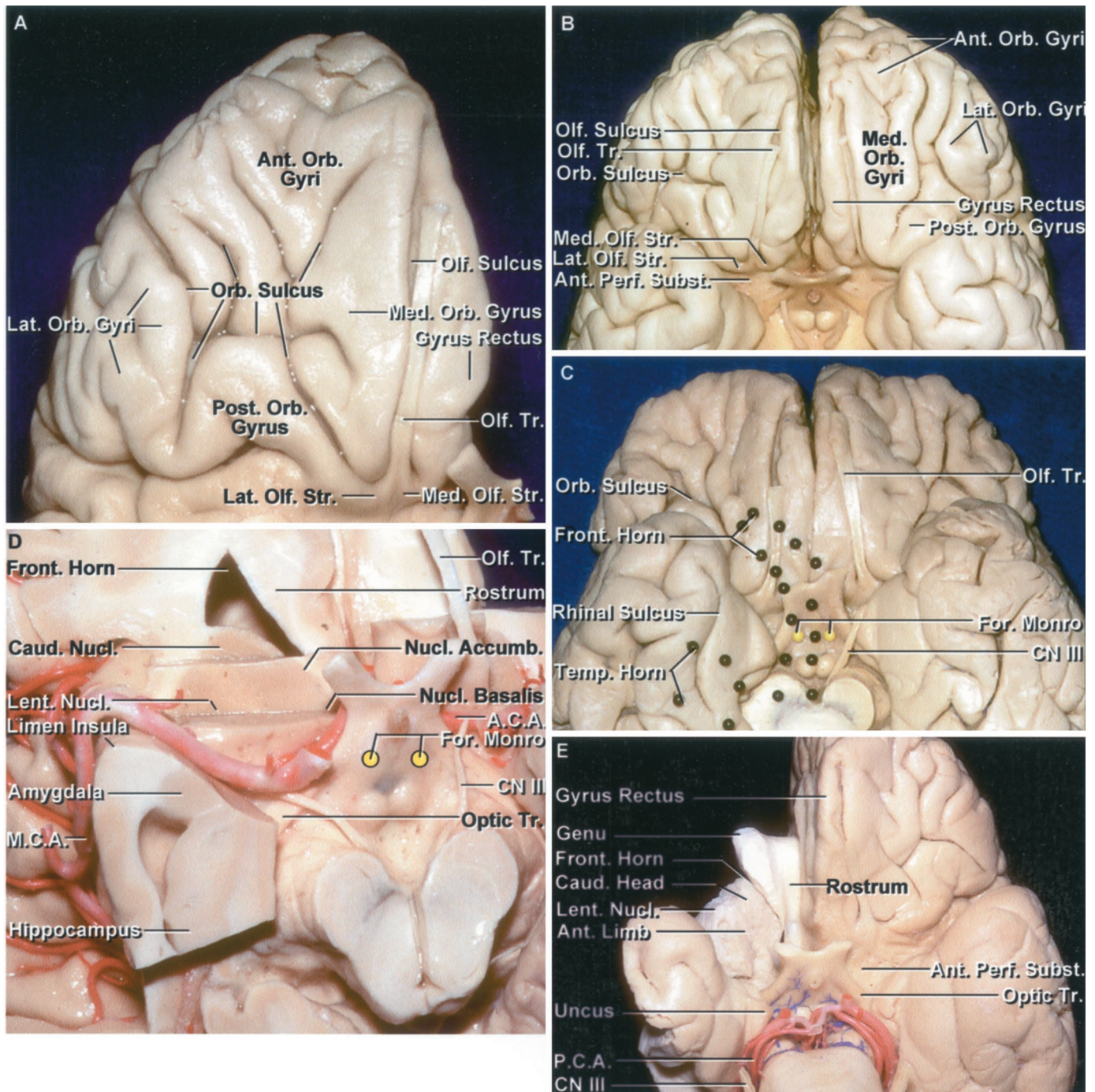


FIGURE 1.11. Orbital surface of the frontal lobe. A, the olfactory tract extends along the olfactory sulcus on the lateral side of the gyrus rectus and divides at the edge of the anterior perforated substance into the medial and lateral olfactory striae. The orbital surface lateral to the gyrus rectus is divided by an H-shaped sulcus into anterior, posterior, medial, and lateral orbital gyri. B, another cerebrum. The olfactory sulci separate the gyrus rectus medially from the orbital gyri laterally. The orbital surface lateral to the gyrus rectus is divided by a number of sulci that tend to form an H-shaped configuration and divide the area into anterior, posterior, medial, and lateral orbital gyri. The most lateral of the lateral orbital gyri is continuous with the pars orbitalis of the inferior frontal gyrus. C, orbital surfaces of another hemisphere. The location of the frontal and temporal horns deep within the hemisphere has been outlined using colored black pins. The frontal horn extends forward in the frontal lobe to approximately the level of the transverse part of the H-shaped orbital sulcus. The deep site of the foramen of Monro, shown with yellow pins, in relationship to the basal surface is anterior to the mammillary bodies. D, the lower part of the right frontal lobe has been removed to expose the frontal horn. The caudate nucleus forms the lateral wall of the frontal horn and the rostrum of the corpus callosum forms the floor. At a more superior axial level, the caudate and lentiform nuclei are separated by the anterior limb of the internal capsule, but at this level below the anterior limb of the internal capsule, the nuclei form a solid, unbroken mass of gray (Legend continues on next page.)

lateral ventricle and is thicker than at the other sites. The upper isthmus also contains the fibers forming the internal capsule.

Opening directly through the superior, posterior, and inferior margins of the isthmus risks damaging important motor, somatosensory, visual, and auditory pathways. Opening the anterior part of the isthmus carries less risk than opening the middle and posterior parts. Yaşargil and Wieser (11) reach the amygdala for amygdalohippocampectomy using a 1- to 2-cm incision through the circular sulcus and the lower isthmus just behind the limen insula. A number of operative routes that access various surfaces of the central core should be considered before transecting a part of the isthmus. These approaches, directed along the sylvian or interhemispheric fissures, between the basal surface of the hemisphere and cranial base, or through the lateral ventricle, provide multiple routes that access various surfaces and part of the central core. The

routes to these deep areas are reviewed further below, in the discussion, and also in Chapter 5.

WHITE MATTER

The white matter of the cerebrum underlies the outer lamina of gray matter, intervenes between the cortical gray matter and the gray matter of the basal ganglia, and encases the ventricles (Figs. 1.7, 1.15, and 1.16). In a horizontal section above the corpus callosum, the subcortical white matter in each hemisphere forms a semiovoid mass called the centrum semiovale. The white matter contains three types of fibers: association fibers interconnecting different cortical regions of the same hemisphere, commissural fibers interconnecting the two hemispheres across the median plane, and projection fibers passing up and down the neuraxis and connecting the cortex with caudal parts of the brain and spinal cord. The

FIGURE 1.11. Continued

matter located above the anterior perforated substance and adjoining part of the orbital surface. In addition, the lentiform and caudate nuclei blend medially without a clear border into the nucleus basalis and nucleus accumbens. The nucleus basalis is located in the medial part of this gray mass below the anterior commissure, and the nucleus accumbens is situated in front of the nucleus basalis. The amygdala is located below and blends into the lentiform nucleus at its upper border. E, fiber dissection of the right hemisphere showing the relationship of the genu and rostrum of the corpus callosum to the orbital surface. The anterior margin of the genu of the corpus callosum is located above the midportion of the basal surface. The rostrum of the corpus callosum forms the floor of the frontal horn. The genu, along with its large fiber bundle, the forceps minor, forms the anterior wall of the frontal horn. The caudate nucleus forms the lateral wall of the frontal horn. The basal side of the caudate nucleus and the lentiform nucleus, formed by the putamen and globus pallidus, blend together in the area below the anterior limb of the frontal capsule to form a globular mass of gray matter that extends almost unbroken from the lower part of the frontal horn to the insula. At a more superior level, the anterior limb of the internal capsule cuts into the interval between the caudate and lentiform nuclei dividing them into separate nuclei. A.C.A., anterior cerebral artery; Accumb., accumbens; Ant., anterior; Caud., caudate; CN, cranial nerve; For., foramen; Front., frontal; Lat., lateral; Lent., lentiform; M.C.A., medial cerebral artery; Med., medial; Nucl., nucleus; Olf., olfactory; Orb., orbital; P.C.A., posterior cerebral artery; Perf., perforated; Post., posterior; Str., stria; Subst., substance; Temp., temporal; Tr., tract.

FIGURE 1.12. Central core of the hemisphere. A, superior view. The central core is the portion located between the insular surface laterally and the lateral and third ventricles medially. We refer to the narrow strip of white matter deep to the circular sulcus and connecting the central core to the remaining hemisphere as the cerebral isthmus. The isthmus, at the margin of the core, conveys all the fibers related to all of the motor and sensory pathways, including those that form the internal capsule and optic radiations. The anterior margin of the circular sulcus is separated from the frontal horn by the relatively thin anterior part of the isthmus, and the posterior margin of the circular sulcus is separated from the atrium by the narrow posterior part of the isthmus. The upper margin of the isthmus separating the upper margin of the circular sulcus and the lateral ventricle is somewhat thicker than the anterior or posterior margin of the isthmus. The transverse temporal gyri, the most anterior of which is Heschl's gyrus, are located lateral to the posterior margin of the insula on the planum temporale. An area without gyri anterior to the planum temporale on the anterior part of the upper surface of the temporal lobe, called the planum polare, faces the anterior part of the lateral surface of the insula. The transverse temporal gyri radiate forward and laterally from the posterior isthmus located lateral to the atrium. The sylvian point, the site at which the last insular branch of the middle cerebral artery turns laterally from the insula, is located lateral to the posterior isthmus and the posterior part of the circular sulcus. B, superior view of the central core and the anterior and posterior parts of the cerebral isthmus. The transverse temporal gyri seem to radiate laterally and forward from an apex situated lateral to the atrium, the posterior part of the circular sulcus, and the posterior isthmus. The section extends through the anterior and posterior limb and genu of the internal capsule, thalamus, and lentiform and caudate nuclei. The thalamus is located directly above the midbrain in the center of the tentorial incisura. C, superolateral view of the insula, circular sulcus, and the anterior and posterior isthmi. The circular sulcus extends completely around the margin of the insula and is located superficial to the white matter forming the cerebral isthmus. The isthmus is the thinnest area between the insular and ventricular surfaces. D, the upper surface of the left temporal lobe has been retracted to expose the lower part of the circular sulcus and isthmus located deep to the circular sulcus. An incision extending through the thin isthmus at the lower margin of the circular sulcus will expose the temporal horn, but will also cut across the optic and auditory radiations and the sublenticular part of the internal capsule, unless only a short segment of the anterior part of the lower isthmus is opened. E, lateral view of the central core. The cerebral hemisphere has been removed by dividing the isthmus, located deep to the circular sulcus and extending around the margin of the insula. The corpus callosum and fibers crossing the midline were also divided. Middle cerebral branches course along the insular surface. The lower margin of the circular sulcus is located deep to the superior temporal sulcus. F, all of the central core has been removed. It includes the caudate and lentiform nuclei, thalamus, and some of the corona radiata and internal capsule. The medial part of the core has been separated from the ventricular surface by opening the choroidal fissure, the natural cleft and cleavage plane between the thalamus and fornix. The body, crus, and fimbria of the fornix form the outer border of the choroidal fissure. The transverse temporal gyri, forming the planum temporale, radiate forward from the posterior edge of the circular sulcus located lateral to the atrium. The quadrigeminal cistern is located medial to the crus of the fornix. A.C.A., anterior cerebral artery; Ant., anterior; Call., callosum; Cap., capsule; Caud., caudate; Circ., circular; Cist., cistern; Corp., corpus; Front., frontal; Int., internal; Lat., lateral; Lent., lentiform; M.C.A., medial cerebral artery; Nucl., nucleus; Post., posterior; Quad., quadrigeminal; Seg., segment; Str., straight; Temp., temporal, temporale; Tent., tentorial; Trans., transverse; Vent., ventricle.

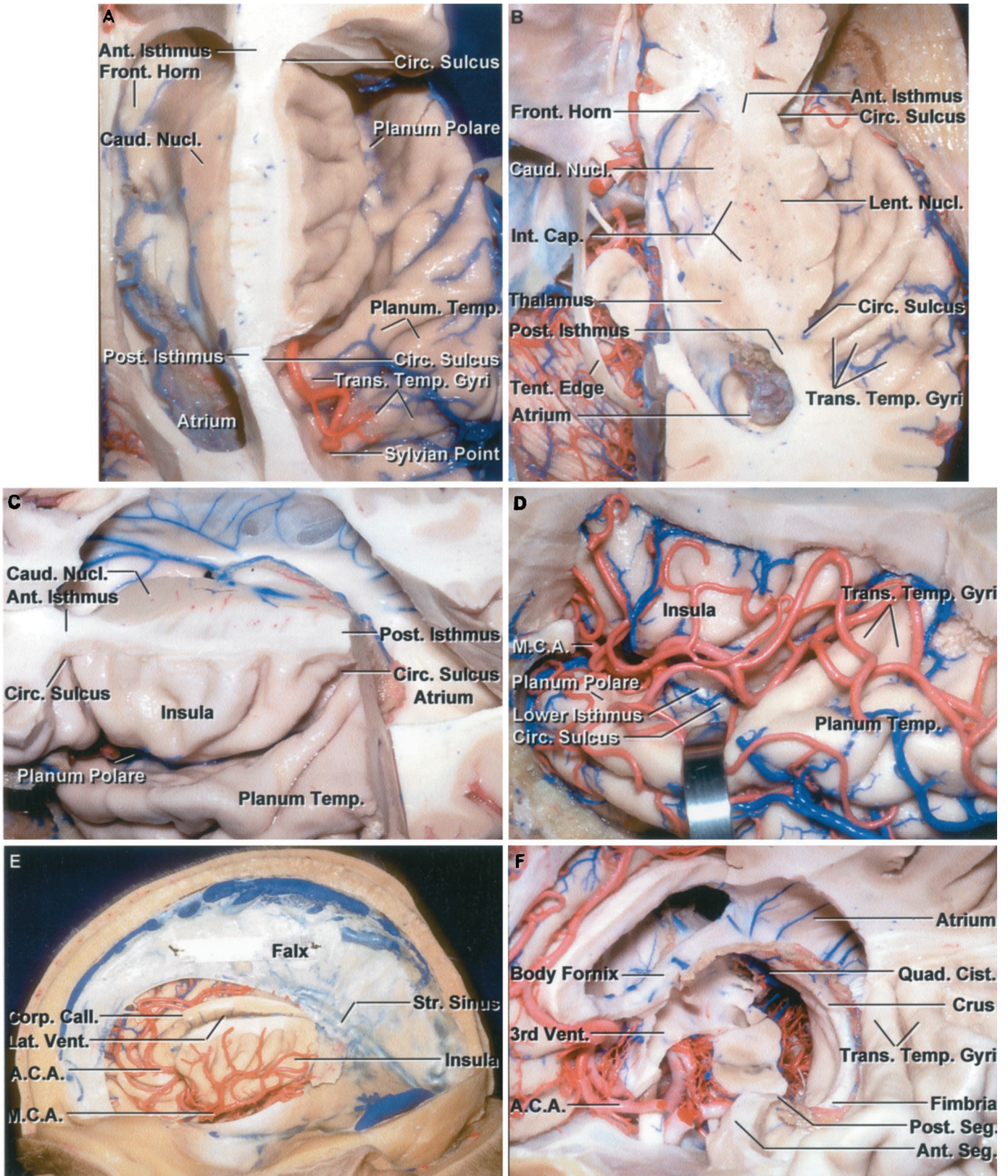


FIGURE 1.12.

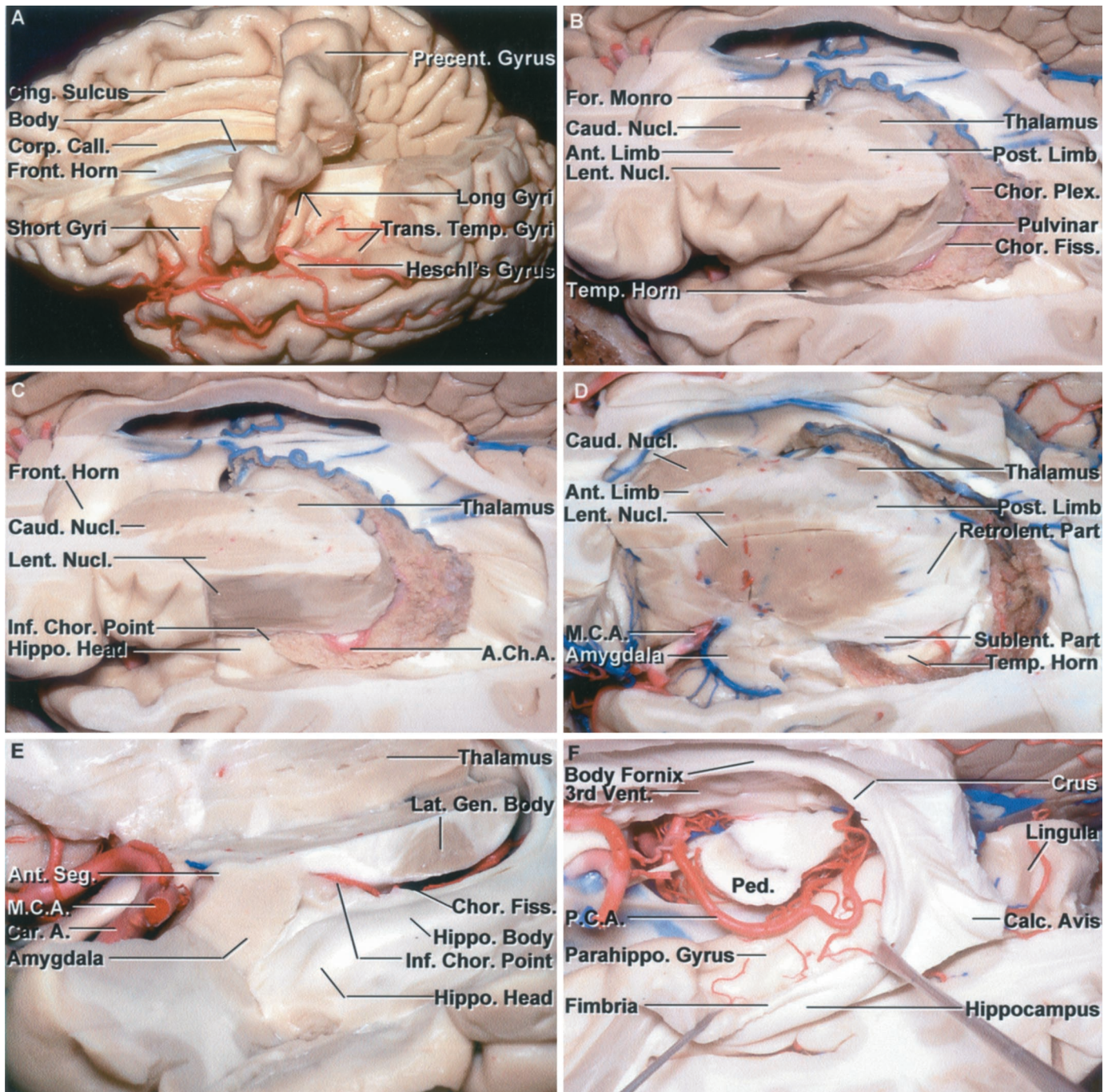


FIGURE 1.13. Stepwise dissection of the central core of the hemisphere. A, superior view. The central core is the part of the cerebrum located between the insula and the third and lateral ventricles. The upper part of the left hemisphere, except the precentral gyrus, has been removed to expose the frontal horn and body of the ventricle. The precentral gyrus is located lateral to the posterior part of the body of the ventricle and lateral to the splenium of the corpus callosum. The postcentral gyrus, which has been removed, faces the most anterior of the transverse temporal gyri, called Heschl's gyrus. The short insular gyri are exposed anterior to and the long gyri behind the precentral gyrus. B, the axial section extending through the central core crosses the anterior and posterior limb and genu of the internal capsule, the thalamus, and the lentiform and caudate nuclei at the level of the foramen of Monro. The lateral wall of the atrium and the roof of the temporal horn have been removed by dividing the white matter along the circular sulcus of the insula. C, the posterior part of the lateral surface of the insula has been removed to expose the lateral surface of the lentiform nucleus. The choroid plexus is attached along the choroidal fissure that extends from the foramen of Monro to the inferior choroidal point located just behind the head of the hippocampus. D, the anterior part of the insular cortex has been removed to expose the lentiform nucleus in the area above and behind the sylvian fissure, and above the anterior perforated substance and temporal horn. The middle cerebral artery, in the stem of the sylvian fissure, passes below the anterior part of the caudate and lentiform nuclei. The sublenticular and retrolenticular parts of the internal capsule, including the optic and auditory radiations, pass below and behind the lentiform nucleus.

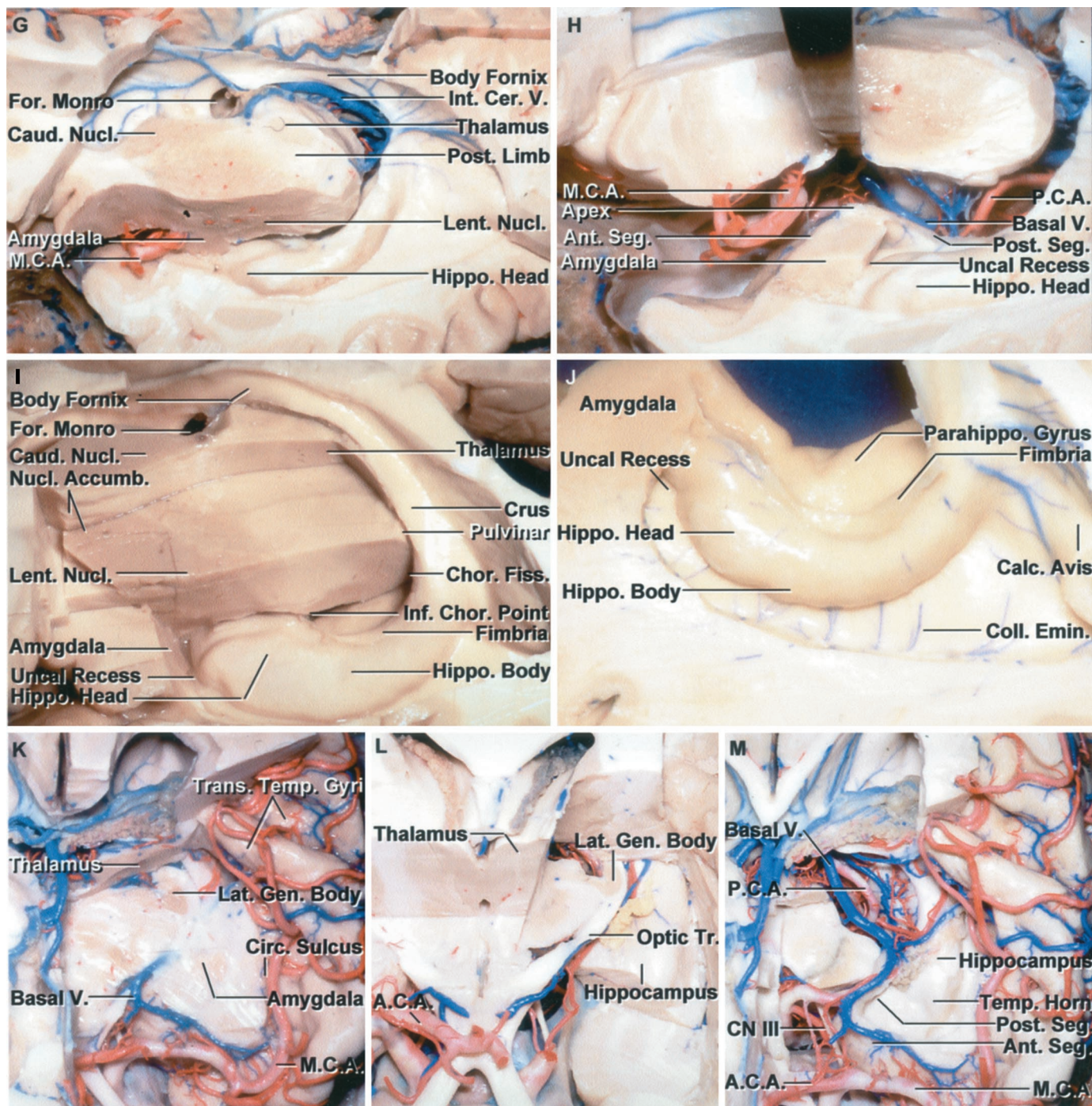


FIGURE 1.13. Continued

The anterior limb of the internal capsule is located between the caudate and lentiform nuclei, and the posterior limb is positioned between the lentiform nucleus and thalamus. E, enlarged view of the lower margin of the thalamus and upper part of the uncus. The anterior segment of the uncus contains the amygdala and faces the carotid and middle cerebral arteries. The posterior segment of the uncus contains the head of the hippocampus and is located anterior to the lower end of the choroidal fissure. The lateral geniculate body is located just above the choroidal fissure and body of the hippocampus. The choroidal fissure, along which the choroid plexus is attached, is located between the fimbria and the thalamus. The inferior choroidal point, the lower end of the choroidal fissure, is located behind the hippocampal head. F, the thalamus has been removed and the fimbria of the fornix retracted laterally to expose the parahippocampal gyrus medial to the fimbria. The posterior cerebral artery courses through the crural and ambient cisterns on the medial side of the parahippocampal gyrus. The upper lip of the calcarine sulcus, formed by the cuneus, has been removed to expose the lower lip formed by the lingula. The deep end of the calcarine sulcus forms a prominence, the calcar avis, in the medial wall of the atrium. G, another hemisphere. (Legend continues on next page.)

fornix, which contains both projection and commissural fibers, is considered below, under Commissural Fibers.

Association Fibers

Association fibers are of two types: short arcuate fibers that interconnect adjacent gyri and long arcuate fibers that interconnect widely separated gyri. The long arcuate fibers are situated deep to the short fibers and form several bundles. In our dissections of the white matter, the uncinata, cingulum, and superior longitudinal fasciculi have been the most distinct and identifiable (Figs. 1.15 and 1.16). Another association fiber bundle encountered in the ventricular margin is the stria terminalis (Figs. 1.7 and 1.16M). It arises in the amygdala and courses along the border between the caudate nucleus and the thalamus in the wall of the lateral ventricle deep to the thalamostriate vein.

Uncinate Fasciculus

The uncinata fasciculus is a hook-shaped bundle of fibers that curves around the stem of the sylvian fissure and connects the frontal and temporal lobes (Figs. 1.15 and 1.16). It is located at the lateral edge of the anterior perforated substance bordering the anteroinferior part of the insula. Its fibers course through the limen insulae and produce the prominence at the junction of the sphenoidal and operculoinular compartments of the sylvian fissure. The uncinata fasciculus has an upper and a lower component. The lower part connects the gyri on the orbital surface of the frontal lobe with the parahippocampal and other gyri on the medial surface of the temporal lobe. The upper component unites gyri on the superolateral part of the frontal lobe with the cortex of the more lateral temporal gyri near the temporal pole.

Cingulum

The cingulum courses along the medial aspect of the cerebral hemisphere, following the curve of and forming much of the white matter within the cingulate gyrus (Fig. 1.7). It contains long- and short-association fibers that follow the curve of the cingulate gyrus and corpus callosum. It interconnects the subcallosal and paraolfactory areas located below the anterior part of the corpus callosum, the cingulate gyrus above the corpus callosum, and the isthmus of the cingulate sulcus and parahippocampal gyri located behind and below the corpus callosum.

Superior Longitudinal Fasciculus

The superior longitudinal fasciculus, the largest of the bundles, is located along the upper and lateral border of the lentiform nucleus and insula (Figs. 1.15 and 1.16). It arches backward from the frontal lobe lateral to the internal capsule and through the parietal to the occipital lobe, where it arches downward and forward to reach the temporal lobe. Less distinct fasciculi seen on our fiber dissections include the inferior longitudinal fasciculus that courses near but separated from the walls of the temporal and occipital horns by the optic radiations and the tapetum of the corpus callosum, and interconnects the occipital and temporal lobes. Other less distinctive and deeper bundles interconnect the frontal, occipital, and temporal lobes.

Projection Fibers

The projection fibers pass up and down the neural axis. Above the level of the thalamus, these projection fibers are arranged in a radiating pattern called the corona radiata (Figs. 1.15 and 1.16). The corona are continuous caudally with the more compact internal capsule whose fibers collect to form the

FIGURE 1.13. Continued

The choroid plexus has been removed to expose the choroidal fissure located between the thalamus and fornix. The lateral part of the body of the fornix has been removed to expose the internal cerebral veins in the roof of the third ventricle. The nuclear mass, formed by the caudate and lentiform nuclei, extends above the middle cerebral artery and the roof of the stem of the sylvian fissure, formed by the anterior perforated substance and posterior part of the frontal lobe. The amygdala is positioned behind and below the middle cerebral artery. H, the incision has been extended forward from the inferior choroidal point through the amygdala. The amygdala occupies the anterior segment of the uncus and is crossed on its upper anterior surface by the middle cerebral artery. The head of the hippocampus blends into the posterior uncus segment. The middle cerebral artery courses above the anterior uncus segment and the posterior cerebral artery and basal vein course medial to the posterior segment. I, much of the thalamus has been removed to expose the body, crus, and fimbria of the fornix forming the outer margin of the choroidal fissure. The axial section extends through the area below the anterior limb of the internal capsule and anterior commissure where the caudate and lentiform nuclei and the nucleus accumbens and basalis blend together to form a massive collection of gray matter above the posterior part of the orbital surface of the frontal lobe and anterior perforated substance. J, axial sections through the temporal lobe and the anterior and posterior segments of the uncus. The amygdala fills the anterior segment and the head of the hippocampus fills the upper part of the posterior segment. The fimbria arises on the surface of the hippocampus. The parahippocampal gyrus extends medially below the hippocampus. The collateral eminence overlies the deep end of the collateral sulcus that runs along the basal surface on the lateral side of the parahippocampal gyrus. The hippocampus meets the calcar avis in the anterior part of the atrium. K, anterosuperior view. The axial section of the left hemisphere extends through the sylvian fissure, lateral geniculate body, amygdala, and the thin layer of white matter in the temporal stem below the lower edge of the circular sulcus. L, the cross sections extend along the optic tract and through the lower margin of the thalamus. The optic tract passes lateral to the lower margin of the thalamus to reach the lateral geniculate body. M, the optic tract and the thin layer of gray and white matter at the lower margin of the insula and circular sulcus that forms the stem of the temporal lobe have been removed to expose the temporal horn and the cisterns between the midbrain and parahippocampal gyrus. The anterior segment of the uncus faces the carotid and middle cerebral arteries. The apex faces the oculomotor nerve. The posterior segment faces the cerebral peduncle, crural cistern, posterior cerebral artery, and basal vein. A., artery; A.C.A., anterior cerebral artery; A.Ch.A., anterior choroidal artery; Accumb., accumbens; Ant., anterior; Calc., calcar; Call., callosum; Car., carotid; Caud., caudate; Cer., cerebral; Chor., choroid, choroidal; Cing., cingulate; Circ., circular; CN, cranial nerve; Coll., collateral; Corp., corpus; Emin., eminence; Fiss., fissure; For., foramen; Front., frontal; Gen., geniculate; Hippo., hippocampal; Inf., inferior; Int., internal; Lat., lateral; Lent., lentiform; M.C.A., medial cerebral artery; Nucl., nucleus; P.C.A., posterior cerebral artery; Parahippo., parahippocampal; Ped., peduncle; Plex., plexus; Post., posterior; Precent., precentral; Retrolent., retrolenticular; Seg., segment; Sublent., sublenticular; Temp., temporal; Tr., tract; Trans., transverse; V., vein; Vent., ventricle.

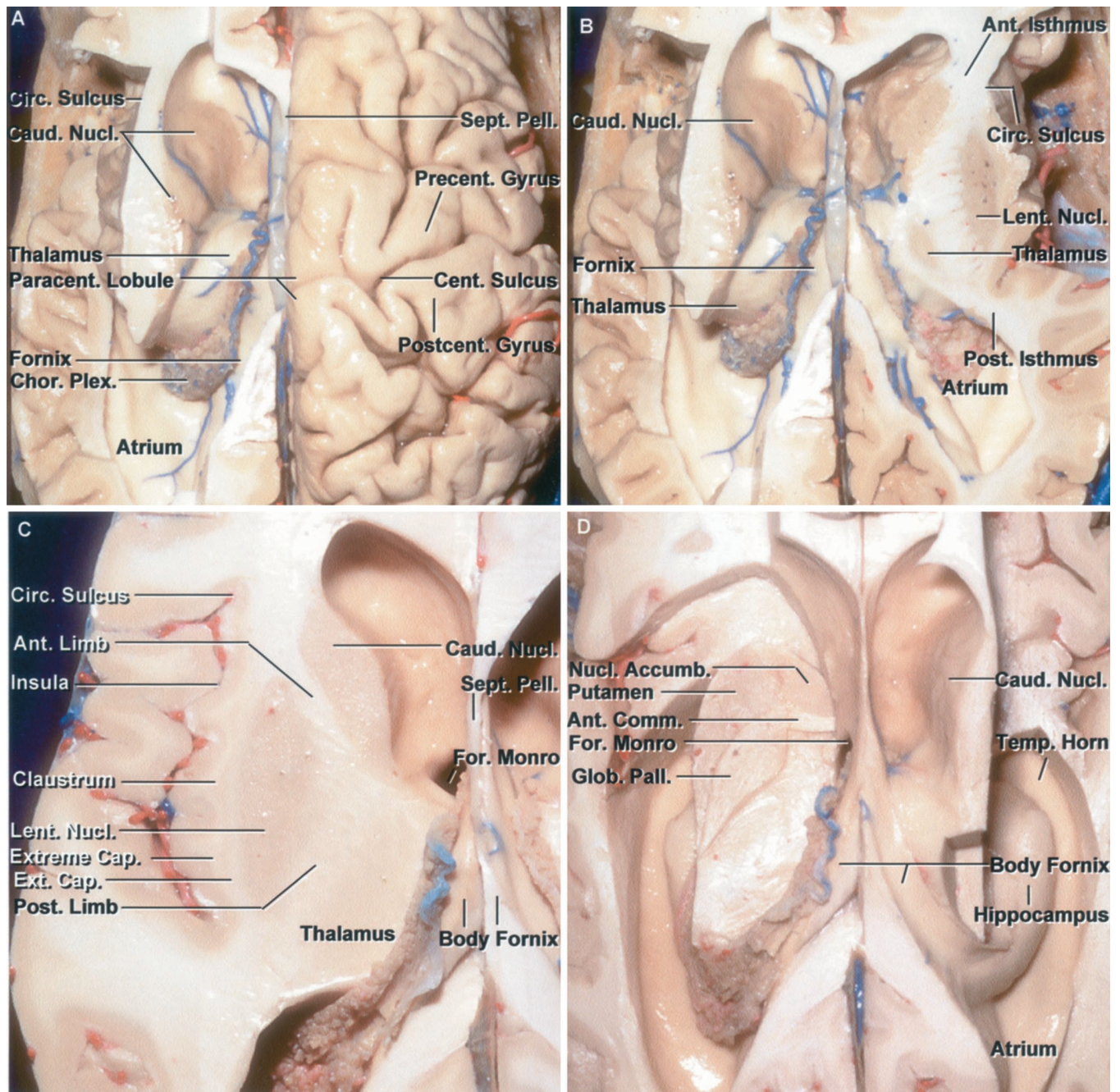


FIGURE 1.14. Axial cross sections of the cerebral hemisphere and central core. A, superior view. The part of the left hemisphere above the upper edge of the insula and circular sulcus has been removed. The central sulcus ascends on the right hemisphere and intersects the superior margin of the hemisphere above the posterior part of the body of the lateral ventricle. The upper part of the body of the caudate that extends above the level of the upper margin of the circular sulcus has been removed. Anteriorly, the circular sulcus is located superficial to the anterior edge of the caudate head. The posterior edge of the circular sulcus is situated lateral to the anterior wall of the atrium. B, the section of the right hemisphere has been extended through the upper part of the lentiform nucleus, thalamus, and caudate head. On the left side, the axial section remains at the level of the upper edge of the circular sulcus. The anterior part of the cerebral isthmus is located between the frontal horn and anterior part of the circular sulcus and the posterior part is located between the posterior part of the circular sulcus and the anterior part of the atrium. C, the external and extreme capsule and the claustrum fill the interval between the insula and the lentiform nucleus. The axial section in the left hemisphere extends through the internal capsule just above and lateral to the foramen of Monro where the genu of the capsule reaches the ventricular surface. The anterior limb of the internal capsule is separated from the frontal horn by the caudate nucleus and the posterior limb is separated from the body of the ventricle by the thalamus, but the genu reaches the ventricular surface lateral to the foramen of Monro. D, the section through the left hemisphere has been extended downward below the frontal horn to the level of the anterior commissure. The anterior part of the section extends through the deep gray matter below the frontal horn anterior limb of the internal capsule. At higher levels, the lentiform (Legend continues on next page.)

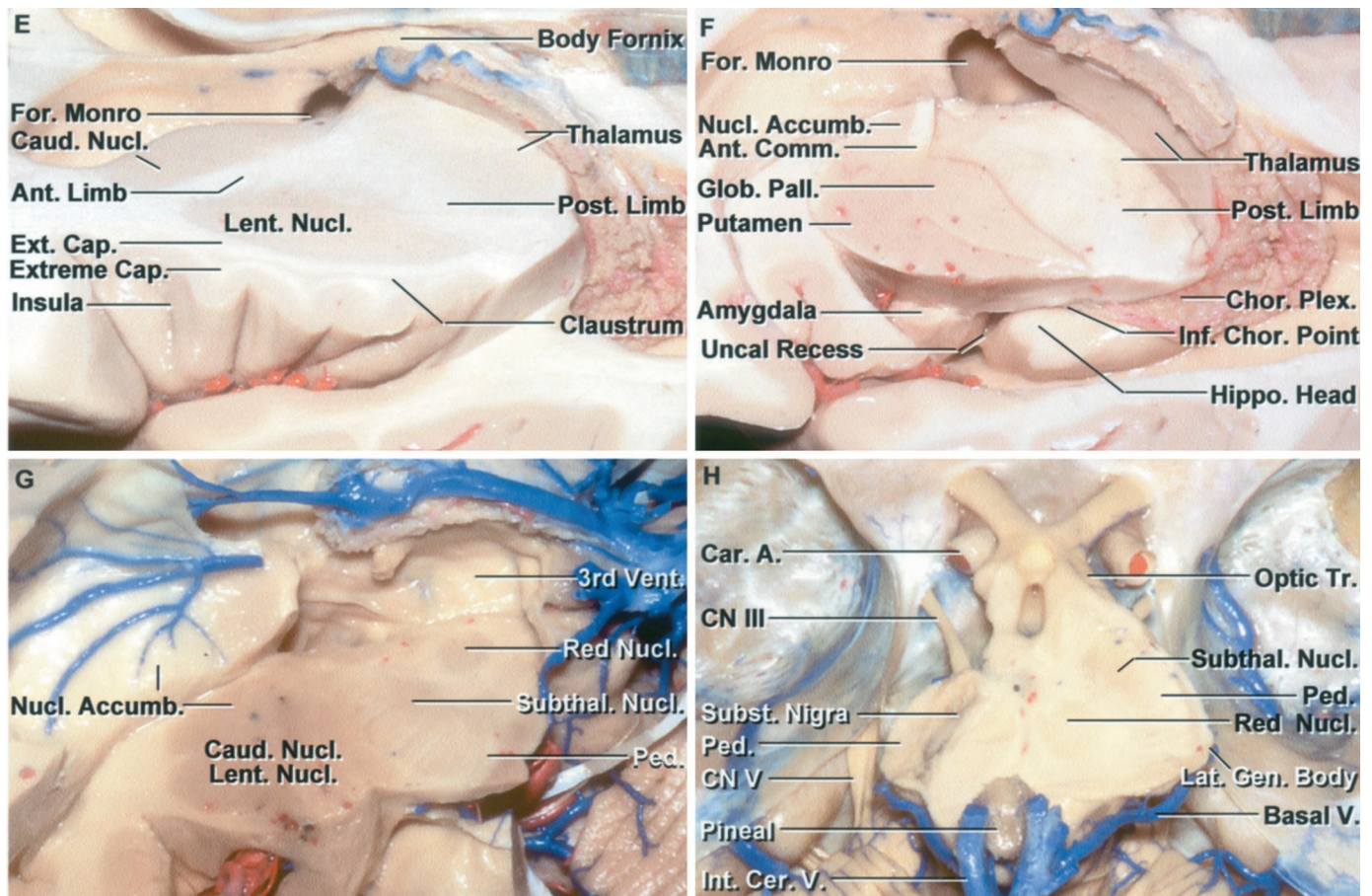


FIGURE 1.14. Continued

and caudate nuclei are separated by the anterior limb of the internal capsule, but at this level below the anterior limb of the internal capsule, the two nuclei blend into a mass of gray matter located above the anterior perforated substance and adjacent part of the orbital surface of the frontal lobe. The caudate and lentiform nuclei blend into the nucleus basalis located below the anterior commissure and the nucleus accumbens situated anterior to the nucleus basalis to form a massive collection of gray matter in the basal part of the hemisphere. E, superolateral view at the foramen of Monro showing the genu of the capsule reaching the ventricular surface lateral to the foramen of Monro. F, superolateral view of the section at the level of the anterior commissure. At this level below the frontal horn and anterior limb of the internal capsule, and above the anterior perforated substance, the putamen, lentiform nucleus, globus pallidus, and caudate head blend into a large mass of gray matter. The posterior limb of the internal capsule, located between the lentiform nucleus and the thalamus, is still present in the cross section even though the anterior limb is absent. In coronal cross sections, the lentiform nucleus is typically lens-shaped, but in the axial cuts, as shown here, the lentiform nucleus, composed of the putamen and globus pallidus, has a tear-drop shape with a broad, rounded head anteriorly and a pointed tail posteriorly. The amygdala and head of the hippocampus, separated by the uncus recess, are exposed below the lentiform nucleus. G, superolateral view of a cross section extending below the frontal horn and through the red and subthalamic nuclei and upper part of the cerebral peduncle. At this level, just above the anterior perforated substance, the lentiform and caudate nuclei blend into the nucleus basalis and accumbens to create a large collection of gray matter. The red nucleus is located in the center of the midbrain. The right subthalamic nucleus is a lens-shaped nucleus situated in the interval between the cerebral peduncle and the midbrain. H, the part of the basal surface of the frontal lobe above the Sylvian fissure has been removed to expose the upper edge of the cerebral peduncles and the red and subthalamic nuclei located just behind the peduncle. The optic tract passes laterally around the upper margin of the cerebellar peduncle. The left half of the brainstem has been sectioned obliquely to expose the substantia nigra located just below the subthalamic nucleus. A., artery; Accumb., accumbens; Ant., anterior; Cap., capsule; Car., carotid; Caud., caudate; Cent., central; Cer., cerebral; Chor., choroid, choroidal; Circ., circular; CN, cranial nerve; Comm., commissure; Ext., external; For., foramen; Gen., geniculate; Glob., globus; Hippo., hippocampal; Inf., inferior; Int., internal; Lat., lateral; Lent., lentiform; Nucl., nucleus; Pall., pallidus; Paracent., paracentral; Ped., peduncle; Pell., pellucidum; Plex., plexus; Post., posterior; Postcent., postcentral; Precent., precentral; Sept., septum; Subst., substantia; Subthal., subthalamic; Temp., temporal; V., vein; Vent., ventricle.

cerebral peduncle. The internal capsule is a thick mass of white matter that is bounded laterally by the lentiform nucleus and medially by the caudate nucleus and the thalamus. The internal capsule has anterior and posterior limbs, a genu, and retro- and sublenticular parts. The internal capsule bends at a

right angle around the medial margin of the pallidal part of the lentiform nucleus to form an anterior limb, located between the caudate nucleus medially and the lentiform nucleus laterally, and a posterior limb, interposed between the thalamus medially and the lentiform nucleus laterally. The two

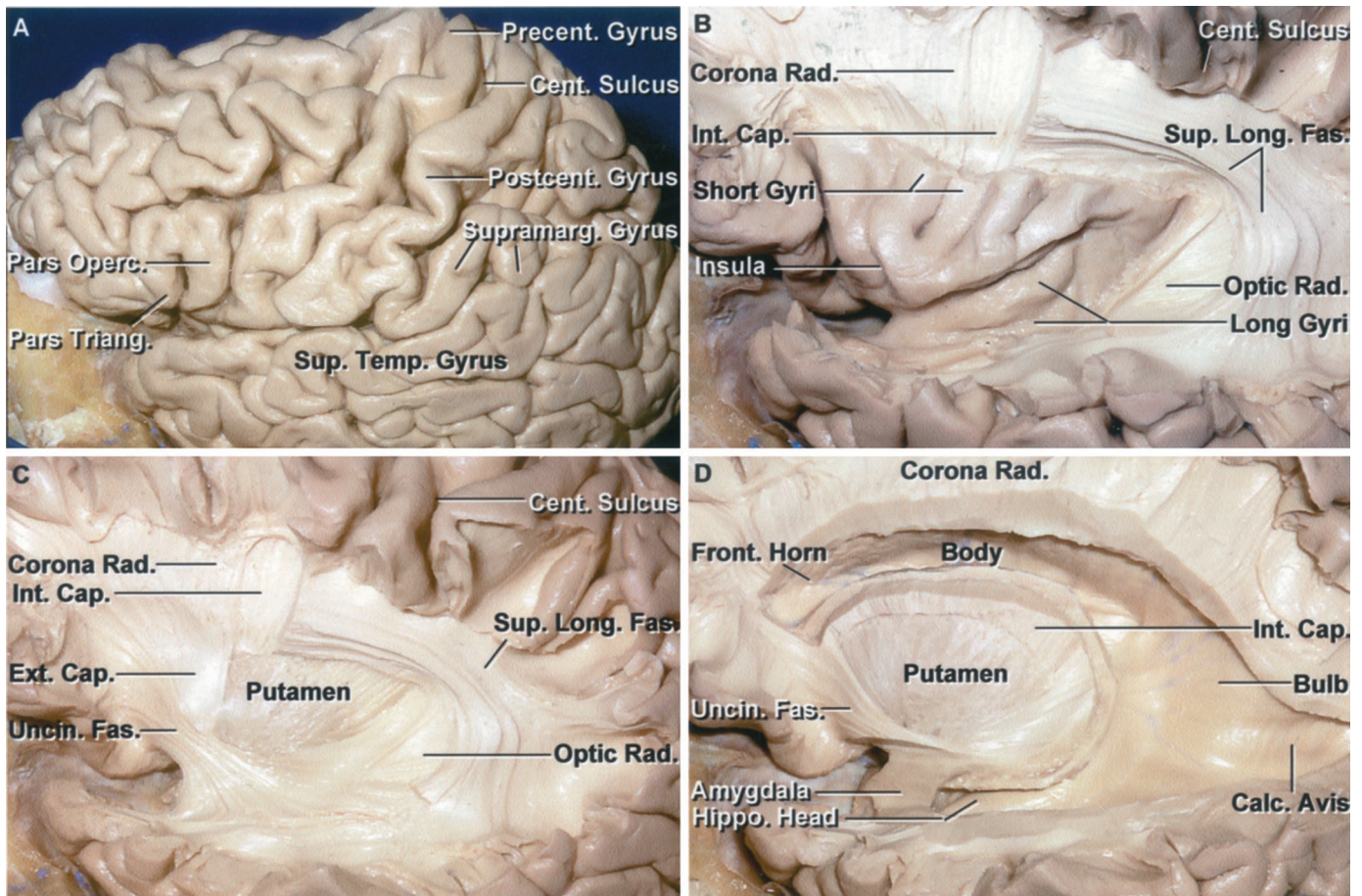


FIGURE 1.15. Stepwise fiber dissection. A, left cerebral hemisphere. The pre- and postcentral gyri adjoin the central sulcus. The precentral gyrus is located behind the pars opercularis and the postcentral gyrus is located in front of the supramarginal gyrus. B, the frontal, parietal, and temporal opercula have been removed to expose the insula. The corona radiata and some of the fibers joining the internal capsule are exposed above the insula. The insular surface is composed of long and short gyri. The superior longitudinal fasciculus courses around the outer margin of the insula and lentiform nucleus. The retrolenticular part of the optic radiations are exposed behind the insula and deep to the superior longitudinal fasciculus. C, the claustrum and the posterior part of the external capsule have been removed to expose the putamen. The anterior part of the external capsule has been preserved. The uncinate fasciculus interconnects the frontal and temporal lobes. The retrolenticular part of the optic radiations is exposed behind the lentiform nucleus. The superior longitudinal fasciculus courses superficial to the optic radiations and deep to the extreme and external capsules. D, the frontal horn, body, atrium, and temporal horn of the lateral ventricle have been exposed. The fibers of the external capsule superficial to the putamen have been removed. The internal capsule courses medial to the lentiform nucleus, the outer segment of which is formed by the putamen. The lower part of the uncinate fasciculus has been removed to expose amygdala and the head of the hippocampus. The amygdala forms the anterior wall of the temporal horn. The calcar avis, overlying the deep end of the calcarine sulcus, and the bulb of the corpus callosum, overlying the fibers of the forceps major, are exposed in the medial wall of the atrium. (Legend continues on next page.)

limbs join at the genu, where the fibers wrap around the medial apex of the globus pallidus. The medially directed apex is located lateral to the foramen of Monro, where the fibers in the genu reach the wall of the ventricle in the interval between the caudate nucleus and thalamus. The anterior limb is composed predominantly of fibers that connect the anterior and medial thalamus and the pontine nuclei to the frontal lobe. The genu of the internal capsule, in addition to the corticothalamic and thalamocortical fibers, contains corticobulbar fibers to the motor nuclei of the cranial nerves. The posterior limb, in addition to fibers interconnecting the thalamus and cortex, contains the corticospinal fibers to the motor nuclei of the upper and lower extremity and trunk. The fibers

to the arm are nearer the genu than those coursing to the leg. The precentral gyrus is positioned superficial to the posterior limb.

Some fibers of the internal capsule curve around the posterior edge of the lentiform nucleus and are referred to as the retrolenticular fibers and others pass below the lentiform nucleus and are referred to as sublenticular fibers. The sublenticular part of the posterior limb contains the auditory radiation fibers directed from the medial geniculate body to the auditory area in the transverse temporal and adjacent parts of the superior temporal gyri and part of the optic radiations that course from the lateral geniculate to the walls of the calcarine sulcus. Some optic radiation fibers also pass through the re-

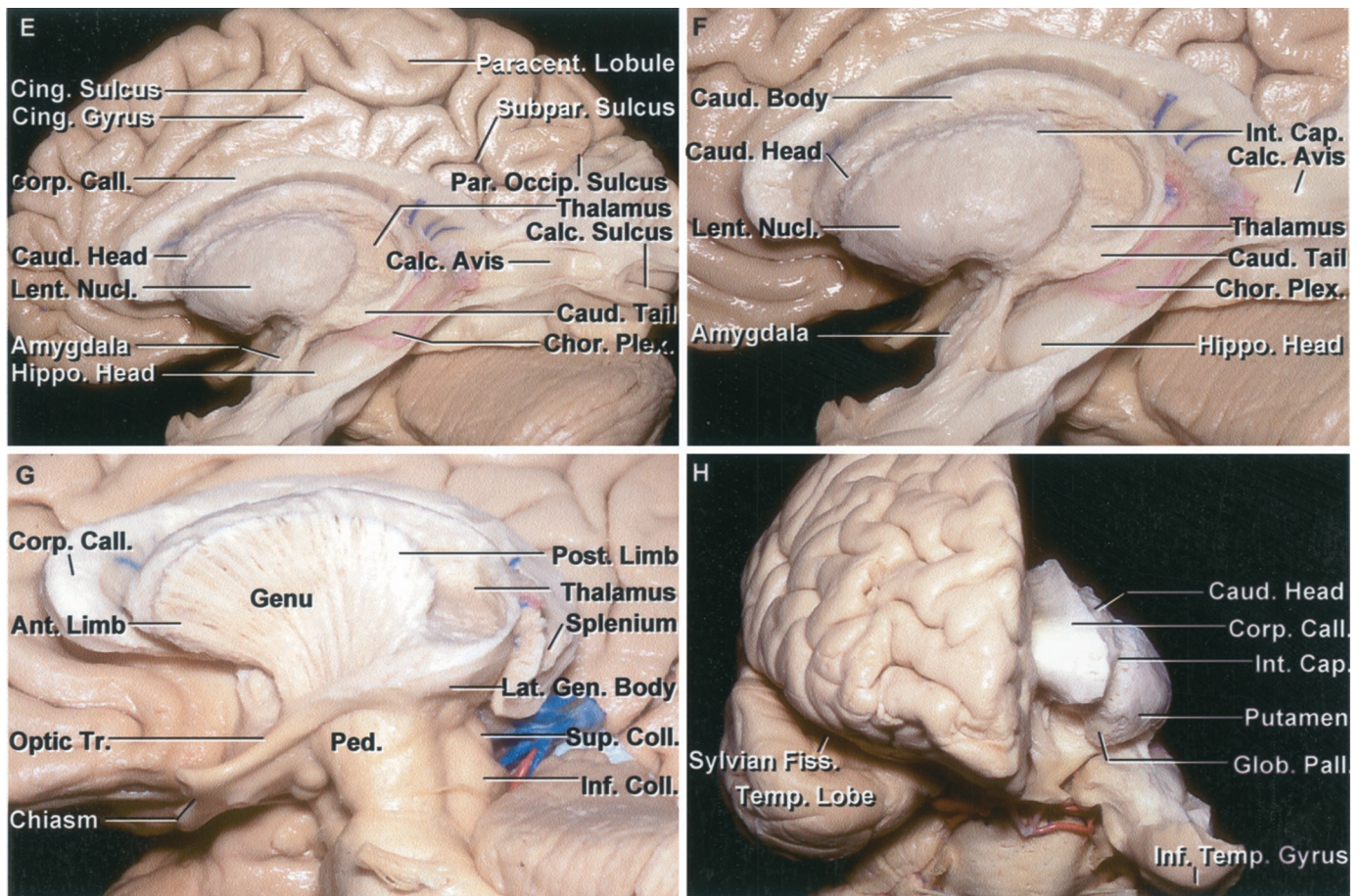


FIGURE 1.15. *Continued*

E, the fibers of the internal capsule that course between the posterior part of the lentiform nucleus and thalamus have been removed. The anterior limb of the internal capsule descends between the caudate head and lentiform nucleus and the posterior limb passes between the lentiform nucleus and thalamus. The head, body, and tail of the caudate nucleus are exposed in the wall of the ventricle. The tail of the caudate nucleus extends along the lateral edge of the thalamus. The head of the hippocampus is located in the floor of the temporal horn. The amygdala forms the anterior wall of the temporal horn. F, enlarged view. Some of the ependyma over the calcar avis has been removed. The choroid plexus is attached along the choroidal fissure. G, lateral view. The lentiform nucleus has been removed to expose the internal capsule. The anterior limb courses between the caudate nucleus and lentiform nucleus and has a darker color than the posterior limb because of the bridges of transcapsular gray matter extending across the internal capsule between the caudate and lentiform nuclei. The posterior limb of the internal capsule is located lateral to the thalamus. The optic tract passes backward to reach the lateral geniculate body. The fibers of the internal capsule descend to form the cerebral peduncle located medial to the optic tract. The superior and inferior colliculi are exposed in the quadrigeminal cistern. H, anterior view of dissection shown in G. The putamen and globus pallidus are positional on the lateral side of the internal capsule and the caudate nucleus is on the medial side. The anterior limb of the internal capsule descends between the caudate head and the lentiform nucleus. Ant., anterior; Calc., calcar, calcarine; Call., callosum; Cap., capsule; Caud., caudate; Cent., central; Chor., choroid; Cing., cingulate; Coll., colliculi; Corp., corpus; Ext., external; Fas., fasciculus; Fiss., fissure; Front., frontal; Gen., geniculate; Glob., globus; Hippo., hippocampal; Inf., inferior; Int., internal; Lat., lateral; Lent., lentiform; Long., longitudinal; Nucl., nucleus; Operc., opercularis; Pall., pallidus; Paracent., paracentral; Par. Occip., parieto-occipital; Ped., peduncle; Plex., plexus; Postcent., postcentral; Post., posterior; Precent., precentral; Rad., radiata, radiations; Sub. Par., subparietal; Sup., superior; Supramarg., supramarginal; Temp., temporal; Tr., tract; Triang., triangularis; Uncin., uncinata.

trochlear part of the internal capsule, but most pass through the sublenticular part.

The optic radiations are separated from the roof and lateral wall of the temporal horn and the lateral atrial wall by only a thin layer of tapetal fibers. The fibers passing to the superior bank of the calcarine fissure leave the upper part of the lateral geniculate body and course almost directly posterior around the lateral aspect of the atrium to reach the striate visual

cortex. Fibers from the lower part of the geniculate body destined for the inferior bank of the calcarine fissure initially loop forward and downward in the temporal lobe, forming Meyer's loop, before turning back to join the other fibers in the optic radiations.

The fibers of the optic radiation are divided into anterior, middle, and posterior groups (Fig. 1.16H). The anterior fibers, called Meyer's loop, subserve the upper half of the visual field.

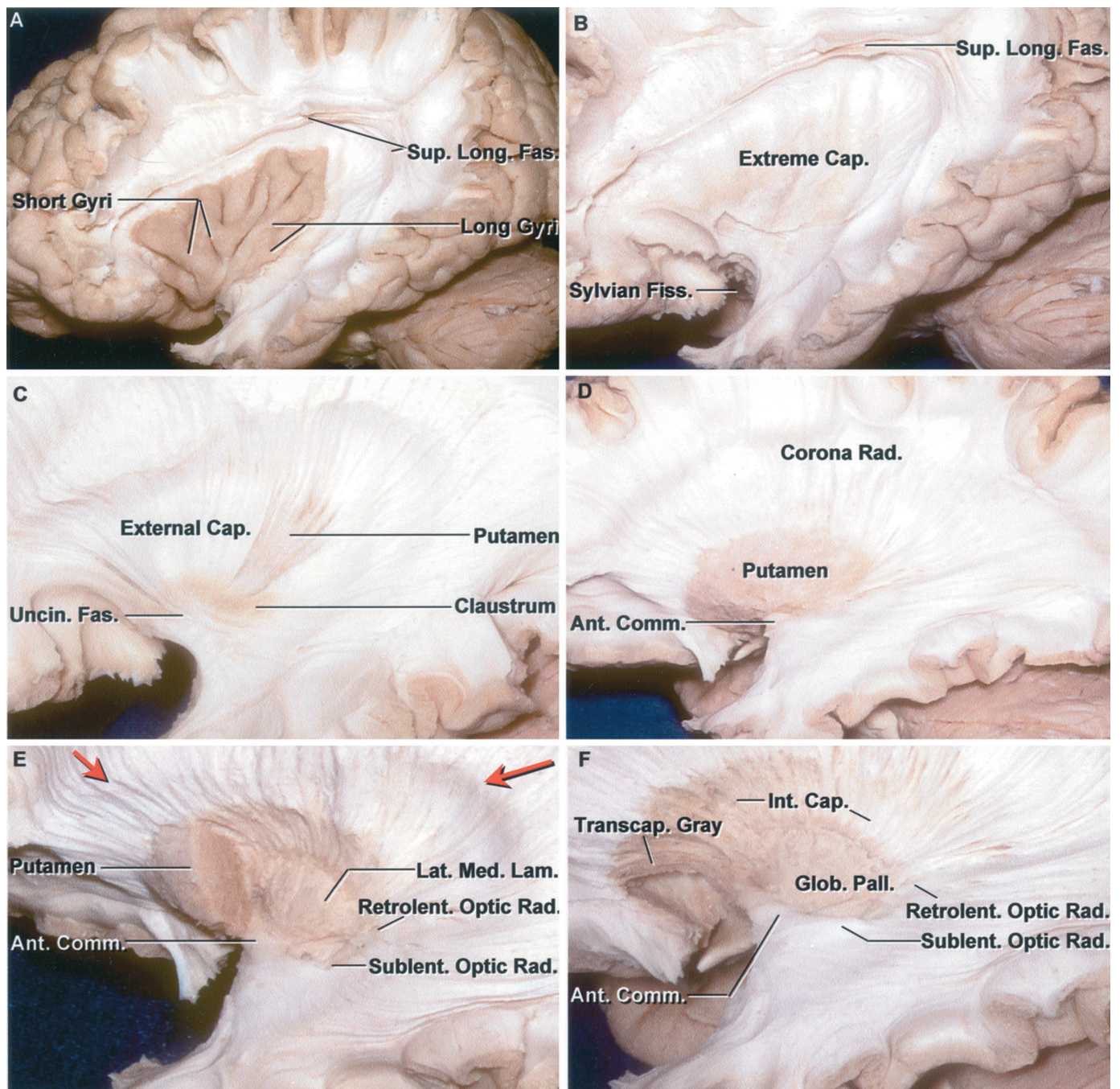


FIGURE 1.16. Stepwise fiber dissection of the left cerebral hemisphere. A, the opercular lips of the Sylvian fissure have been removed to expose the insula. The superior longitudinal fasciculus courses in the deep white matter around the outer edges of the insula and lentiform nucleus. B, the insular gray matter has been removed to expose the extreme capsule that separates the insular cortex from the claustrum. The superior longitudinal fasciculus arches around the outer margin of the insula and lentiform nucleus to interconnect the frontal, parietal, occipital, and temporal lobes. C, the extreme capsule has been removed. A small patch of the lower part of the claustrum remains. The external capsule, which separates the claustrum and lentiform nucleus, is exposed deep to the claustrum. Some of the fibers of the external capsule have been removed to expose the lateral surface of the putamen. The superior longitudinal fasciculus has also been removed. The uncinuate fasciculus is located deep to the limen insula and interconnects the frontal and temporal lobes. D, the external capsule has been removed to expose the putamen. The anterior commissure, interconnecting the temporal and septal areas, is exposed below the putamen. The corona radiata spreads out around the putamen. E, the posterior part of the putamen has been removed to expose the lateral medullary lamina that separates the putamen and globus pallidus. The white matter prominence (red arrows) around the putamen is created by the intersection of the fibers of the corpus callosum and the corona radiata. The optic radiations pass through the retrolenticular and sublenticular parts of the internal capsule to reach the visual cortex. Fibers of the anterior commissure spread laterally into the temporal lobe. (Legend continues on next page.)

They initially take an anterior direction above the roof of the temporal horn, usually reaching as far anteriorly as the tip of the temporal horn, where they loop along the lateral and inferior aspects of the atrium and occipital horn to reach the lower lip of the calcarine fissure. The middle fibers, subserving the macula, course laterally above the roof of the temporal horn and turn posteriorly along the lateral wall of the atrium and the occipital horn. The posterior fibers responsible for the lower visual field course directly backward along the lateral wall of the atrium and the occipital horn to end in the upper lip of the calcarine fissure.

Commissural Fibers

The commissural fibers interconnect the paired cerebral hemispheres. The largest is the corpus callosum. The anterior commissure is a smaller bundle.

Corpus Callosum

The corpus callosum is located between the hemispheres in the floor of the longitudinal fissure and the roof of the lateral ventricles (Figs. 1.7, 1.15, and 1.16). The corpus callosum, which forms the largest part of the ventricular walls, contributes to the wall of each of the five parts of the lateral ventricle. Its anterior half is situated in the midline deep to the upper part of the inferior frontal gyrus. Its posterior part, the splenium, is situated deep to the supramarginal gyrus and the lower third of the pre- and postcentral gyri. The corpus callosum has five parts: two anterior parts, the genu and rostrum; a central part, the body; and two posterior parts, the splenium and tapetum. The curved anterior part, the genu, wraps around and forms the anterior wall and adjacent part of the roof of the frontal horn. The genu blends below into the rostrum, a thin tapered portion that forms the floor of the frontal horn and is continuous downward, in front of the anterior commissure, with the lamina terminalis. The genu gives rise to a large fiber tract, the forceps minor, which forms the anterior wall of the frontal horn and interconnects the frontal lobes. The forceps minor sweeps obliquely forward and laterally, as does the anterior wall of the frontal horn. The genu

blends posteriorly into the midportion, the body, located above the body of the lateral ventricle. The splenium, the thick, rounded posterior end, is situated dorsal to the pineal body and the upper part of the medial wall of the atrium. The splenium gives rise to a large tract, the forceps major, which forms a prominence called the bulb in the upper part of the medial wall of the atrium and occipital horn as it sweeps posteriorly to interconnect the occipital lobes. Another fiber tract, the tapetum, which arises in the posterior part of the body and splenium, sweeps laterally and inferiorly to form the roof and lateral wall of the atrium and the temporal and occipital horns. The tapetum separates the fibers of the optic radiations from the temporal horn and the atrium. The cingulate gyrus surrounds and is separated from the corpus callosum by the callosal sulcus.

Anterior Commissure

The anterior commissure is a small bundle that crosses the midline in front of the columns of the fornix (Figs. 1.8 and 1.16). It forms part of the anterior wall of the third ventricle. It is shaped somewhat like the handlebars of a bicycle. It interconnects the olfactory structures and temporal gyri on both sides.

Fornix

The fornix is the main efferent pathway from the hippocampal formation. It contains both commissural and projection fibers. The fornix is a C-shaped structure that wraps around the thalamus in the wall of the lateral ventricle and has relationships with the cortical surface that are similar to those at the outer edge of the thalamus (Figs. 1.2, 1.8, 1.12, and 1.13). The fornix extends from the hippocampus to the mammillary bodies and has four parts: fimbria, crus, body, and columns. It arises in the floor of the temporal horn on the ventricular surface of the hippocampus from fibers that collect along the medial edge of the hippocampus and are directed backward. The fimbria is separated from the dentate gyrus by the fimbriodentate sulcus. The fimbria courses along the lateral edge of the lateral geniculate body and is separated from the geniculate body and optic and auditory radiations by the choroidal

FIGURE 1.16. Continued

F, all of the putamen has been removed to expose the lateral surface of the globus pallidus. The anterior commissure passes below the anterior part of the globus pallidus. Transcapsular bridges of gray matter extending between the lentiform and caudate nuclei cross the anterior part of the internal capsule to give it a dark appearance. G, the posterior, but not the anterior, part of the globus pallidus has been removed. Transcapsular bridges of gray matter cross the anterior part of the internal capsule. H, the optic tract proceeds posteriorly toward the lateral geniculate body. Three bundles of the optic radiations are seen: an anterior one that is deeper and loops forward above the temporal horn before turning backward, the middle one passes laterally above the temporal horn, and the third bundle passes backward lateral to the atrium to reach the calcarine sulcus. I, the retrolenticular part of the optic radiations has been removed to expose the tapetum, which separates the optic radiations from the ventricular wall. The lateral ependymal wall of the atrium has been opened. The anterior commissure was transected and the lateral part removed. The middle part of the optic radiation has been elevated on a dissection. J, the optic radiations have been removed to expose the tail of the caudate blending into the amygdala. The optic tract has been exposed further posteriorly. The stria terminalis courses medial to the caudate tail and contains fibers passing from the amygdala to the septal area, thalamus, and mammillary body. K, the lateral ependymal wall of the lateral ventricle has been removed and some bundles of callosal fibers above the ventricle have been preserved. The calcar avis bulges into the medial wall of the atrium and occipital horn. The window in the white matter (yellow arrow) overlying the calcar avis exposes the cortical gray matter in the deep end of the calcarine sulcus. The red pin is positioned lateral to the deep site of the foramen of Monro. The genu of the internal capsule is located directly lateral to the foramen of Monro. The anterior limb of the capsule is located anterior to the red dot and lateral to the caudate head. The posterior limb is located posterior to the foramen of Monro. The internal capsule blends into the cerebral peduncle below the level of the optic tract. L, the head of the caudate has been folded downward to expose the foramen of Monro. The columns of the fornix pass superior and anterior to the foramen of Monro. The septum pellucidum is exposed above the rostrum of the corpus callosum. The amygdala is exposed below the optic tract. M, the tail of the caudate has been elevated to expose the stria terminalis, which arises within the amygdala. The collateral eminence overlies the deep end of the collateral sulcus. The tail of the caudate nucleus blends into the amygdala. Ant., anterior; Calc., Calcar; Call.,

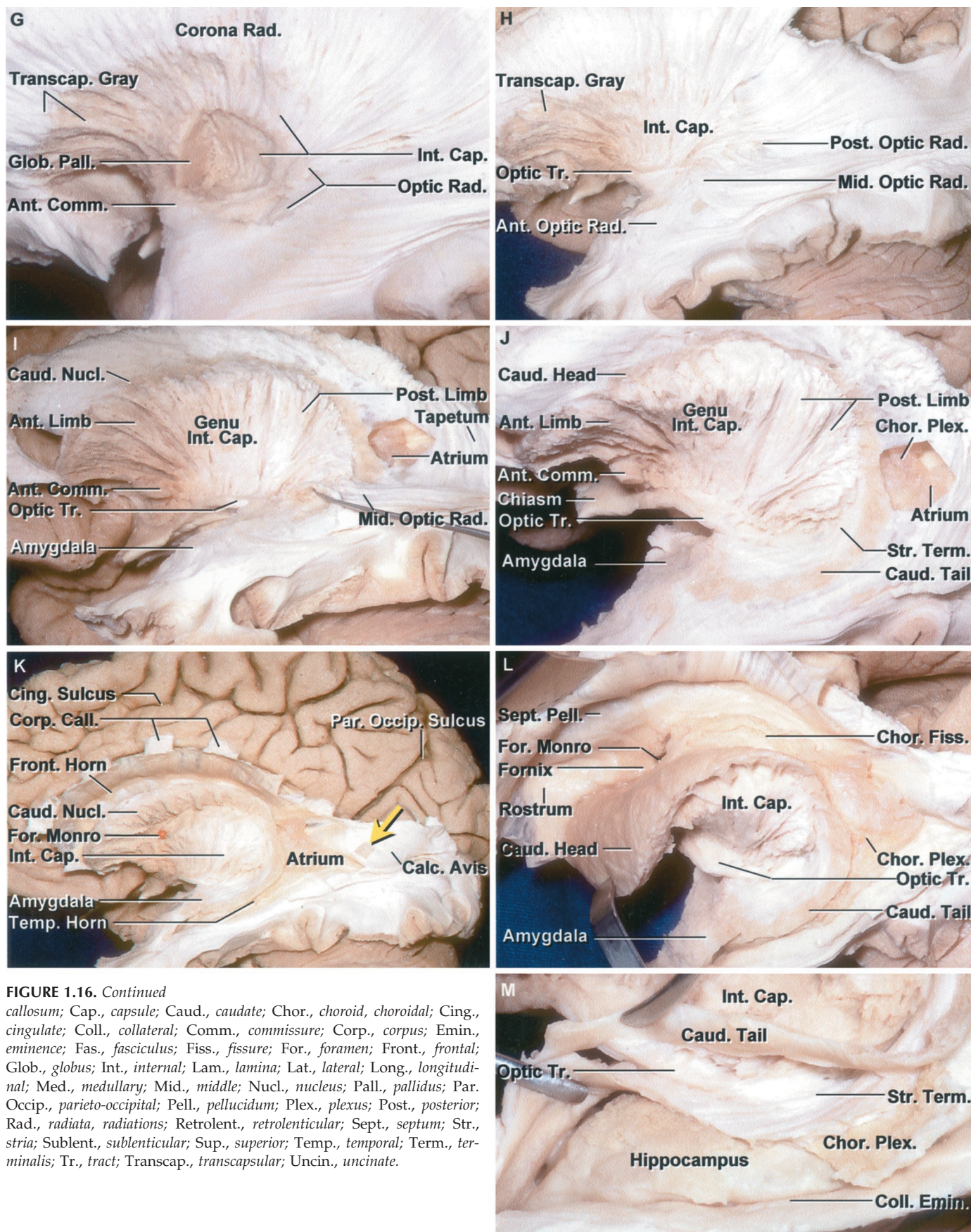


FIGURE 1.16. Continued
callosus; Cap., capsule; Caud., caudate; Chor., choroid, choroidal; Cing., cingulate; Coll., collateral; Comm., commissure; Corp., corpus; Emin., eminence; Fas., fasciculus; Fiss., fissure; For., foramen; Front., frontal; Glob., globus; Int., internal; Lam., lamina; Lat., lateral; Long., longitudinal; Med., medullary; Mid., middle; Nucl., nucleus; Pall., pallidus; Par. Occip., parieto-occipital; Pell., pellucidum; Plex., plexus; Post., posterior; Rad., radiata, radiations; Retrolent., retrolenticular; Sept., septum; Str., stria; Sublent., sublenticular; Sup., superior; Temp., temporal; Term., terminalis; Tr., tract; Transcap., transcapsular; Uncin., uncinata.

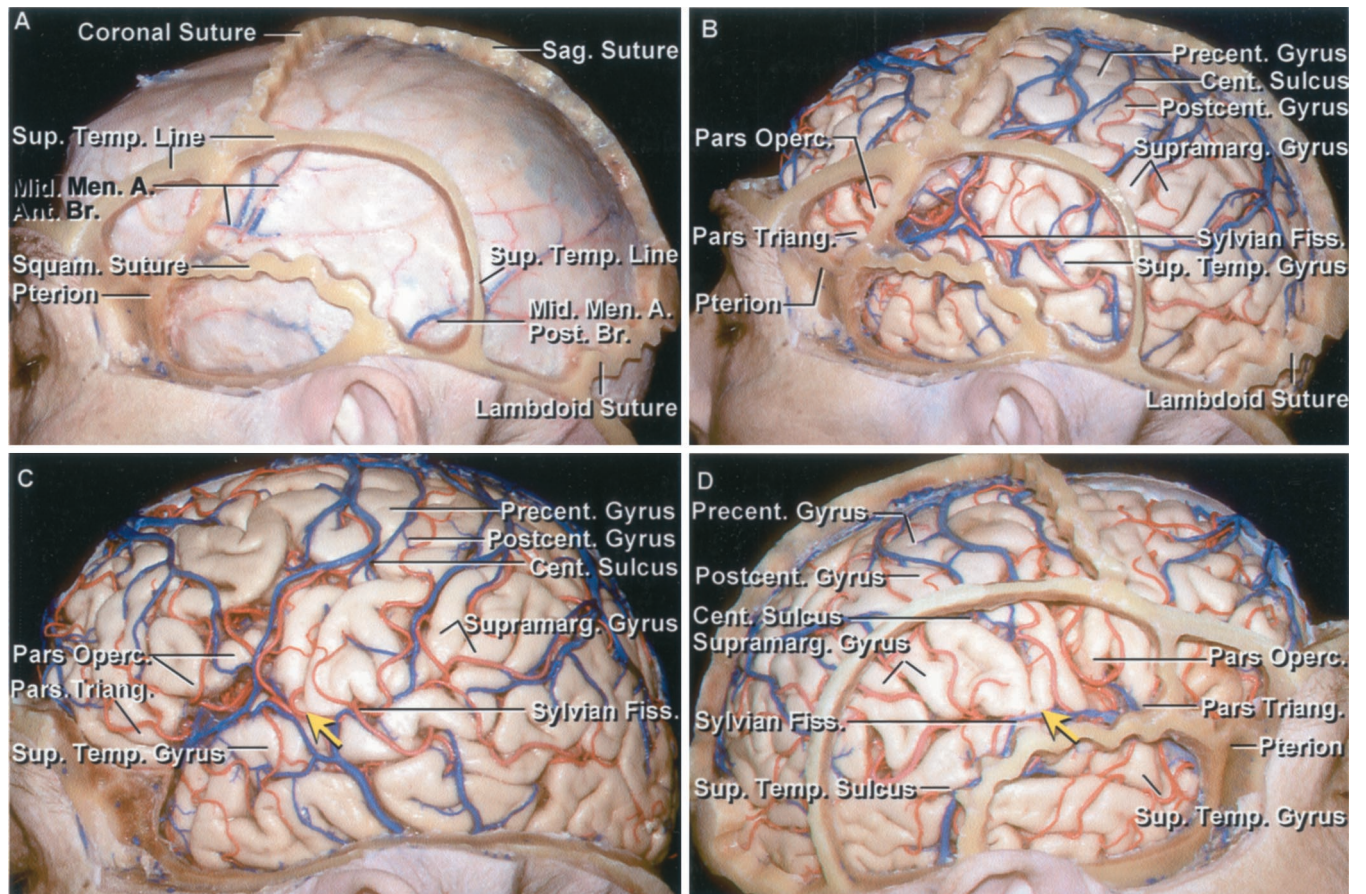


FIGURE 1.17. Relationship of the cranial sutures and the cortical surfaces. A, left hemisphere. The coronal, sagittal, lambdoid, and squamosal sutures have been preserved. The anterior and posterior meningeal branches of the middle meningeal artery course along the dura. The pterion is located at the lateral margin of the sphenoid ridge near the junction of the coronal, squamosal, and frontosphenoid sutures. B, the dura has been removed while preserving the sutures. The coronal suture crosses the posterior part of the superior, middle, and inferior frontal gyri in front of the precentral sulcus. The central sulcus has a more posterior slope than the coronal suture, thus placing the coronal suture nearer the lower end of the central sulcus than the upper end. The anterior part of the superior temporal line overlies the inferior frontal sulcus, extends posteriorly near the junction of the middle and lower thirds of the pre- and postcentral gyri, and turns downward, crossing the supramarginal and angular gyri and the posterior temporal lobe. The squamosal suture is situated just below the anterior part of the sylvian fissure and posteriorly turns downward to cross the midportion of the temporal lobe. C, the sutures have been removed to expose the gyri and sulci. The lower end of the precentral gyrus is located behind the pars opercularis and the postcentral gyrus is located in front of the supramarginal gyrus. D, right side before removal of the sutures. The relationships are similar to those on the left side, except that the anterior part of the squamosal suture courses at the level of the anterior part of the sylvian fissure, rather than being positioned below the sylvian fissure as shown in B. The coronal suture has less slope from below to above than the central sulcus, thus placing the lower end of the central sulcus nearer the coronal suture than the upper end. In D there are relatively well-developed superior, middle, and inferior temporal gyri, but in C the temporal lobe is divided into a superior temporal gyrus, but there is no clear demarcation between the region of the middle and inferior temporal gyri that are broken into multiple segments by the oblique sulci. There is a gyral bridge (yellow arrow) below the central sulcus between the lower end of the pre- and postcentral gyri on both sides so that neither central sulcus reaches the sylvian fissure. The supramarginal gyrus wraps around the upturned posterior end of the superior temporal sulcus. E, another right hemisphere. Green pinheads have been placed along the site of the coronal, squamosal, and lambdoid sutures. The pterion is located at the junction of the squamosal and coronal sutures at the lateral end of the sphenoid ridge and stem of the sylvian fissure. A yellow pin (yellow arrow) has been placed along the edge of the superior sagittal sinus at the 50% point along the nasion-to-inion line. Another red pin (red arrow) has been placed 2 cm behind the 50% point, which is usually located at the upper end of the central sulcus. The central sulcus is usually placed 3.5 to 4.5 cm behind the coronal suture. A., artery; Ant., anterior; Br., branch; Cent., central; Fiss., fissure; Men., meningeal; Mid., middle; Operc., opercularis; Post., posterior; Postcent., postcentral; Precent., precentral; Sag., sagittal; Squam., squamosal; Sup., superior; Supramarg., supramarginal; Temp., temporal; Triang., triangularis.

fissure. Posteriorly, the fimbria blends into the crus of the fornix that wraps around the posterior surface of the pulvinar in the medial part of the atrium and arches superomedial toward the lower surface of the splenium of the corpus callosum. At the junction between the atrium and the body of the lateral ventricle, the paired crura meet to form the body of the fornix, which passes above the thalamus and below the septum pellucidum in the lower part of the medial wall of the body of the lateral ventricle. At the anterior margin of the thalamus, the body of the fornix separates into two columns that arch along the superior and anterior margin of the foramen of Monro and blend into the walls of the third ventricle as they pass behind the anterior commissure and descend to reach the mamillary bodies. In the area below the splenium, a thin sheet of fiber, the hippocampal commissure, interconnects the medial edges of the crura of the fornix. The body and crus are located deep to the lower part of the pre- and post-central gyri, and the fimbria is located deep to the lower part of the superior temporal gyrus. All of its parts are located deep to the posterior part of the insula. In the body of the lateral ventricle, the body of the fornix is in the lower part of the medial wall; in the atrium, the crus of the fornix is in the medial part of the anterior wall; and in the temporal horn, the fimbria of the fornix is in the medial part of the floor.

The inner border of the fornix forms the outer border of the choroidal fissure, the cleft between the thalamus and the fornix, along which the choroid plexus in the lateral ventricle attaches (2, 7). The choroidal fissure is a C-shaped arc that extends from the foramen of Monro through the body, atrium, and temporal horn of the lateral ventricle (Figs. 1.2, 1.8, and 1.13) (2). The choroidal fissure is divided into three parts: the body part between the body of the fornix and the thalamus (9), the atrial part between the crus of the fornix and the pulvinar of the thalamus, and the temporal part between the fimbria of the fornix and the stria terminalis of the thalamus. The choroid plexus of the lateral ventricle is attached to the fornix and to the thalamus by an ependymal covering called taenia. The choroidal fissure is one of the most important landmarks in microneurosurgery involving the body and third ventricle and temporal lobe. In the body of the lateral ventricle, the fissure can be used as a route to the third ventricle. In the temporal region, it separates those structures located laterally that can be removed from those structures located medially that should be preserved during temporal lobectomy.

Septum Pellucidum

The septum pellucidum stretches across the interval between the anterior parts of the corpus callosum and the body of the fornix (Figs. 1.8, 1.14, and 1.16). It is composed of paired laminae and separates the frontal horns and bodies of the lateral ventricles in the midline. In the frontal horn, the septum pellucidum is attached to the rostrum of the corpus callosum below, the genu anteriorly, and the body above. In the body of the lateral ventricle, the septum is attached to the body of the corpus callosum above and the body of the fornix

below. The septum pellucidum disappears posteriorly where the body of the fornix meets the splenium. There may be a cavity, the cavum septum pellucidum, in the midline between the laminae of the septum pellucidum.

GRAY MATTER IN THE CENTRAL CORE

The central core of the hemisphere is the site of four large masses of gray matter located in the deep regions of the hemisphere (Figs. 1.8 and 1.12–1.16). These are the caudate nucleus putamen, globus pallidus, and thalamus. The putamen and globus pallidus combined have a lens shape in coronal cross sections and together are termed the lentiform nucleus. The thalamus is separated from the other nuclear masses by the internal capsule. The subcortical nuclear masses that include the caudate and lentiform nuclei plus the amygdala are referred to as the basal ganglia. The amygdala is located in the medial temporal lobe outside the central core. The amygdala is discussed above, with the medial surface of the temporal lobe. The superior and posterior parts of the caudate and lentiform nuclei are separated by the internal capsule, but anteroinferiorly, below the anterior limb of the internal capsule and above the anterior perforated substance, they fuse into a single nucleus mass. Further medially, below the anterior commissure and rostrum of the corpus callosum, they blend without clear demarcation into the nucleus basalis and accumbens. The tail of the caudate nucleus blends into the amygdala, and superiorly the amygdala blends into the lower surface of the globus pallidus. Two other nuclei that appear in axial sections of the basal gray matter, at the lower edge of the thalamus and medial to the cerebral peduncles, are the subthalamic and red nuclei (Fig. 1.14). This subthalamic nucleus is a biconvex lens-shaped structure located medial to the cerebral peduncle and above the substantia nigra. The substantia nigra is located below the subthalamic nucleus. The red nucleus is located in the center of the midbrain.

Caudate Nucleus

The caudate nucleus is an arched C-shaped structure that wraps around the lateral part of the thalamus (Figs. 1.8, 1.13, and 1.14). It has a large head that tapers down to a smaller body and tail. The body extends backward from the head and is separated from the thalamus by the stria terminalis and thalamostriate vein. The head and body are so large that they produce a prominence in and form the lateral wall of the frontal horn and body of the lateral ventricle. The long slender tail arches downward in the atrial wall along the lateral edge of the pulvinar to form part of the lateral wall of the atrium. The tail reaches the roof of the temporal horn where it passes forward and blends into the junction between the amygdala and lower part of the lentiform nucleus. The tail is so slender that it does not produce a prominence in the wall of the atrium and temporal horn, as does the head in the horn and body. In the body of the lateral ventricle, the caudate nucleus is superolateral to the thalamus; in the atrium, it

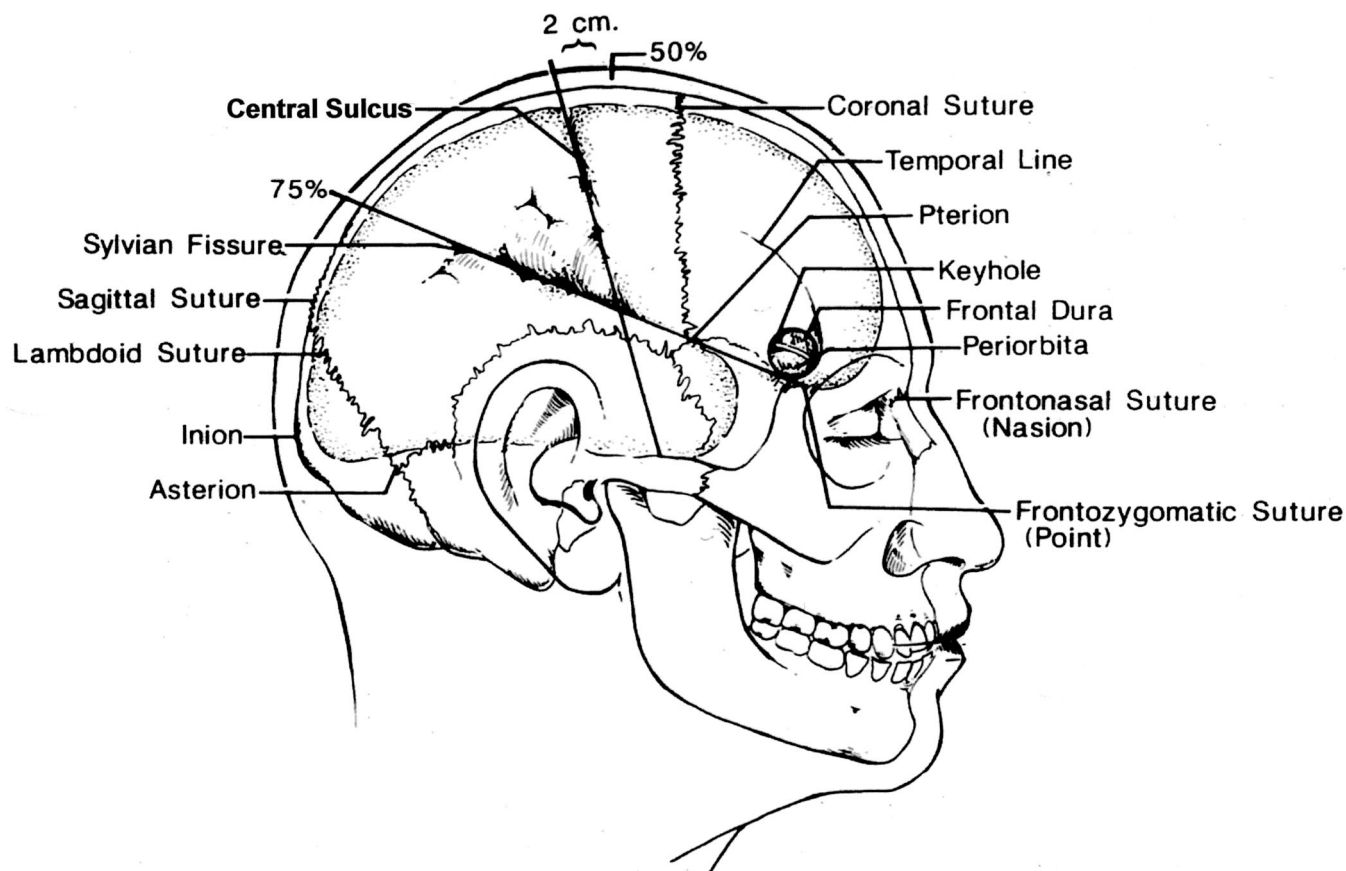


FIGURE 1.18. Sites commonly marked on the scalp before applying the drapes include the coronal, sagittal, and lambdoid sutures; the central sulcus and sylvian fissures; and the pterion, inion, asterion, and keyhole. Approximating the site of the sylvian fissure and central sulcus on the scalp begins by noting the position of the nasion, inion, and frontozygomatic point. The nasion is located in the midline at the junction of the nasal and frontal bones. The inion is the site of a bony prominence that overlies the torcular herophili. The frontozygomatic point is located on the orbital rim 2.5 cm above the level where the upper edge of the zygomatic arch joins the orbital rim and just below the junction of the lateral and superior margins of the orbital rim. The next steps are to construct a line along the sagittal suture and, using a flexible measuring tape, to determine the distance along this line from the nasion to inion and mark the midpoint and three-quarter points (50% and 75% points). The sylvian fissure is located along a line that extends backward from the frontozygomatic point across the lateral surface of the head to the three-quarter point. The pterion, the site on the temple approximating the lateral end of the sphenoid ridge, is located 3 cm behind the frontozygomatic point on the sylvian fissure line. The central sulcus is located by identifying the upper and lower rolandic points. The upper rolandic point is located 2 cm behind the midpoint (50% plus 2 cm point) on the nasion-to-inion midsagittal line. The lower rolandic point is located where a line extending from the midpoint of the upper margin of the zygomatic arch to the upper rolandic point crosses the line defining the sylvian fissure. A line connecting the upper and lower rolandic points approximates the central sulcus. The lower rolandic point is located approximately 2.5 cm behind the pterion on the sylvian fissure line. Another important point is the keyhole, the site of a burr hole, which if properly placed, has the frontal dura in the depths of its upper half and the periorbita in its lower half. It is approximately 3 cm anterior to the pterion, just above the lateral end of the superior orbital rim and under the most anterior point of attachment of the temporalis muscle and fascia to the temporal line.

is posterolateral to the thalamus; and, in the temporal horn, it is inferolateral to the thalamus.

Lentiform Nucleus

The lentiform nucleus is a wedge- or lens-shaped structure in cross section, located between the insula and the anterior and posterior limbs of the internal capsule (Figs. 1.8 and 1.13–1.16). Its lateral surface, all of which is medial to the insula, is slightly smaller than the insular surface area. Its anterior margin does not reach as far forward as the anterior part of the head of the caudate, which it faces across the anterior limb of the internal capsule. Its posterior margin does

not reach as far posteriorly as the posterior part of the thalamus, which it faces across the posterior limb of the internal capsule. Its anterior edge is grooved by the anterior commissure. Its lower-anterior part blends into the lower part of the head of the caudate nucleus in the area below the anterior limb of the internal capsule and above the anterior perforated substance. It is divided by the lateral medullary lamina, a thin layer of white matter, into the larger, more laterally positioned putamen and the smaller medially placed globus pallidus. The putamen, the largest of the basal ganglia, forms a shell-like covering to the globus pallidus. The globus pallidus is subdivided into medial and lateral parts by the medial medullary

lamina. The anterior limb of the internal capsule courses along the anterior margin of the lentiform nucleus and separates it from the caudate head. The posterior limb of the internal capsule courses along the posterior margin of the lentiform nucleus and separates the nucleus from the thalamus. The claustrum, a thin layer of gray matter interposed between the insular cortex and putamen, is separated from the putamen by a lamina of white matter, the external capsule, and from the outer gray cortex of the insula by another white matter layer, the extreme capsule.

Thalamus

The thalamus is located in the center of the lateral ventricle at the upper end of the brainstem. It is positioned deep to the posterior half of the insula and the lower part of the pre- and postcentral gyri and adjacent part of the superior temporal gyrus (Figs. 1.2, 1.8, and 1.13–1.15). The anterior thalamic tubercle, the prominence overlying the anterior thalamic nucleus, forms the posterior edge of the foramen of Monro. The thalamus reaches the level of the posterior commissure posteriorly and the hypothalamus sulcus inferiorly. Its upper margin forms the floor of the lateral ventricle. The stria terminalis and thalamostriate veins are located dorsolaterally at the junction of the thalamus and caudate. Each lateral ventricle wraps around the superior, inferior, and posterior surfaces of the thalamus. The prominent posterior part, the pulvinar or buttock of the thalamus, presents in the wall of three different supratentorial compartments: the posterolateral part of the pulvinar forms the lateral half of the anterior wall of the atrium; the posteromedial part of the pulvinar is covered by the crus of the fornix and the part medial to the fornix forms part of the anterior wall of the quadrigeminal cistern; and the inferolateral part of the pulvinar in the region of the geniculate bodies forms part of the roof of the ambient cistern. The medial part of the thalamus forms the upper part of the lateral wall of the third ventricle.

DISCUSSION

Understanding the relationship of the sutures and other superficial landmarks to the cortical surfaces is helpful in positioning and directing operative approaches (Fig. 1.17). The pterion is located at the lateral end of the greater sphenoid wing and stem of the sylvian fissure near the junction of the squamosal, coronal, sphenoparietal, and frontosphenoid sutures. The lower end of the pars triangularis of the inferior frontal gyrus is located just behind the pterion. The coronal suture, as it descends from its junction with the sagittal suture, arches over the superior and middle frontal gyri in front of the precentral sulcus. The central sulcus is nearer the lower than the upper end of the coronal suture because the central sulcus, as it ascends, is directed more posteriorly than the coronal suture. The squamosal suture follows the anterior part of the posterior limb of the sylvian fissure before turning downward, at approximately the level of the postcentral gyrus, to cross the junction of the middle and posterior third of the temporal lobe. Another surface landmark is the superior temporal line that extends from the lateral frontal region

in front of the pterion across the parietal and temporal region to the upper margin of the mastoid behind the ear. From its anterior end located lateral to the anterior margin of the pars orbitalis, it is directed obliquely upward, crossing the pars triangularis to reach the pars opercularis near the inferior frontal sulcus. Further posteriorly, it crosses superficial to the junction of the lower and middle thirds of the central sulcus, and turns downward and backward, crossing the posterosuperior margin of the supramarginal and angular gyri, finally reaching the parietomastoid suture. The lambdoid suture provides a rough estimate of the junction of the occipital lobe posteriorly with the parietal and temporal lobe anteriorly.

It may be helpful to outline several important landmarks on the scalp before applying the drapes (Fig. 1.18). Sites commonly marked include the coronal and sagittal sutures, the central sulcus and sylvian fissure, and the pterion, inion, and keyhole. Approximating the site of the sylvian fissure and central sulcus on the scalp begins with noting the position of the nasion, inion, and frontozygomatic point. The nasion is located in the midline at the junction of the nasal and frontal bones at the level of the upper rim of the orbit. The inion is the site of a bony prominence that overlies the torcular herophili and the attachment of the tentorium to the inner table of the cranium. The frontozygomatic point is the site of the frontozygomatic suture situated on the lateral orbital rim. It is positioned on the upper part of the lateral orbital rim just below where the frontal bone, which forms the upper margin of the orbital rim, joins the zygomatic bone, which forms the lateral margin of the orbital rim. The frontozygomatic point is situated on the orbital rim 2.5 cm above the level where the upper edge of the zygomatic arch joins the orbital rim.

The next step is to construct a line along the sagittal suture and, with the use of a flexible measuring tape, to determine the distance along the midsagittal line from the nasion to inion and to mark the midpoint and three-quarter point (the 50% and 75% points) along the line. The sylvian fissure is located along a line that extends backward from the frontozygomatic point across the lateral surface of the head to the three-quarter point on the nasion-to-inion midsagittal line. The pterion is located 3 cm behind the frontozygomatic point on the sylvian fissure line. The pterion approximates the lateral end of the sphenoid ridge, which extends along the stem of the sylvian fissure.

The central (rolandic) sulcus is located by identifying the upper and lower rolandic points that correspond to the upper and lower ends of the central sulcus. The upper rolandic point is located 2 cm behind the midpoint (50% plus 2 cm point) on the nasion-to-inion midsagittal line. The lower rolandic point is located where a line extending from the midpoint of the upper margin of the zygomatic arch to the upper rolandic point crosses the line defining the sylvian fissure. A line connecting the upper and lower rolandic points approximates the central sulcus. The lower rolandic point is located approximately 2.5 cm behind the pterion on the sylvian fissure line. The upper end of the central sulcus is usually located 3.5 to 4.5 cm behind the upper end of the central sulcus.

Another especially important point in approaches to the anterior part of the cerebrum is the keyhole, the site of a burr

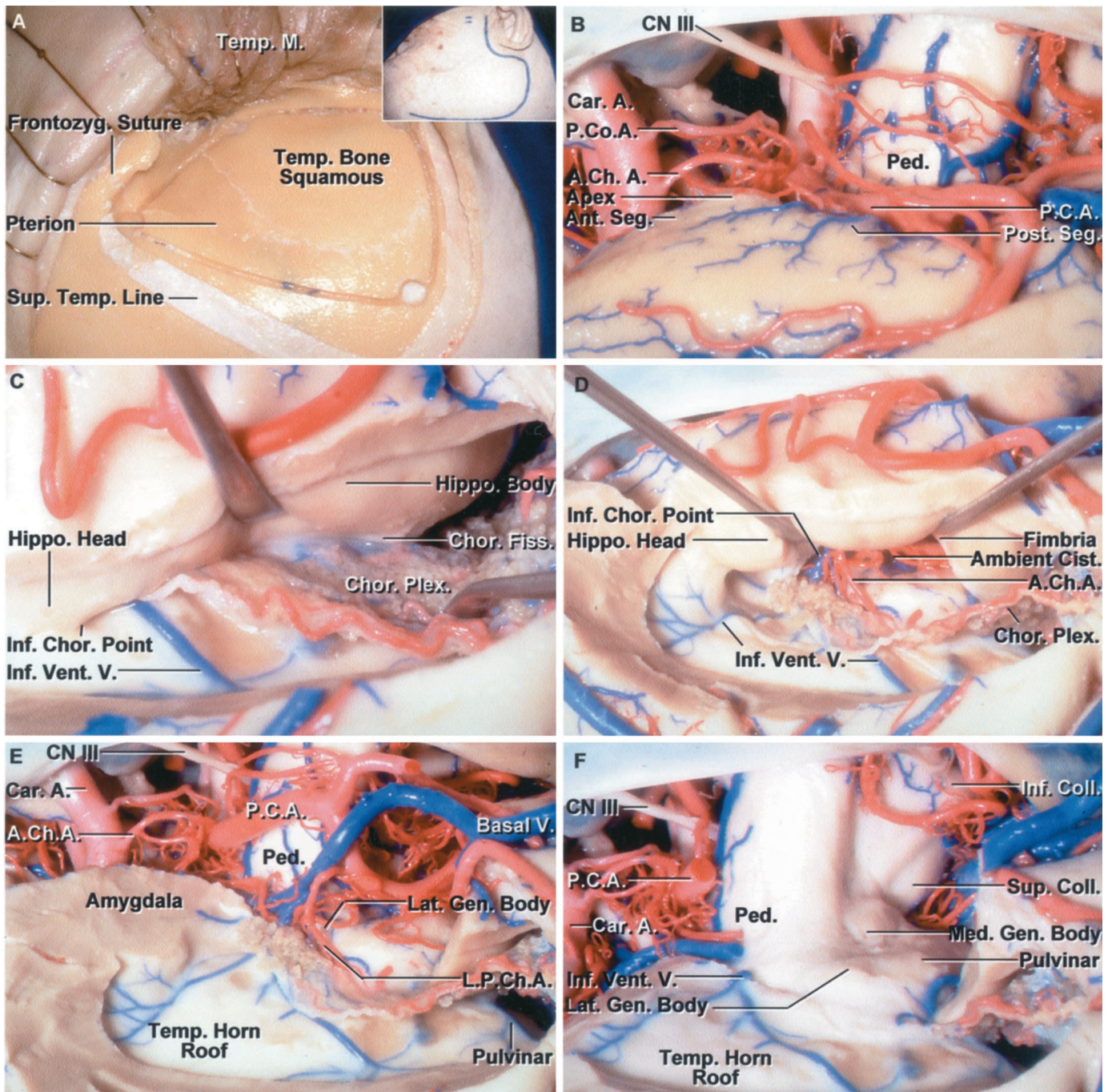


FIGURE 1.19. Transchoroidal approach to the medial disconnection of the hippocampus during temporal lobectomy. *A*, the scalp incision is shown in the inset and the left frontotemporal bone flap has been outlined. A cuff of temporalis fascia is left along the superior temporal line for closure. *B*, the temporal lobe has been elevated to expose the anterior and posterior segment of the uncus. The anterior segment contains most of the amygdala and faces the internal carotid artery. The posterior segment contains the head of the hippocampus and faces the posterior cerebral artery and cerebral peduncle. The uncus apex is located lateral to the oculomotor nerve and posterior communicating artery. *C*, the temporal horn has been opened by incising through the collateral sulcus, and the inferior temporal and occipitotemporal gyri lateral to the collateral sulcus have been removed. The medial disconnection is performed by opening the choroidal fissure between the choroid plexus and fimbria. *D*, the taenia fimbria, which attaches the choroid plexus to the fimbria, has been divided and the choroid plexus elevated with the thalamus. Opening the choroidal fissure exposes the branches of the anterior choroidal artery entering the choroid plexus and the ambient cistern. The choroid plexus remains attached to the thalamus. *E*, the hippocampus and adjacent parahippocampal gyrus have been removed. The posterior cerebral artery courses through the crural and ambient cistern on the medial side of the uncus and parahippocampal gyrus. Some of the amygdala in the upper margin of the anterior uncus segment was not removed to avoid dissection and damage along the optic tract.

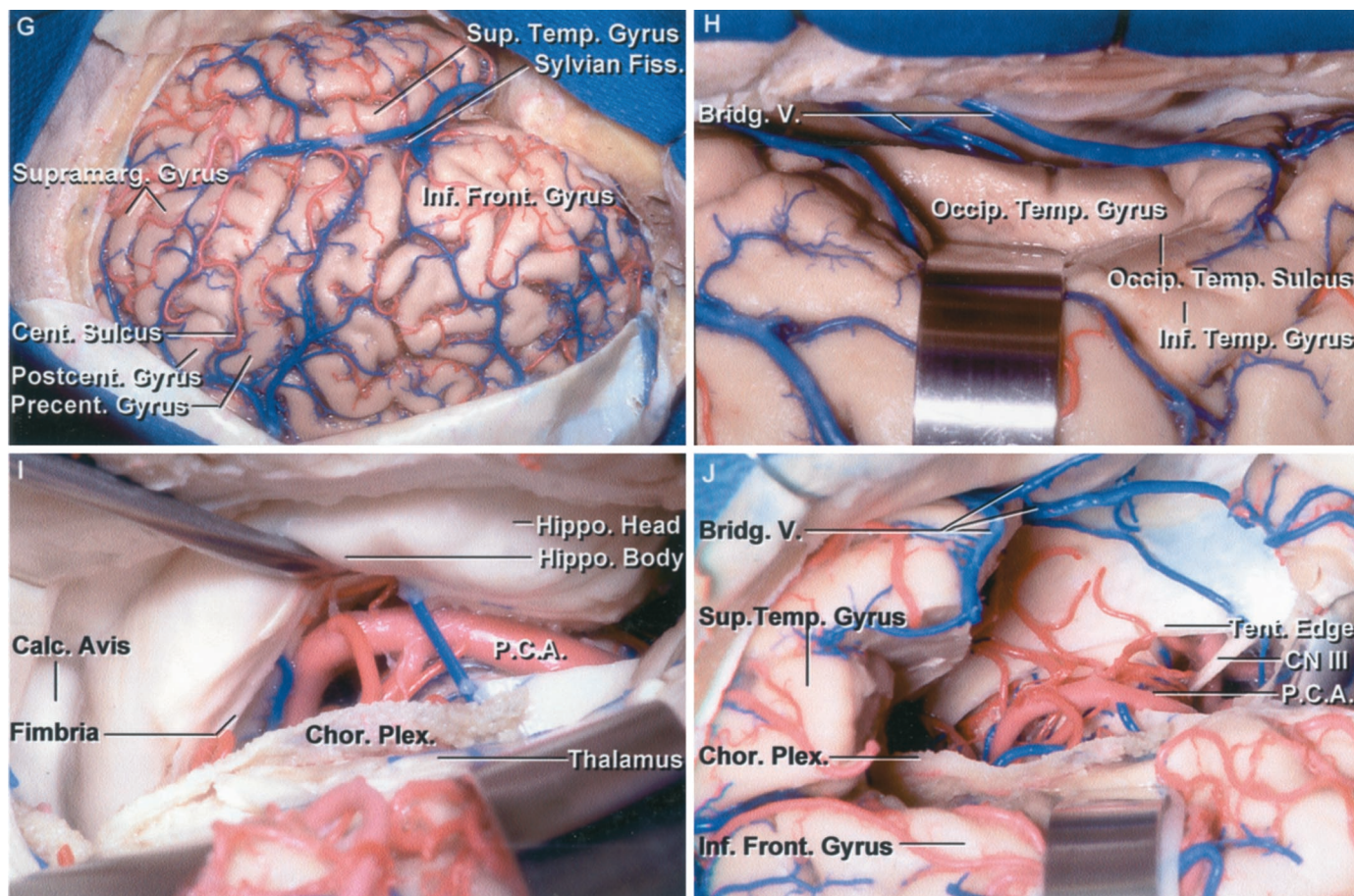


FIGURE 1.19. Continued

The lateral geniculate body is exposed medial to the choroidal fissure. The anterior and lateral posterior choroidal arteries enter the choroid plexus by passing through the choroidal fissure. F, in this dissection, the posterior cerebral artery and basal vein were removed to expose the roof of the temporal horn and the lateral geniculate body. The inferior ventricular vein drains some of the central core of the hemisphere and passes medially across the roof of the temporal horn formed by the tapetum to reach the basal vein. G, exposure for left temporal lobectomy. The exposure includes the frontal and temporal lobe, as might be used for extensive cortical recording and mapping. The exposure is greater than normally used for a standard temporal lobectomy. H, an approach that preserves more of the neocortical surface is to open through a sulcus like the occipitotemporal sulcus located between the inferior temporal and occipitotemporal gyri. I, the left temporal horn and hippocampal body and head have been exposed. The choroidal fissure has been opened by dividing the tenia fimbria that attaches the choroid plexus to the fimbria on the surface of the hippocampus. The choroid plexus remains attached to the thalamus. J, a temporal lobectomy has been completed. The third nerve, posterior cerebral artery, and tentorial edge are in the medial part of the exposure. A large bridging vein passes from the sylvian fissure below the temporal lobe to empty into a tentorial sinus. After disconnecting the hippocampus medially, the resection is extended across the head of the hippocampus behind the amygdala. A., artery; A.Ch.A., anterior choroidal artery; Ant., anterior; Car., carotid; Cist., cistern; Chor., choroid, choroidal; CN, cranial nerve; Coll., colliculus; Fiss., fissure; Frontozyg., frontozygomatic; Gen., geniculate; Hippo., hippocampal; Inf., inferior; L.P.Ch.A., lateral posterior choroidal artery; Lat., lateral; M., muscle; Med., medial; P.C.A., posterior cerebral artery; P.Co.A., posterior communicating artery; Ped., peduncle; Plex., plexus; Post., posterior; Seg., segment; Sup., superior; Temp., temporal; V., vein; Vent., ventricular.

hole, which, if properly placed, has the frontal dura in the depths of its upper half and the periorbita in its lower half. The keyhole is located immediately above the frontozygomatic point. It is approximately 3 cm anterior to the pterion, just above the lateral end of the superior orbital rim and under the most anterior point of attachment of the temporalis muscle and fascia to the temporal line. Familiarity with these points and lines aids placement of a bone flap over the appropriate lobe and intracranial compartment.

A number of superficial cortical landmarks are helpful in estimating the position of the deep structures (Figs. 1.2, 1.17,

and 1.18). The temporal horn is located deep to the middle temporal gyrus, the atrium is located deep to the supramarginal gyrus, and the frontal horn is positioned deep to the inferior frontal gyrus. The splenium and posterior part of the body of the lateral ventricle are located deep to the pre- and posterior cingulate gyri.

An understanding of the superficial relationships of a deep landmark, such as the foramen of Monro, is helpful in planning deep operative approaches. At the cranial surface, the foramen of Monro is located approximately 2 cm above the level of the pterion, just behind the lower third of the coronal

suture. At the cerebral surface, it is located deep to the central part of the pars opercularis of the inferior frontal gyrus and, at the insular level, it is located deep to the central part of the second short insular gyrus (Fig. 1.2). The pineal is located at the level of the posterior part of the middle temporal gyrus. The thalamus sits at the center of the brain with the foramen of Monro positioned at one end and the pineal at the other end. Together the surface landmarks for the foramen of Monro and pineal approximate the deep position of both the thalamus and third ventricle. The foramen of Monro defines the anterosuperior thalamic margin and the pineal defines the posterior edge. The thalamus is positioned deep to the lower part of the pre- and postcentral gyri and the adjacent part of the superior temporal sulcus (Fig. 1.2).

The most reliable landmarks for guiding an operative approach into or around the cerebrum are the frontal, occipital, and temporal poles, the sylvian fissure, the superior, lateral, and medial hemispheric borders, and the central sulcus. If the approach is directed through the cortical surface distant to these landmarks, the orientation of the approach becomes less accurate because of their marked variability in the sulci and gyri. The central sulcus is the most reliable sulcal landmark after the sylvian fissure (Figs. 1.2, 1.5, and 1.6). After opening the dura, its position adjoining the sylvian fissure between the pre- and postcentral gyri can usually be estimated by noting that it is located between the pars opercularis and precentral gyrus anteriorly and the postcentral and supramarginal gyri posteriorly. The precentral gyrus is located behind the pars opercularis, and the postcentral gyrus is positioned in front of the anterior bank of the supramarginal gyrus.

The poles and adjacent part of the frontal and temporal lobes are considered relatively safe areas for approaching deeper lesions, but opening the occipital pole carries significant risks to the visual pathways. If approaches to the midportions of the cerebrum are to be directed through the cortical surface and a lesion has not dissected a pathological pathway to the cortical surface, it is best to direct the approach through the middle and superior frontal gyri, superior parietal lobule, intraparietal sulcus, or the lower part of the lateral or basal surface of the temporal lobe. The deep end of the cerebral sulci are commonly directed toward the ventricular surface. Sulci suitable for approaching deep lesions, such as those in the lateral ventricles, include the superior frontal, inferior temporal, occipitotemporal, collateral, or the intraparietal sulci. The approaches to the lateral and third ventricle are reviewed in detail in Chapter 5.

Electrophysiological cortical mapping and studies of the sulci and gyri on magnetic resonance imaging also play a major role in directing an operative approach to the appropriate area. These more recent contributions, when combined with image guidance, have made intracerebral surgery much safer when applied with an accurate understanding of microsurgical anatomy.

The supratentorial area, fortunately, provides a number of natural pathways through which deep lesions can be approached. The sylvian fissure is a frequently used pathway for reaching all structures within and bordering the basal cisterns anterior to the quadrigeminal cistern. The neural and vascular

structures within reach of transsylvian approaches include the insula, basal ganglia, uncus, orbit, anterior cranial fossa; the olfactory, optic, and oculomotor nerves; the chiasmatic, interpeduncular, carotid, lamina terminalis, and crural cisterns; the middle cerebral and proximal part of the anterior cerebral arteries; the internal carotid artery and its branches; the circle of Willis; and the upper part of the basilar artery. The major obstacles in working through the sylvian fissure are the trunks and perforating branches of the arteries that course through the cisterns. These are reviewed in Chapter 2.

The interhemispheric fissure provides another natural cleft for accessing deep areas of the brain. Approaches directed along the anterior part of the fissure access the subcallosal area in front of the lamina terminalis and rostrum of the corpus callosum and can be used as a route to the anterior third ventricle, floor of the frontal horn, and regions of the anterior communicating artery. Transcallosal approaches directed through the interhemispheric fissure just in front of the coronal suture access the portion of the corpus callosum above the foramen of Monro for dealing with colloid cysts and other lesions in the frontal horn and body of the lateral ventricle and the upper part of the third ventricle. Usually the portion of the interhemispheric fissure along the paracentral lobule is avoided, unless it is directly involved in the pathology. The posterior part of the interhemispheric fissure provides an excellent route to the quadrigeminal cistern, pineal region, and galenic venous complex because there are no bridging veins between the posterior part of the superior sagittal sinus and the occipital lobe. The interhemispheric fissure can also be used to access lesions that involve the corpus callosum, cingulate sulcus, and the frontal horn, body, and atrium of the lateral ventricle.

The area between the basal surface of the cerebrum and the cranial base also provides a route for reaching selected lesions. The approaches directed below the orbital surface of the frontal lobe provide access to the region of the cribriform plate, orbital roof, optic nerves, the chiasmatic and lamina terminalis cisterns, and the medial part of the sylvian fissure. The approach directed below the anterior part of the basal surface of the temporal lobe, called the anterior subtemporal approach, can be used to access lesions along the whole lateral margin of the tentorial incisura back to the junction of the ambient and quadrigeminal cisterns. Retracting the anterior part of the basal surface of the temporal lobe carries less risk than elevating the posterior part, because the bridging veins that drain the majority of the temporal lobe course below the posterior temporal lobe.

The central core of the hemisphere, although small relative to the surface cortical area, is the site of numerous vital structures and pathways that can be reached by a number of surgical routes. These approaches include the subfrontal approach, which accesses the area below the anterior perforated substance where the lentiform and caudate blend together below the anterior limb of the internal capsule in the roof of the sphenoidal part of the sylvian cistern; the anterior interhemispheric approach, with opening the lamina terminalis and rostrum of the corpus callosum, which accesses the lateral and third ventricle at the medial surface of the central core; the

frontal and parietal transcallosal and transcortical approaches, which access the lateral ventricular surfaces of the core formed by the thalamus and caudate, and the medial thalamic surface facing the third ventricle; the transsylvian approach, which accesses the insular surface in the lateral aspect of the core and the caudate and lentiform nuclei facing the anterior perforated substance; and the subtemporal approach, which exposes the lower thalamic surface and the optic tract forming the roof of the ambient cistern in the lower part of the core.

Temporal Lobectomy and Amygdalohippocampectomy

The medial temporal lobe, one of the most complicated parts of the cerebrum, is the most common target for resections to treat convulsive disorders (Figs. 1.2, 1.8–1.10, 1.12, 1.13, and 1.19) (10). Several important concepts aid in conceptualizing structures in the area. One is an understanding of the relationships of the anterior and posterior segments of the uncus to the amygdala and hippocampus and to the temporal horn. The amygdala forms the majority of the anterior segment of the uncus and the anterior wall and adjacent part of the roof of the temporal horn. The amygdala presents at the medial surface of the anterior segment just lateral to the internal carotid artery. The anterior segment and amygdala are crossed above by the middle cerebral artery. The anterior choroidal artery arises from the internal carotid artery medial to the anterior segment and ascends as it passes posteriorly along the medial surface of the anterior segment. The medially directed apex of the uncus is located lateral to the third nerve and posterior communicating artery. The posterior segment faces posteromedially toward the cerebral peduncle and is divided into an upper and lower part by the uncus notch, a short sulcus that extends into the posterior segment from its posterior edge (Figs. 1.9 and 1.10). The head of the hippocampus is located in the floor of the temporal horn and turns medially to form most of the upper half of the posterior uncus segment. The amygdala extends backward above the anterior part of the head of the hippocampus and roof of the temporal horn. Superiorly, the amygdala blends into the lower margin of the lentiform nucleus (Fig. 1.8, F and G). The uncus recess, a narrow medially projecting space between the hippocampal head and the ventricular surface of the amygdala, partially separates the two structures and is located lateral to the uncus apex (Figs. 1.13J and 1.14F).

During a temporal lobectomy, the temporal horn, depending on the extent of the resection, can be entered through the middle or inferior temporal sulcus or through the basal surface on the medial side of the basal part of the inferior temporal or occipitotemporal gyri (Fig. 1.19). The temporal horn will be encountered approximately 2.5 cm from the temporal pole. There are several steps in completing the lobectomy. The first step is the lateral temporal or neocortical exposure and removal. The second step is the medial disconnection of the hippocampus, which can be achieved by opening the choroidal fissure. The third step is the anterior disconnection that includes separating the head of the hippocampus from the amygdala by using the uncus recess as a landmark for carrying

the exposure through the medial aspect of the uncus. The next step is the posterior disconnection, which involves sectioning the hippocampus and parahippocampal gyrus as far posteriorly as indicated by electrophysiological and neuroradiological studies. The final step is removal of the remaining amygdala in front of the uncus recess. Usually, a small bit of amygdala is preserved superiorly where it is in close apposition to the optic tract, branches of the anterior choroidal and posterior cerebral arteries, and the lower surface of the lentiform nucleus.

Yaşargil and Wieser (11) approach the amygdala and hippocampus through the lower part of the sylvian fissure and circular sulcus, medial to the superior temporal gyrus and below the inferior trunk of the middle cerebral artery. The incision through the antero-inferior part of the circular sulcus exposes the amygdala in the anterior uncus segment (Figs. 1.12 and 1.13). The lower and lateral parts of the amygdala are removed, but the upper medial part adjacent the claustrum, optic tract, and lentiform nucleus is not removed. The anterior uncus area is removed using subpial suction, taking care to preserve the anterior choroidal and posterior communicating arteries, the oculomotor nerve, basal vein, and optic tract, which are visible through the pia arachnoid. The anterior portion of the temporal horn is then exposed and the choroidal fissure is opened in the area lateral to the cerebral peduncle while preserving the anterior choroidal artery, optic tract, and basal vein. The dissection is carried along the lateral side of the hippocampus to the rhinal and collateral sulcus, and the transverse section of the hippocampus and parahippocampal gyrus is carried out at the posterior edge of the cerebral peduncle, lateral to the level of the geniculate body and the ascension of the fimbria to form the crus of the fornix.

REFERENCES

- Gibo H, Carver CC, Rhoton AL Jr, Lenkey C, Mitchell RJ: Microsurgical anatomy of the middle cerebral artery. *J Neurosurg* 54:151–169, 1981.
- Nagata S, Rhoton AL Jr, Barry M: Microsurgical anatomy of the choroidal fissure. *Surg Neurol* 30:3–59, 1988.
- Ono M, Kubik S, Abernathy CD: *Atlas of the Cerebral Sulci*. New York, Thieme Medical Publishers, 1990, pp 218.
- Perlmutter D, Rhoton AL Jr: Microsurgical anatomy of the distal anterior cerebral artery. *J Neurosurg* 49:204–228, 1978.
- Rhoton AL Jr: The posterior cranial fossa: Microsurgical anatomy and surgical approaches. *Neurosurgery* 47[Suppl 1]:S1–S297, 2000.
- Rhoton AL Jr: Tentorial incision. *Neurosurgery* 47[Suppl 1]:S131–S153, 2000.
- Timurkaynak E, Rhoton AL Jr, Barry M: Microsurgical anatomy and operative approaches to the lateral ventricles. *Neurosurgery* 19:685–723, 1986.
- Wen HT, Rhoton AL Jr: Basic neuroanatomy, in Layon AJ, Gabrielli A, Friedman WA (eds): *A Textbook of Neurointensive Care*. Philadelphia, W.B. Saunders Co. (in press).
- Wen HT, Rhoton AL Jr, de Oliveira EP: Transchoroidal approach to the third ventricle: An anatomic study of the choroidal fissure and its clinical application. *Neurosurgery* 42:1205–1219, 1998.
- Wen HT, Rhoton AL Jr, de Oliveira EP, Cardoso AC, Tedeschi H, Baccanelli M, Marino R Jr: Microsurgical anatomy of the temporal lobe: Part 1—Mesial temporal lobe anatomy and its vascular relationships as applied for amygdalohippocampectomy. *Neurosurgery* 45:549–592, 1999.
- Yaşargil MG, Wieser HG: Selective amygdalohippocampectomy at the University Hospital, Zurich, in Engel J Jr (ed): *Surgical Treatment of the Epilepsies*. New York, Raven Press, 1987, pp 653–658.
- Zeal AA, Rhoton AL Jr: Microsurgical anatomy of the posterior cerebral artery. *J Neurosurg* 48:534–559, 1978.