

UPPER LIMB

- What is a limb?
- Sensory to upper limb
- Making it move
 - Bones and joints
 - Muscles and nerves
- Vascular supply
- Surface anatomy
- (muscle study hint)

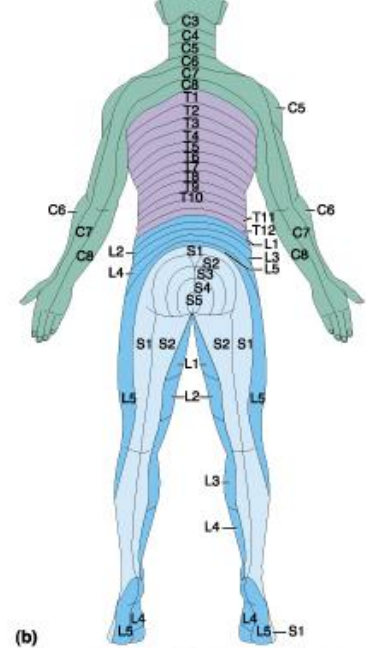
What is a limb?

- Ventral somatic outgrowth of outer tube
 - Bones (with bone, cartilage, marrow, NAV, etc.)
 - Joints
 - Muscle
 - Nerves
 - Vascular supply
- No viscera--all innervation is somatic (motor or sensory) from ventral ramus of spinal nerve (except autonomics to blood vessels)

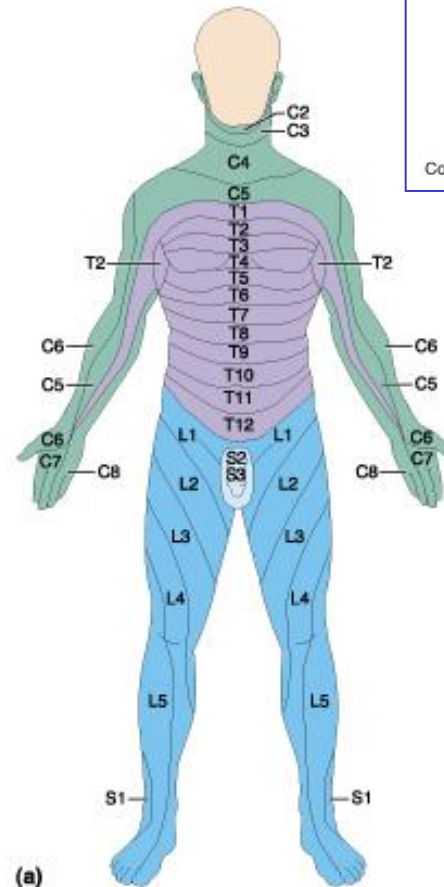


Sensory from limb (dermatomes/sensory skin segments from spine)

- Dermatomes extend over limbs
- Twisted orientation reflects twisting of limb during development
- Named nerves generally innervate skin over muscles that they innervate



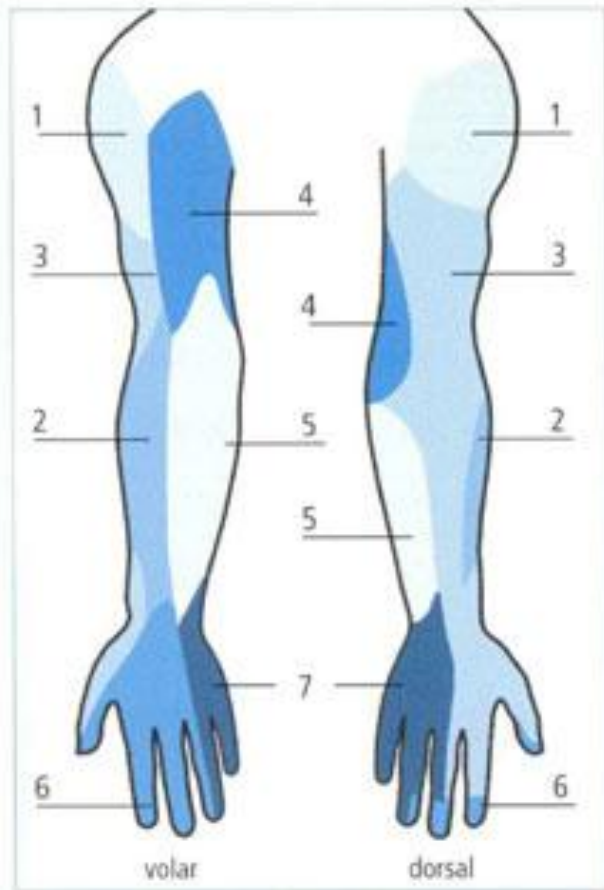
Copyright © Pearson Education, Inc., publishing as Benjamin Cummings.



(a)

Copyright © Pearson Education, Inc., publishing as Benjamin Cummings.

Sensory territory of nerves

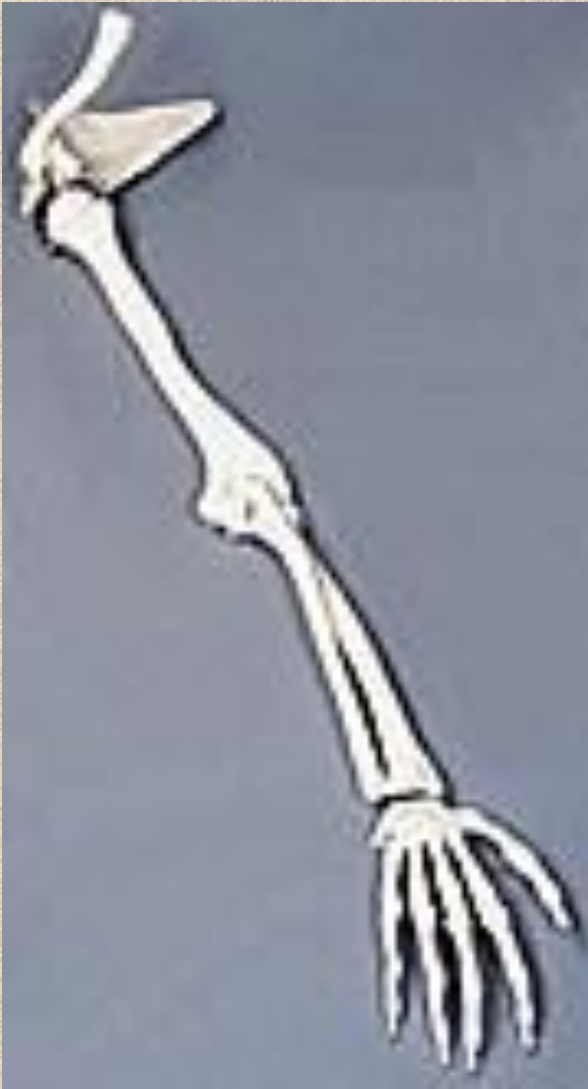

Brachial plexus serves to re-direct spinal routes into named nerves covering certain territory

- 1 Axillary nerve
 - 2 Musculocutaneous nerve
 - 3 Radial nerve
 - 4 Medial cutaneous nerve of the arm
 - 5 Medial cutaneous nerve of the forearm
 - 6 Median nerve
 - 7 Ulnar nerve
- } Cutaneous branches of medial cord/ulnar nerve

Fig. 2: Sensory supply areas of the brachial plexus

Upper Limb Skeleton (old hat?)



- Scapula
- Humerus
- Radius, ulna
- Carpals--proximal, distal
- Digits
 - Metacarpals
 - Phalanges

Joints

JOINT	BETWEEN	MOVEMENT	TYPE

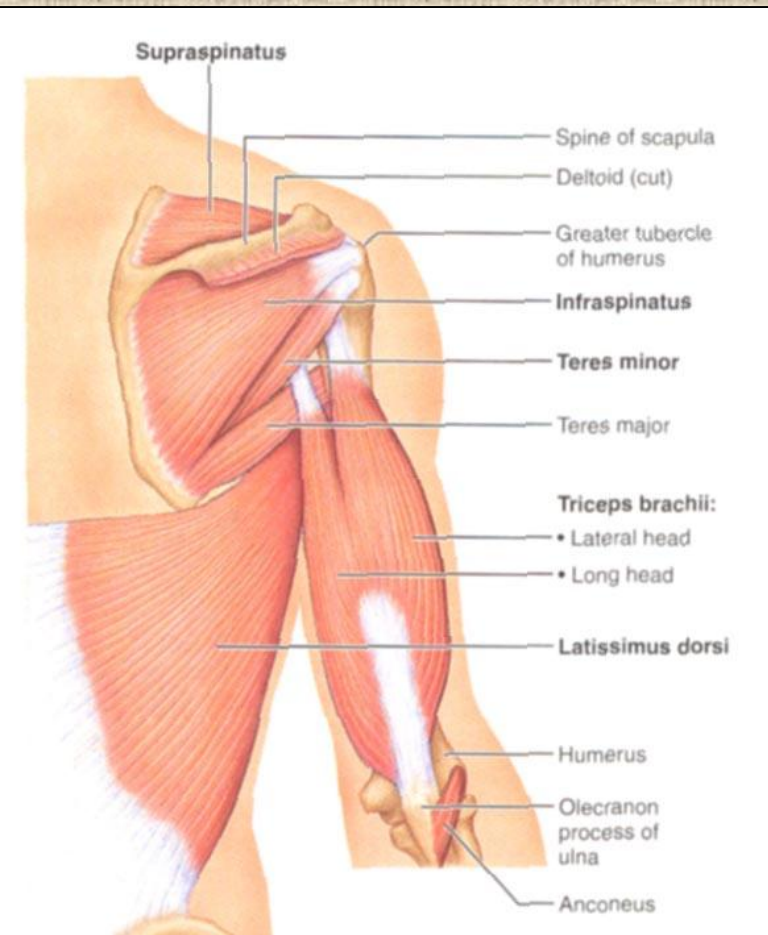
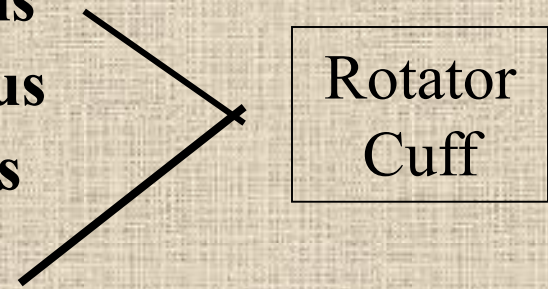
Muscles of Scapula

- If INSERTION on scapula = Move scapula

- Rhomboids
- Trapezius
- Pectoralis Minor
- Serratus Ventralis
- Levator Scapulae

If ORIGIN on scapula = Move Arm

- **Subscapularis**
- **Supraspinatus**
- **Infraspinatus**
- **Teres Minor**
- Teres Major
- Latissimus Dorsi (partial O on scap)
- Coracobrachialis

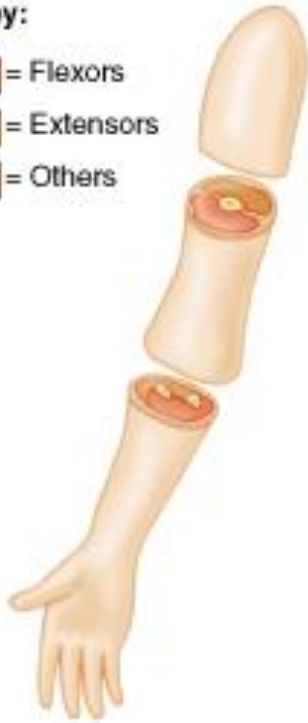

Use location of Insertion to determine exact movement!!

POSTERIOR AND ANTERIOR COMPARTMENTS

Key:

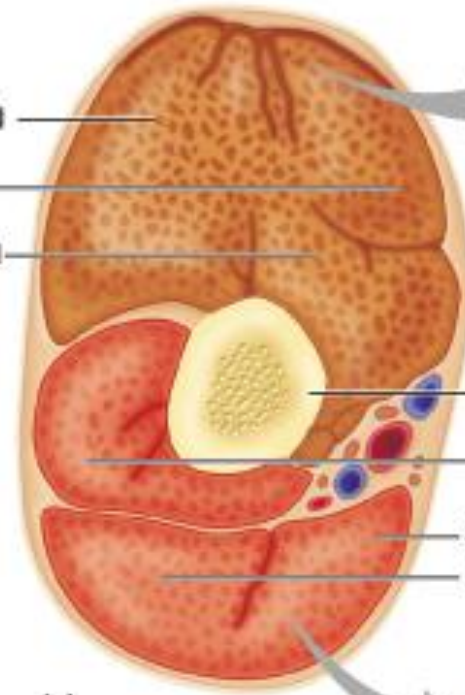
- = Flexors
- = Extensors
- = Others



(a)

Triceps
brachii

Lateral
Long
Medial



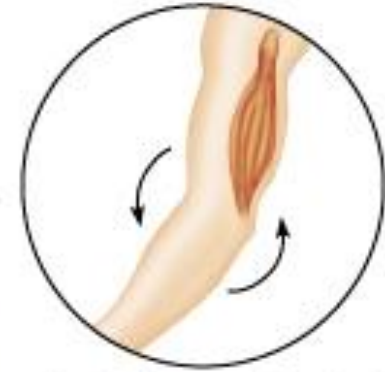Humerus

Brachialis

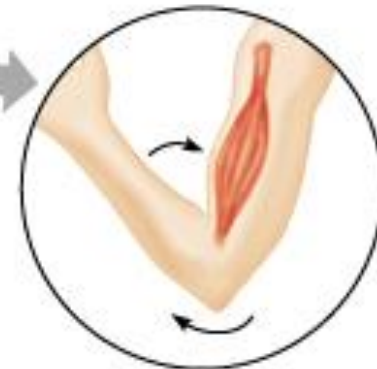Short head
Long head

Biceps brachii

(a)



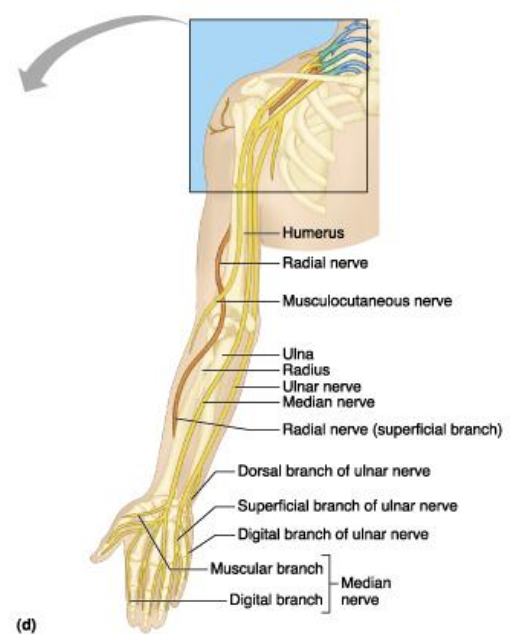
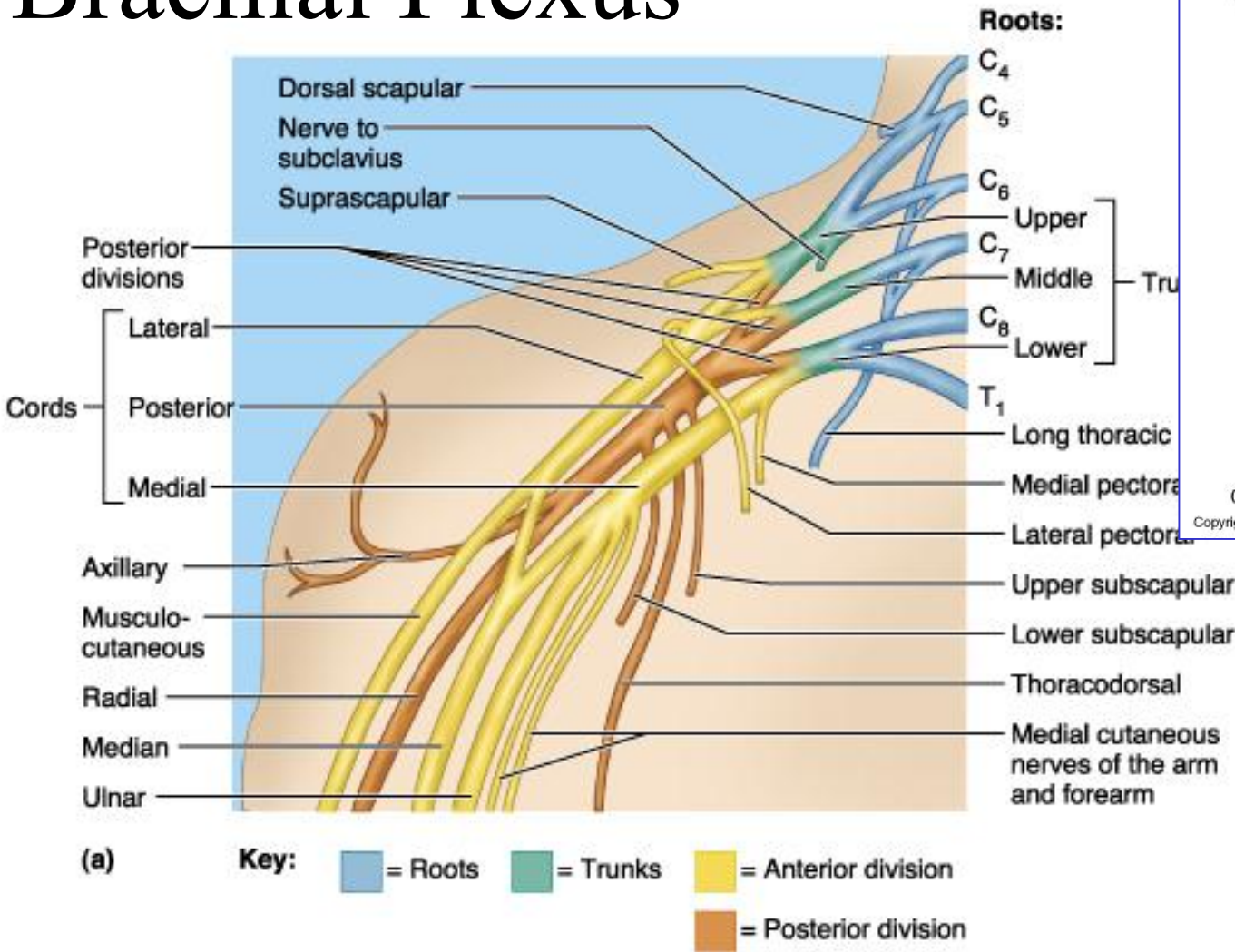
Posterior compartment of arm
(extends elbow)



Anterior compartment of arm
(flexes elbow)

Copyright © Pearson Education, Inc., publishing as Benjamin Cummings.

Brachial Plexus



(d) Copyright © Pearson Education, Inc., publishing as Benjamin Cummings.

Copyright © Pearson Education, Inc., publishing as Benjamin Cummings.

M&M, Fig. 14.11

- Posterior Compartment—posterior cord
- Anterior compartment—medial, lateral cords
- Name of cord is relative to axillary artery

ANTERIOR MUSCLES

- M-C
 - Biceps
 - brachialis
- Median
 - Forearm flexors
 - Thumb intrinsics (1M\$ nerve)
- Ulnar
 - Flexor carpi ulnaris
 - Hand intrinsics

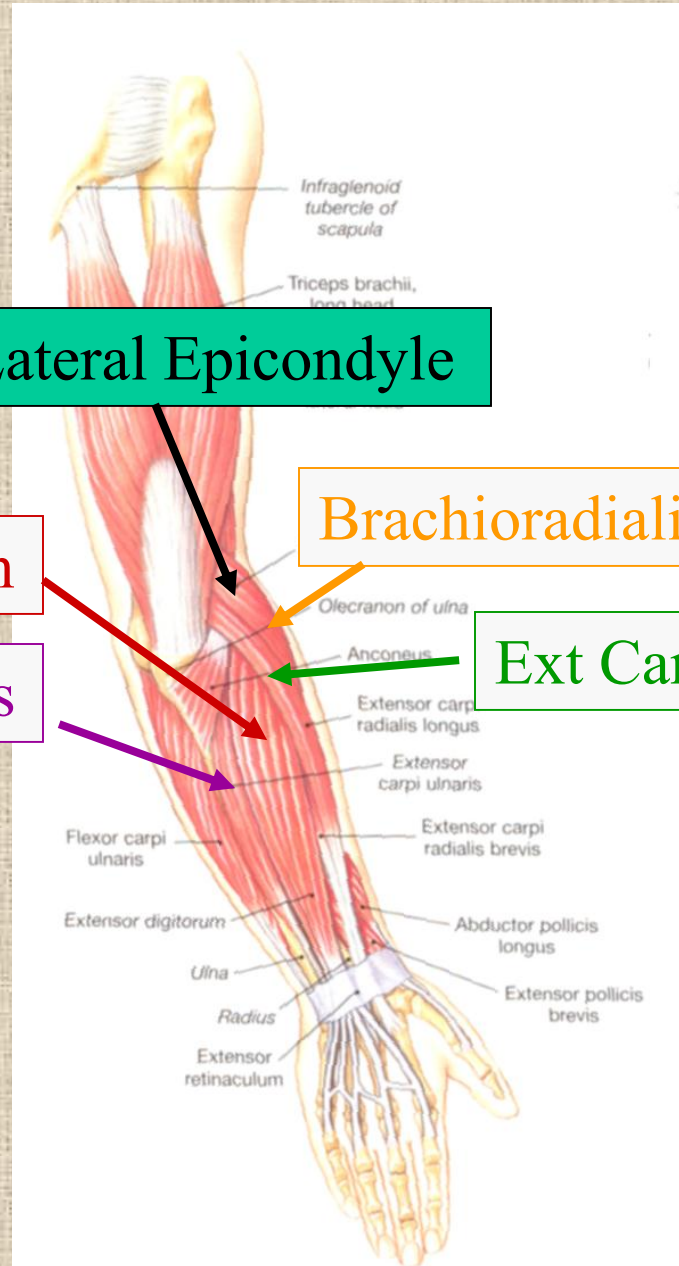
POSTERIOR MUSCLES

- Muscles (radial nerve)
 - Triceps
 - Anconeus
 - Brachioradialis
 - Carpal, digit extensors

Muscles and nerves by compartment

	ANTERIOR	POSTERIOR
NERVES	M-C, ulnar, median	Radial
MOVEMENT	Flexion	Extension
MUSCLES	Biceps, flexors	Triceps, extensors
TWIST	Flexors from medial epicondyle	Extensors from lateral epicondyle

Posterior Compartment of Forearm



Lateral Epicondyle

Extensor digitorum

Brachioradialis

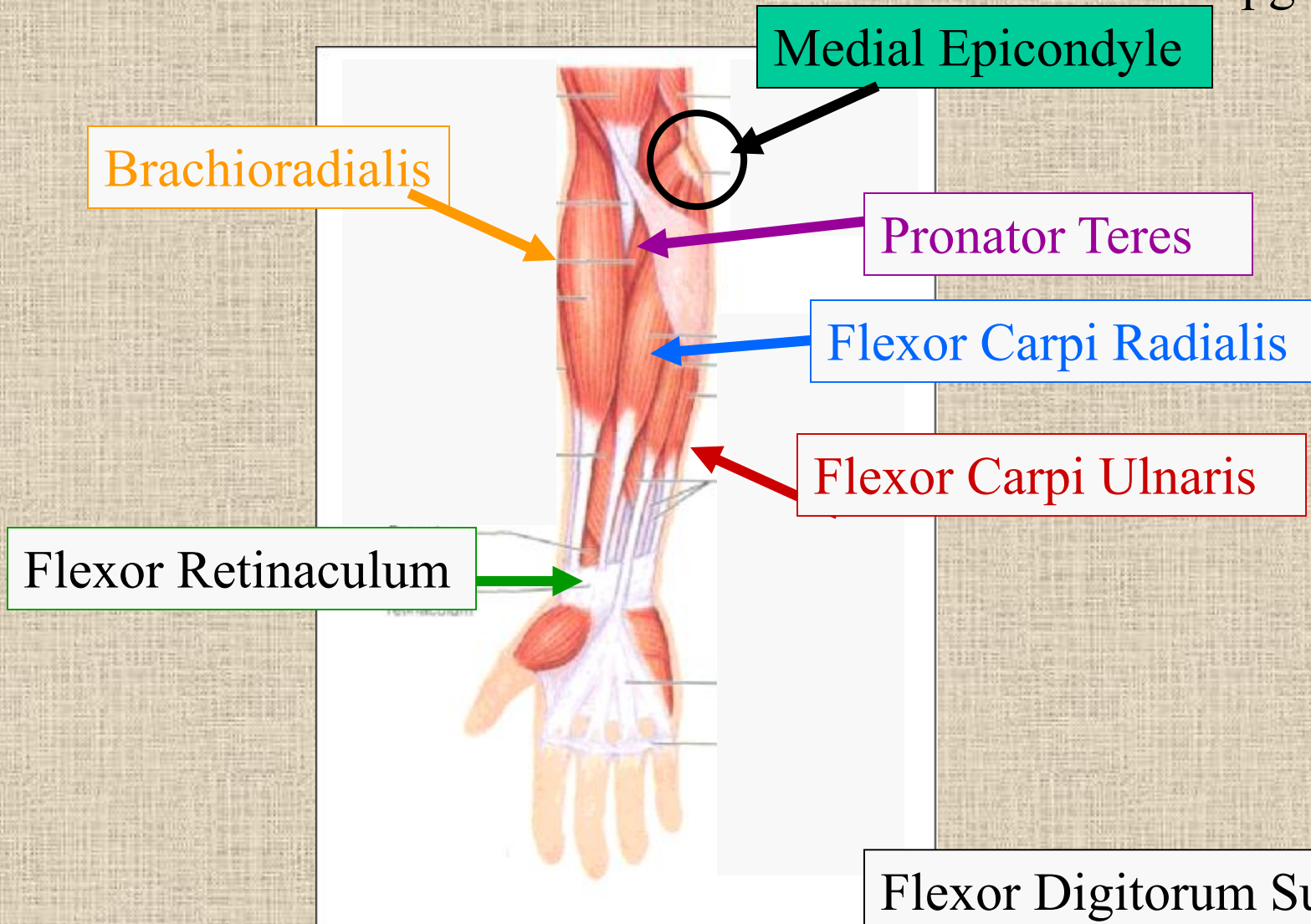
Extensor carpi ulnaris

Ext Carpi Radialis Longus

Posterior View

Anterior Compartment Forearm

pg 302



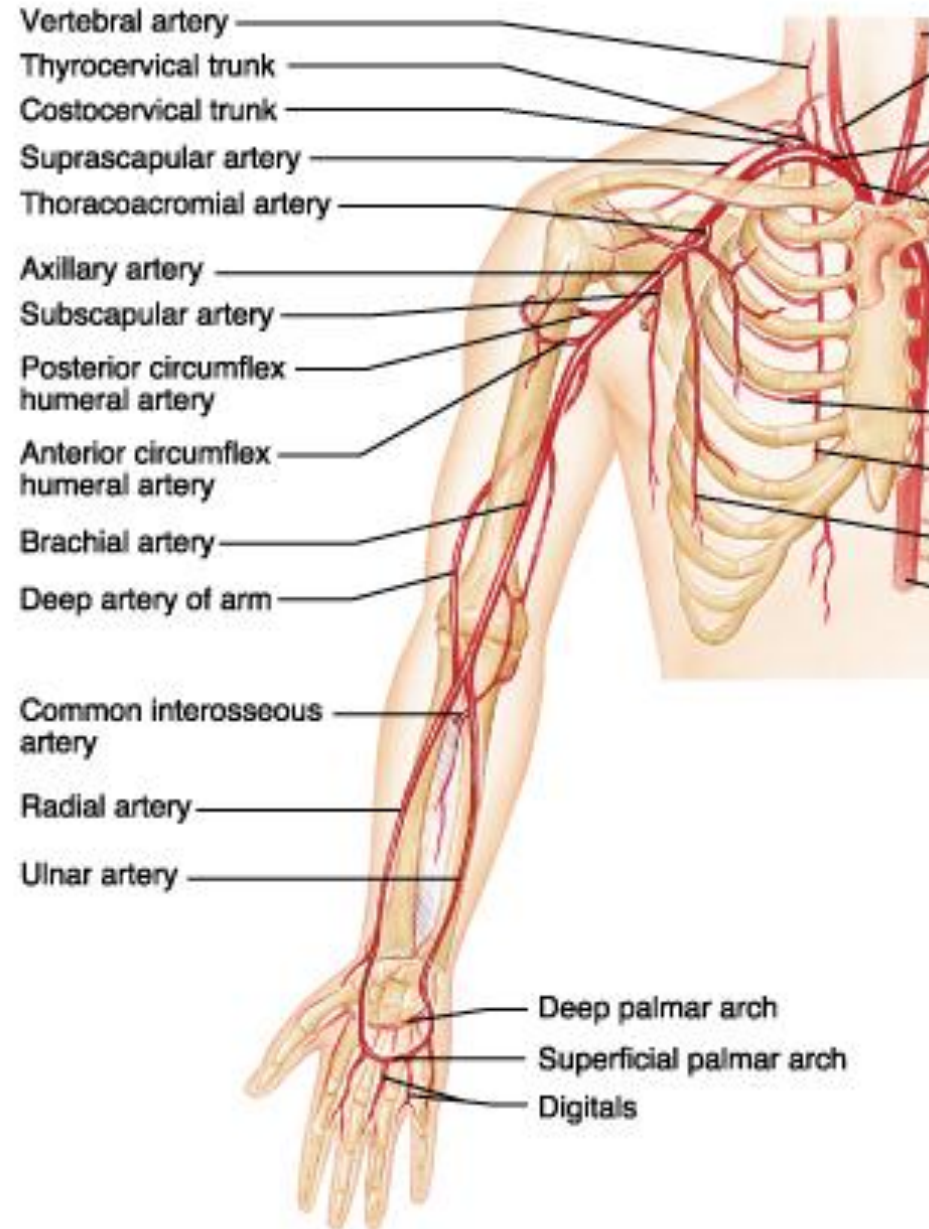
Flexor Digitorum Superficialis
is deep to other flexors

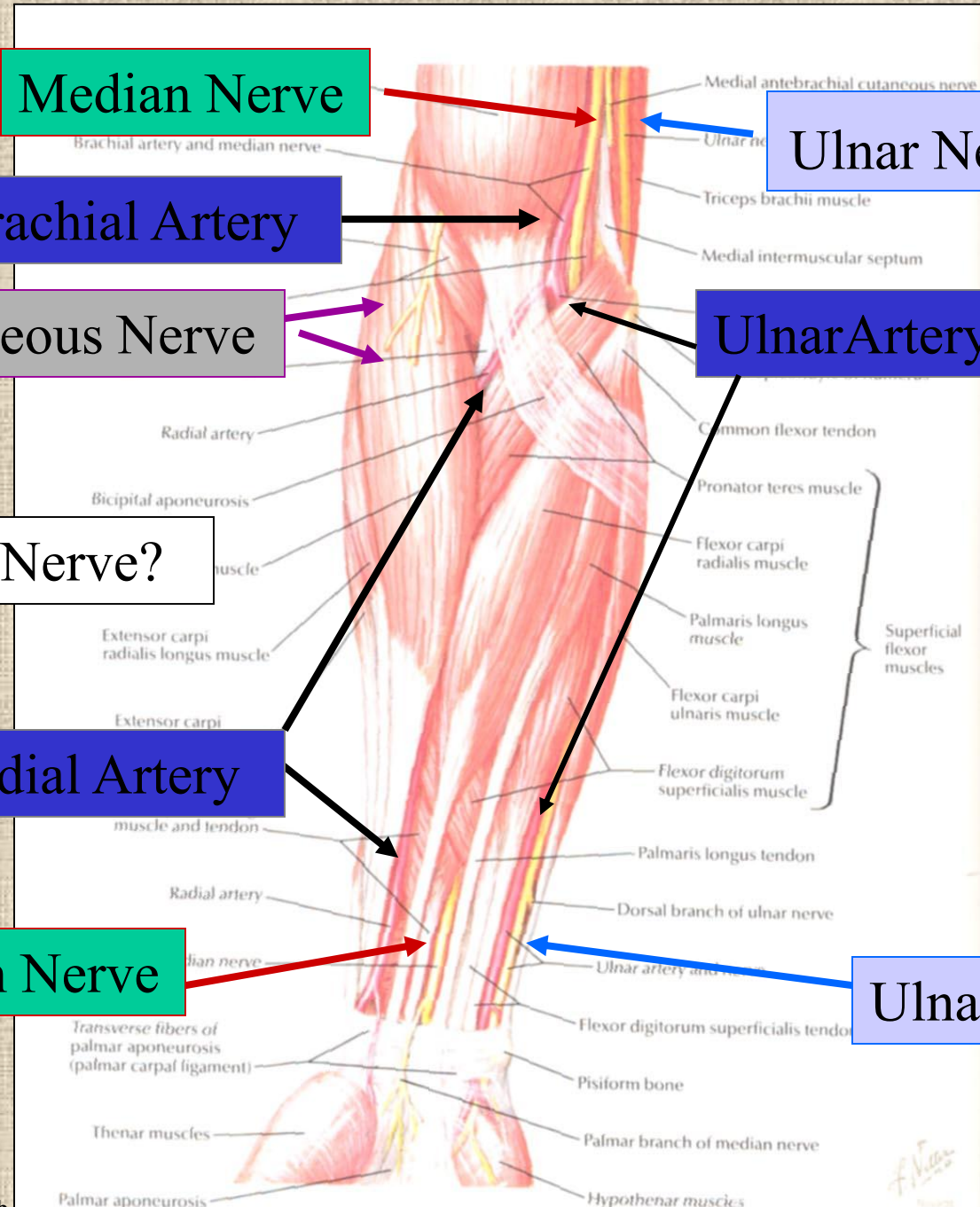
Routes of nerves (in human)

- M-C: between biceps brachii and brachialis
- Median: medial/posterior to biceps, branches into forearm flexors at elbow then to hand through carpal tunnel
 - Recurrent median (1M\$) superficial at wrist to thumb over thenar eminence) deficit - ape's hand
- Ulnar: medial in arm, posterior to medial epicondyle of humerus (funny bone) down medial forearm medial to carpal tunnel into palm
- Radial: deep posterior arm around lateral epicondyle of humerus to forearm (deep and superficial branches)

Vascular supply

- Subclavian → axillary
→ radial (same street, new street sign every block)
- Collateral circulation
 - Posterior/anterior circumflex humeral
 - Deep brachial a.
- Radial a. (with median n.)
→ deep palmar arch
- Ulnar a. (with ulnar n.) → superficial palmar arch





Median Nerve

Ulnar Nerve

Brachial Artery

Musculocutaneous Nerve

Ulnar Artery

Where's Radial Nerve?


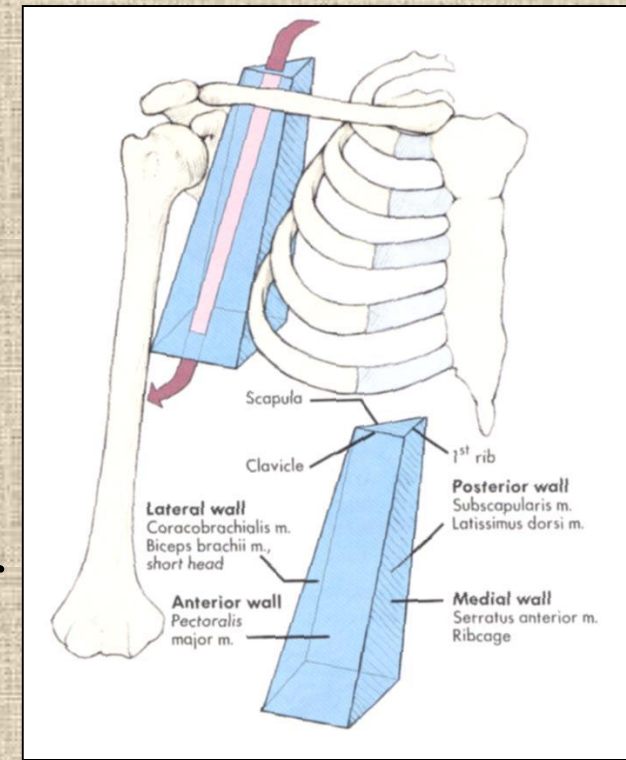
Radial Artery

Median Nerve

Ulnar Nerve

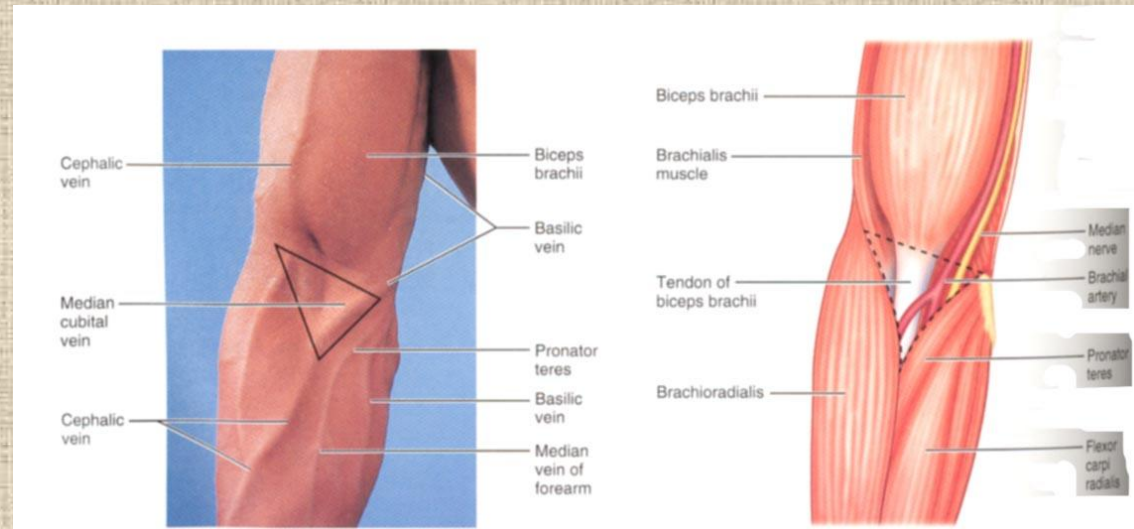
Axilla = Armpit

- Region between arm and chest
- Boundaries
 - Ventral - pectoral muscles
 - Dorsal = latissimus dorsi, teres major
subscapularis
 - Medial = serratus ventralis
 - Lateral = bicipital groove of humerus
- Contents
 - Axillary lymph nodes, Axillary vessels
Brachial Plexus

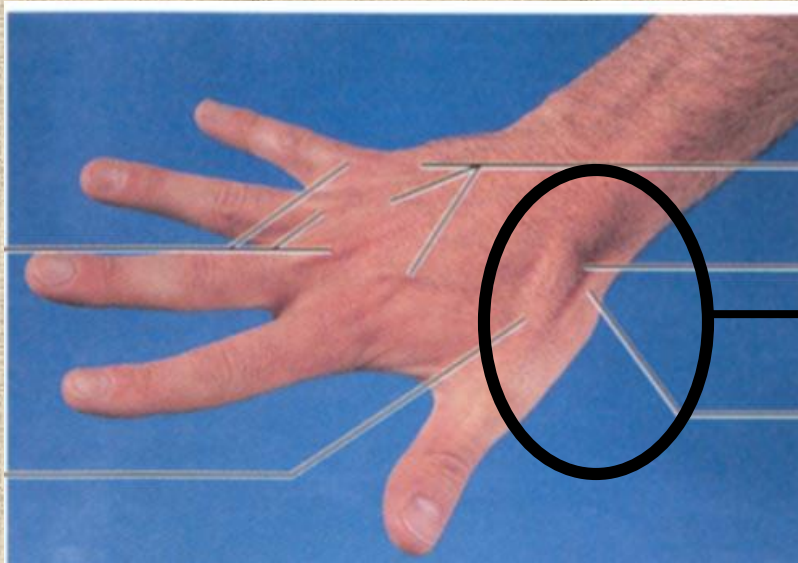


Surface Anatomy of Upper Limb

- Biceps + Triceps brachii
- Olecrenon Process
- Medial Epicondyle
- Cubital Fossa
 - Anterior surface elbow
 - Contents
 - Median Cubital Vein
 - Brachial Artery
 - Median Nerve
 - Boundaries
 - Medial= Pronator teres
 - Lateral= Brachioradialis
 - Superior= Line between epicondyles



Surface Anatomy of Upper Limb



- Carpal Tunnel
 - Carpals concave anteriorly
 - Carpal ligament covers it
 - Contains: long tendons, Median nerve
 - Inflammation of tendons = compression of Median nerve

• Anatomical Snuffbox

- Lateral = E. pollicis brevis
- Medial = E. pollicis longus
- Floor = scaphoid, styloid of radius
- Contains Radial Artery (pulse)

pg 306, 788